



اطلس انگل شناسي

گردآورنده و تهیه کننده : دکتر شهلا فارسي
مسئول آزمایشگاه انگل شناسي

منابع :

- www.dpd.cdc.gov
- Cdfound www.atlas of Medical
- عكسهاي تهيه شده توسط اينجانب با آرمي در گوشه آن مشخص گردیده است



نمادهای روده ای انسان

آسکاریس لومبریکوئیدس

کرم قلاب دار

استرونژیلوئیدس استرکورالیس

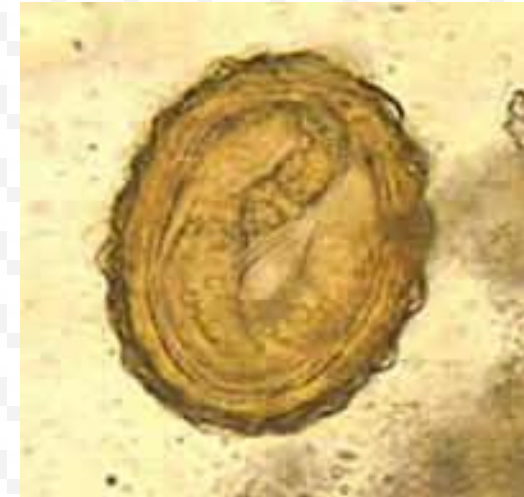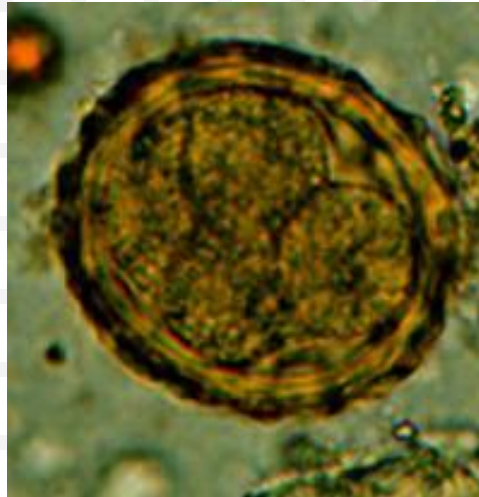
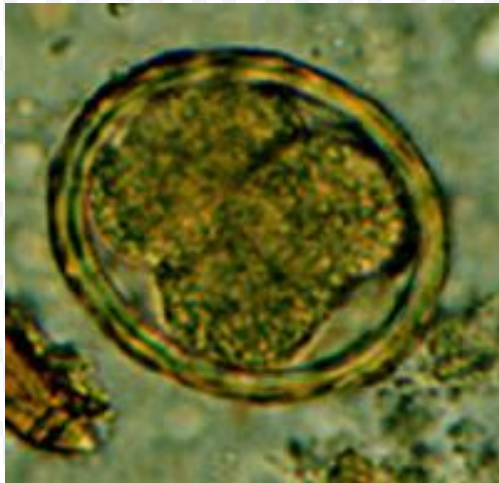
انتروبیوس ورمیکولاریس = کرمک

تریکوسفال = تریکیوریس تریکیورا = کرم شلاقی

دراکونکولوس مدینسیس

لارومهاجر احشایی (عامل : توکسوکارا)

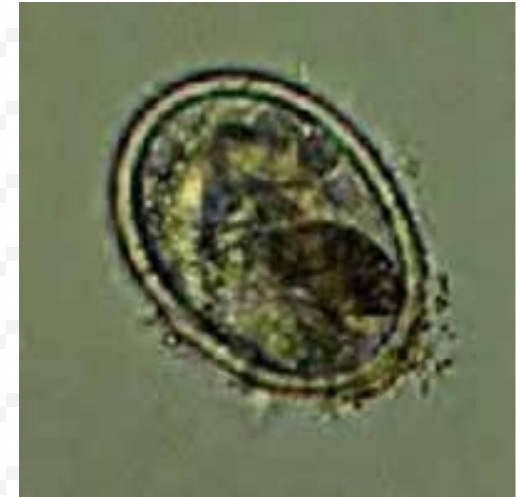
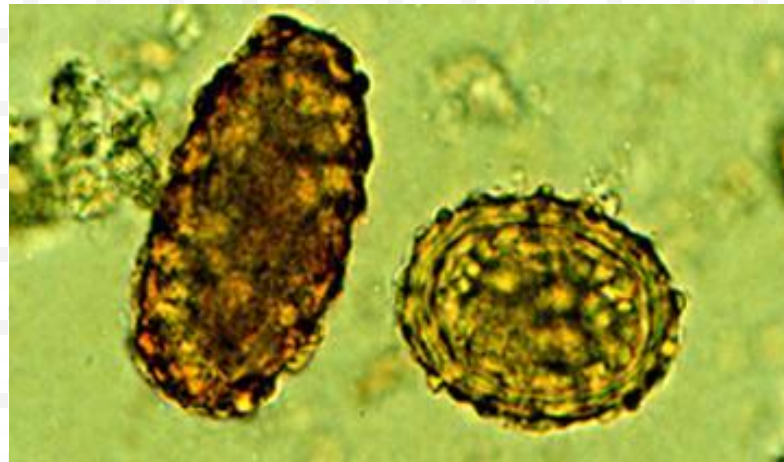
Ascaris lumbricoides



Egg containing a larva
which will be infective if
ingested)

- Two fertilized eggs

Ascaris lumbricoides



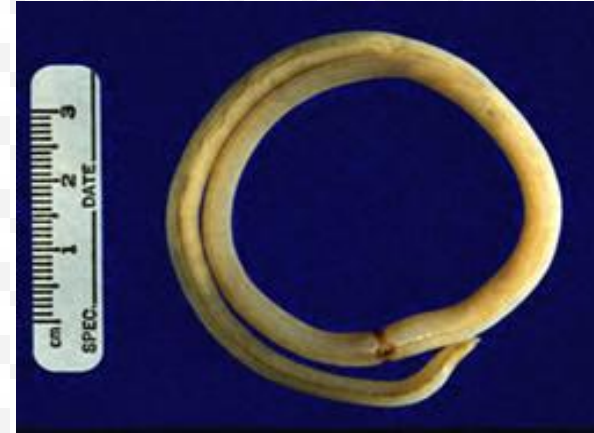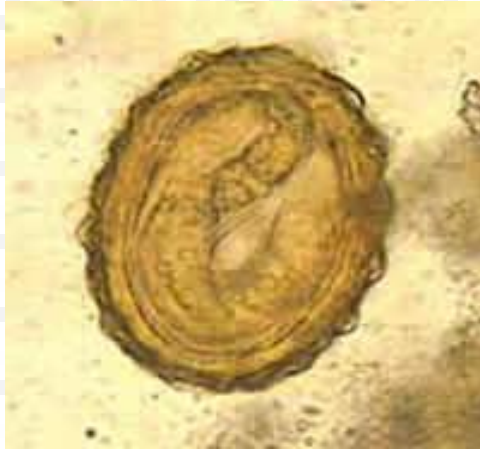A fertilized *Ascaris* egg, still at the unicellular stage

Unfertilized and fertilized eggs (left and right, respectively)

Unfertilized egg with no outer mammillated layer (decorticated egg)



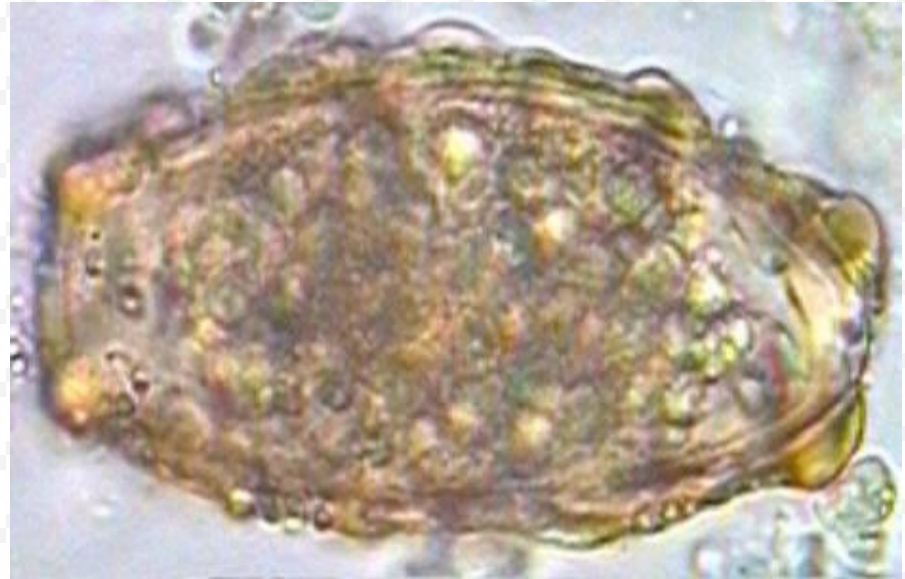
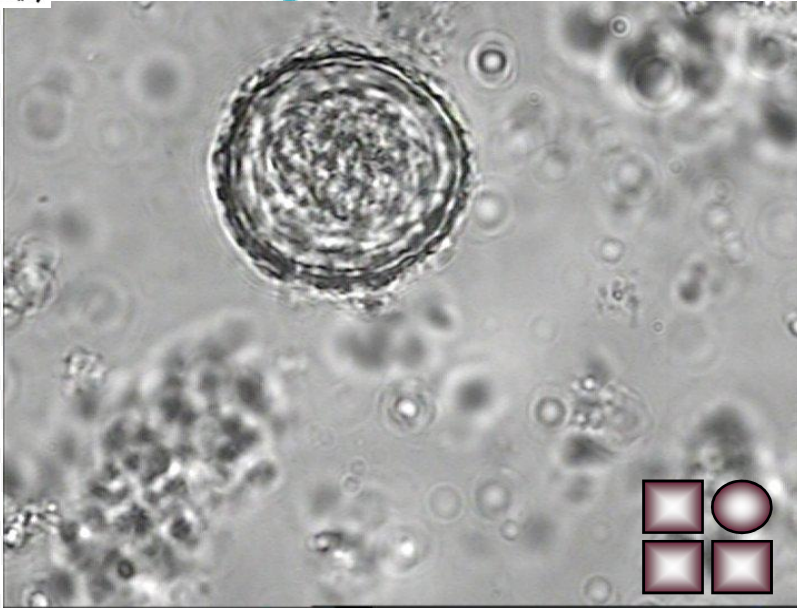
Ascaris lumbricoides




Egg containing a larva, which will be infective if ingested

Larva hatching from an egg .

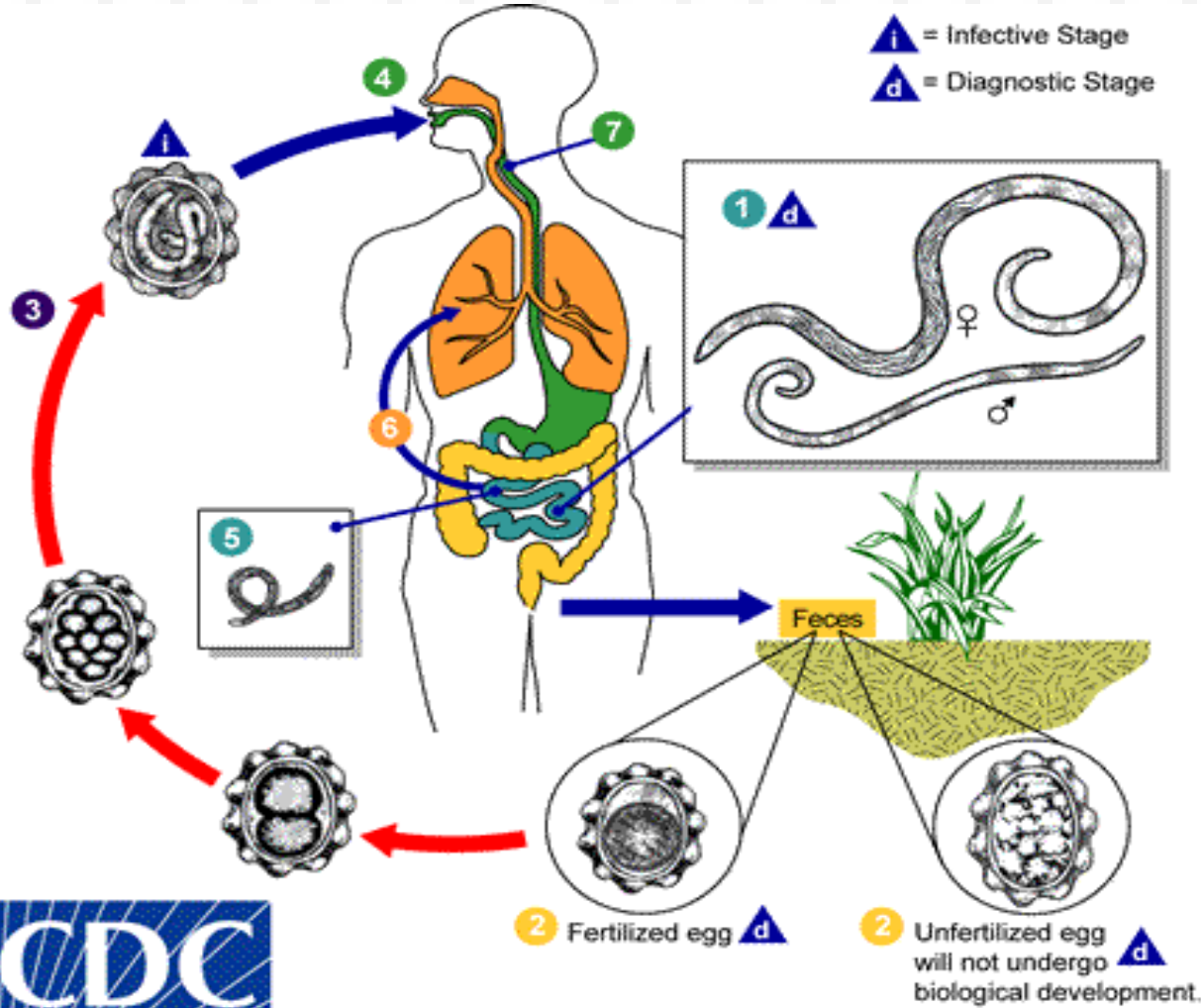
An adult *Ascaris* worm



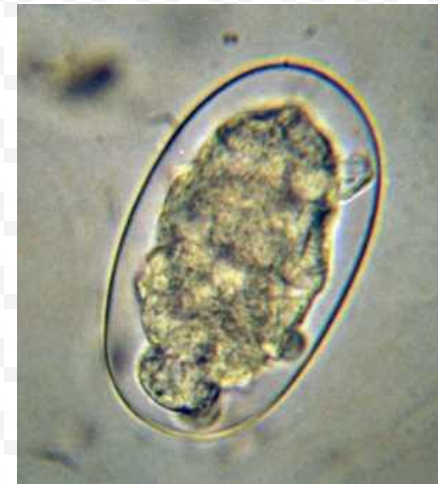
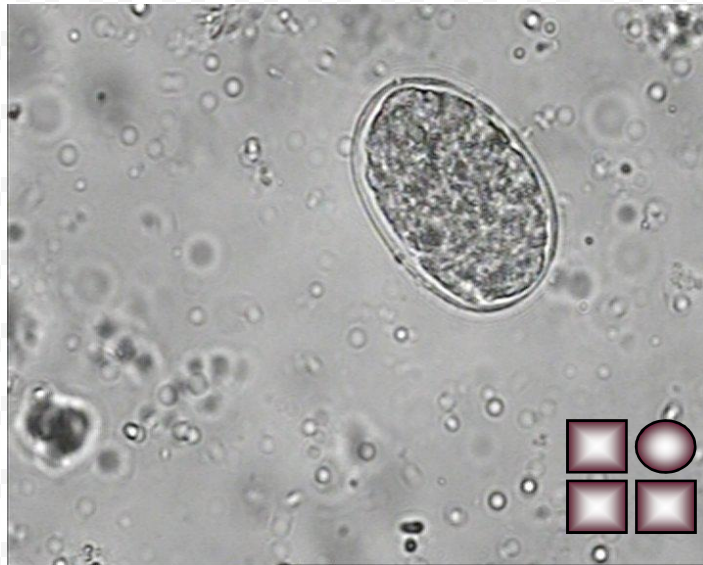
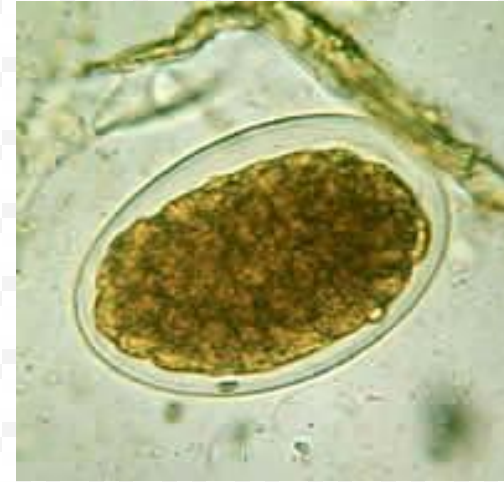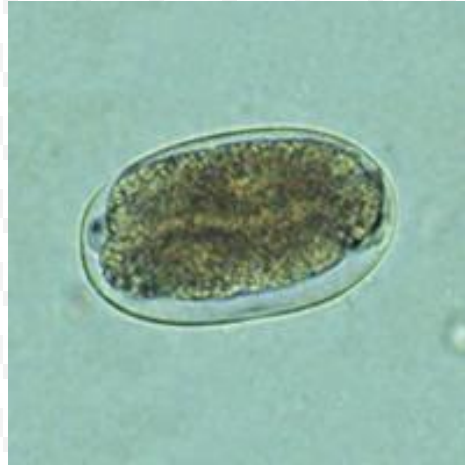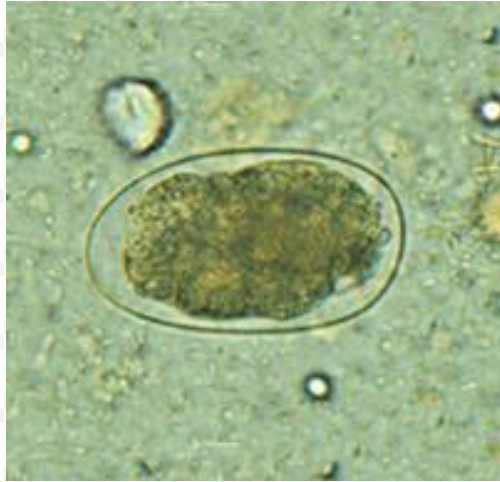Laboratorio Patologia Clinica - P.O. Teramo
Settore di Batteriologia

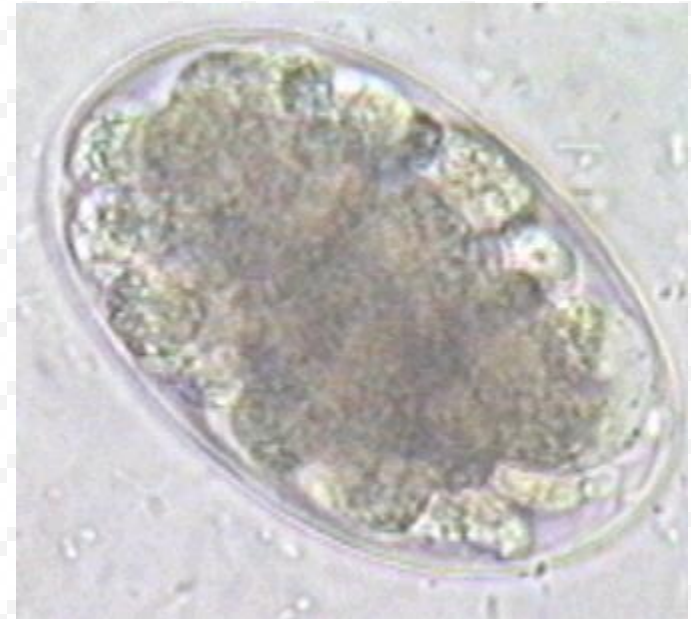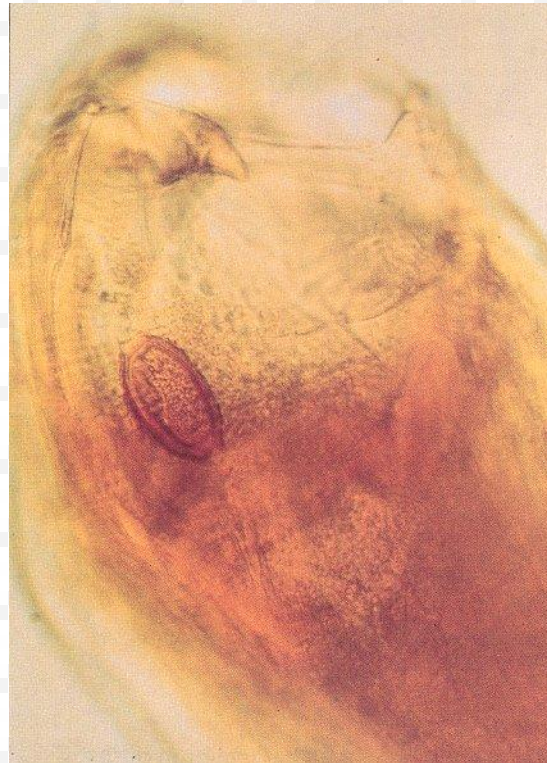
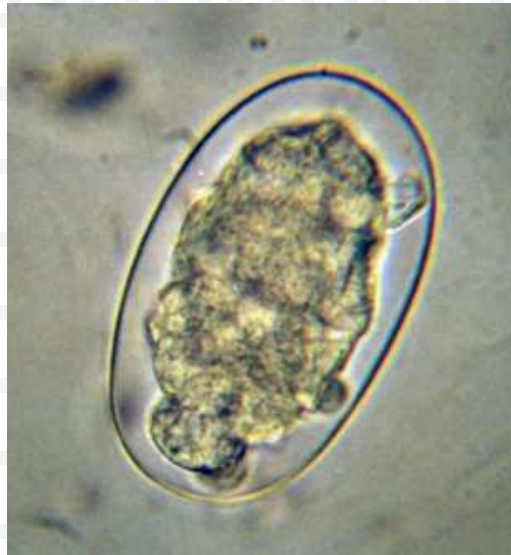Life cycle of *Ascaris lumbricoides*.

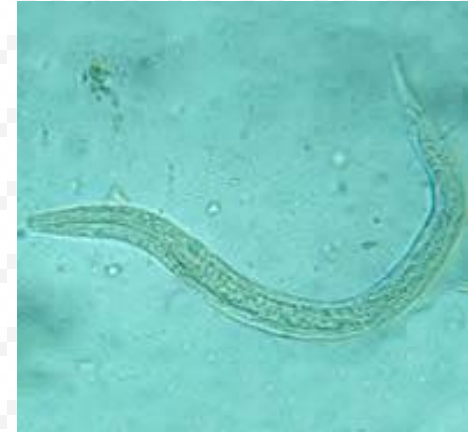
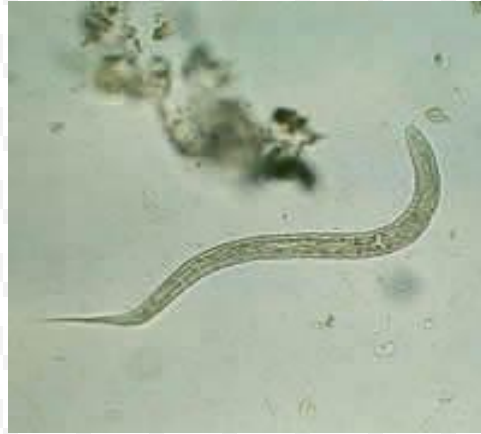
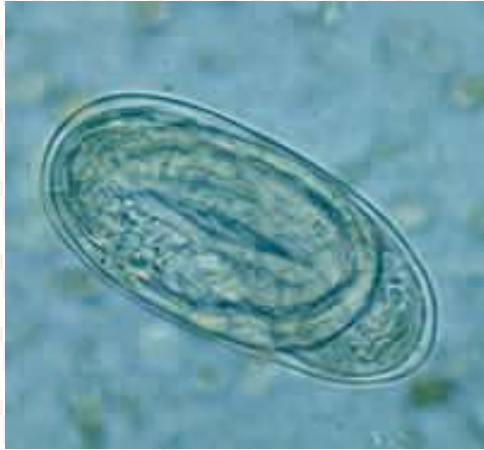Hookworm



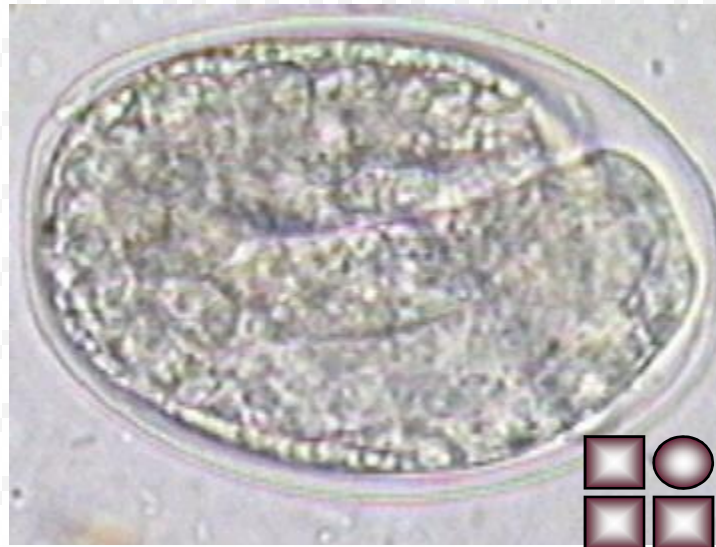
Hookworm





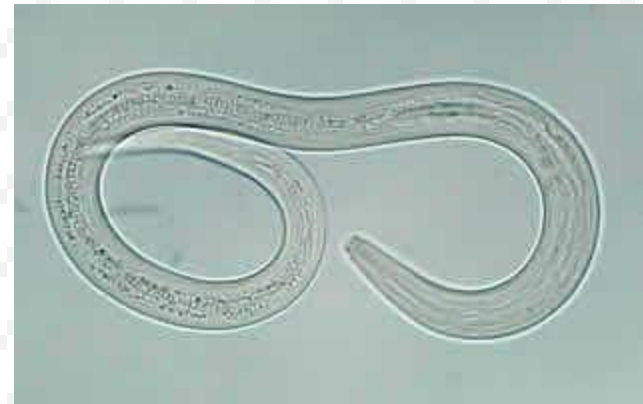
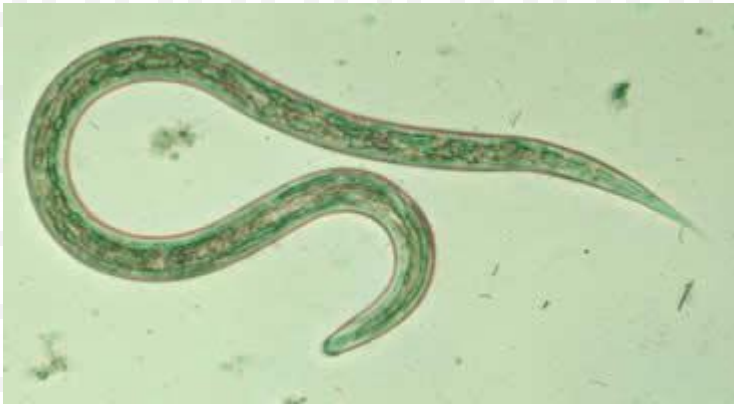Embryonated hookworm egg.

A, B: Hookworm rhabditiform larva (wet preparatio).



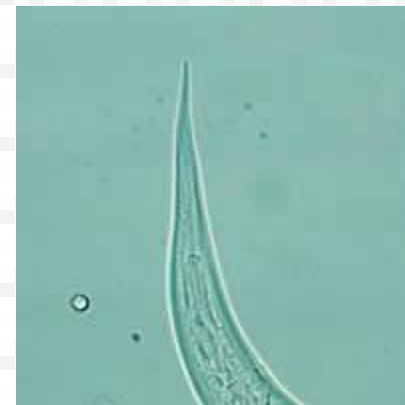

Hookworm



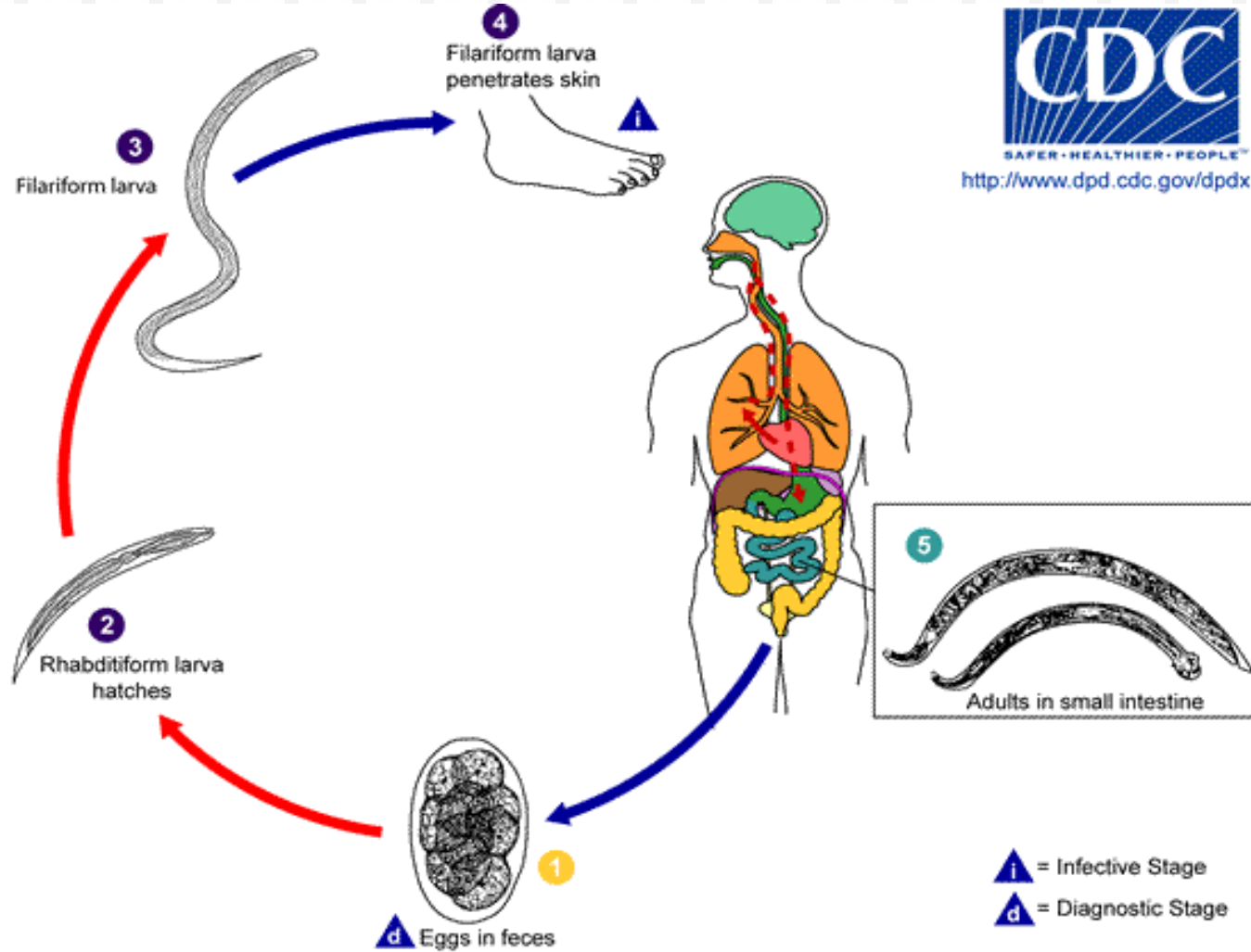
Hookworm filariform larva (wet preparation)

Hookworm filariform larva tail .

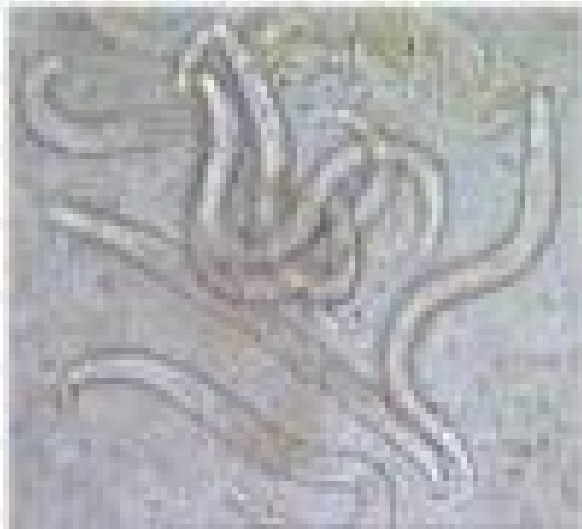



Life cycle of Hookworm



Strongyloides stercoralis

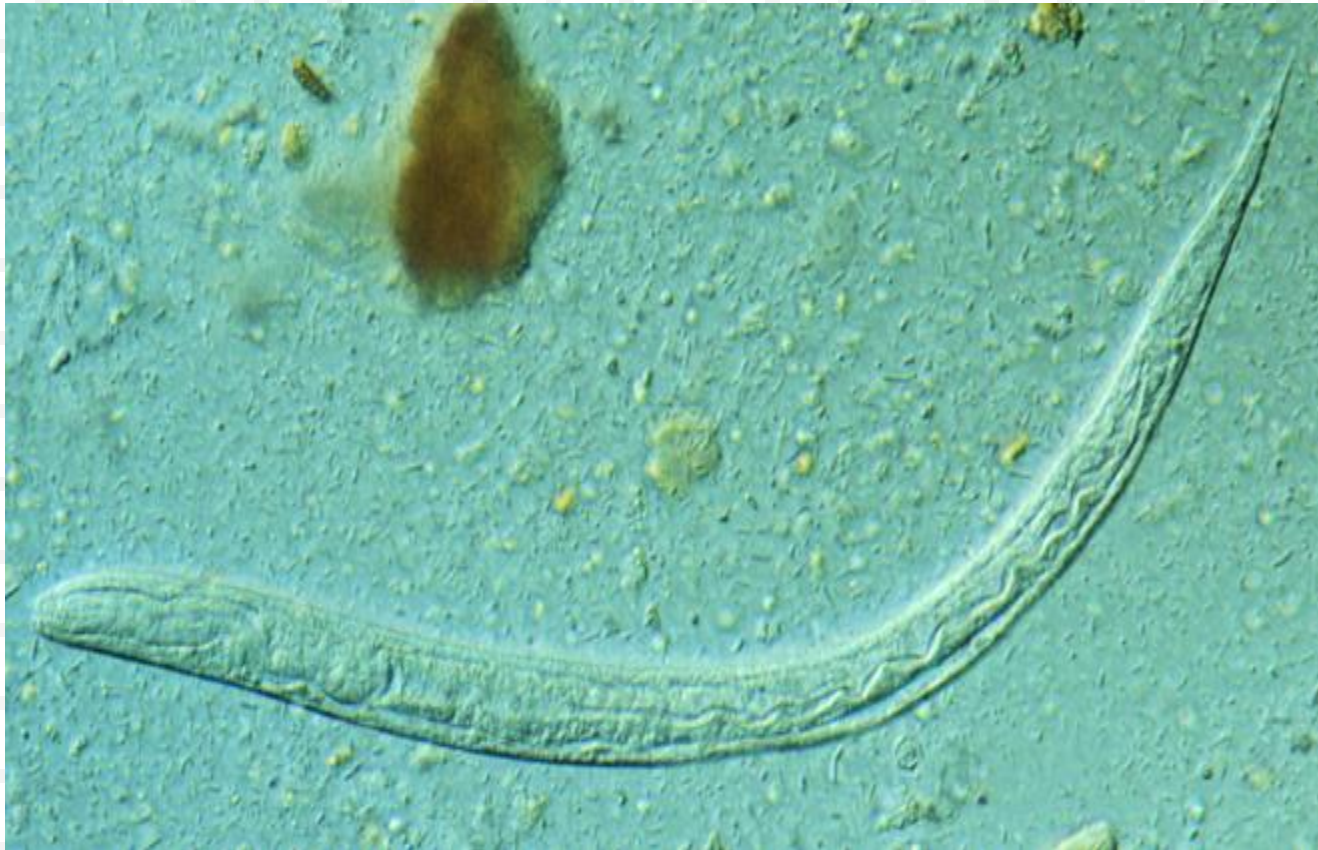

S.T.Larva

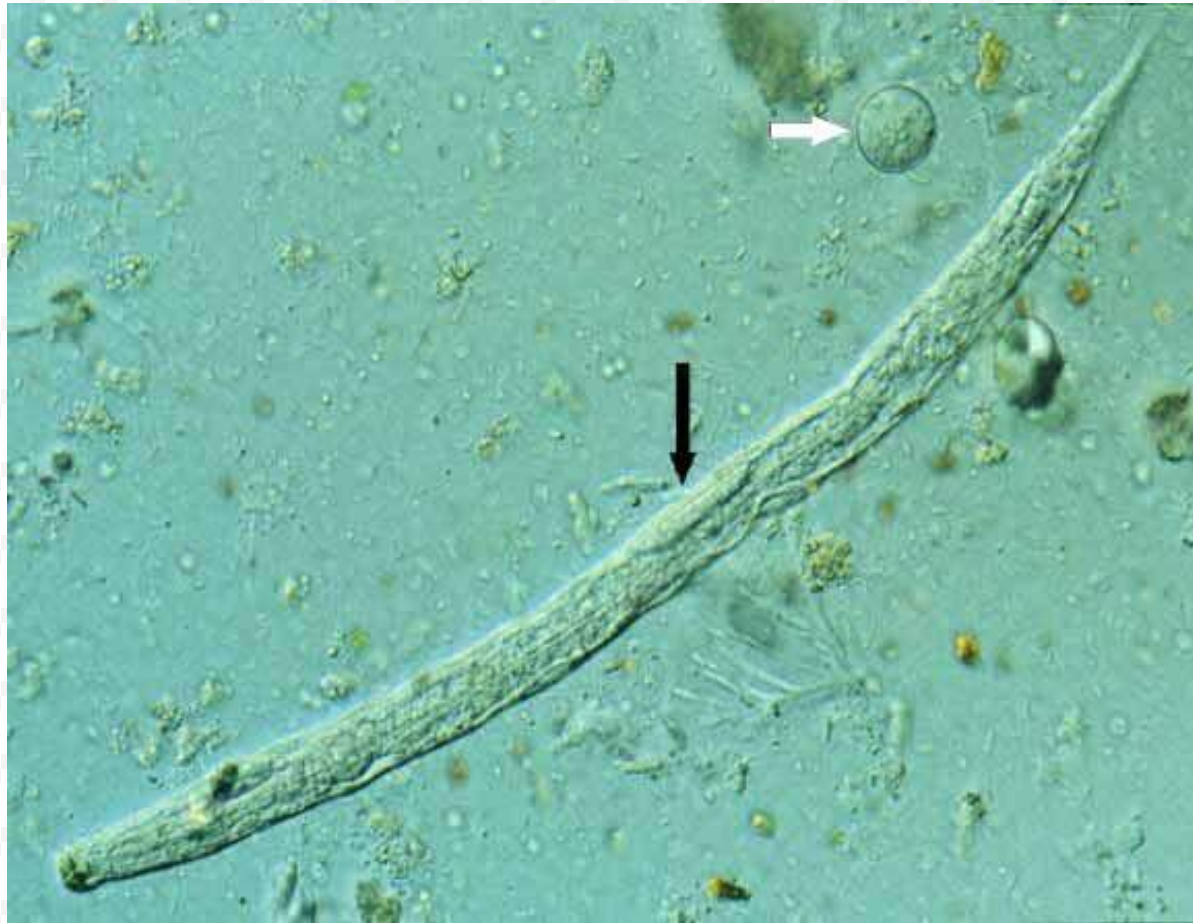

filariform larva tail.

Adult Worm



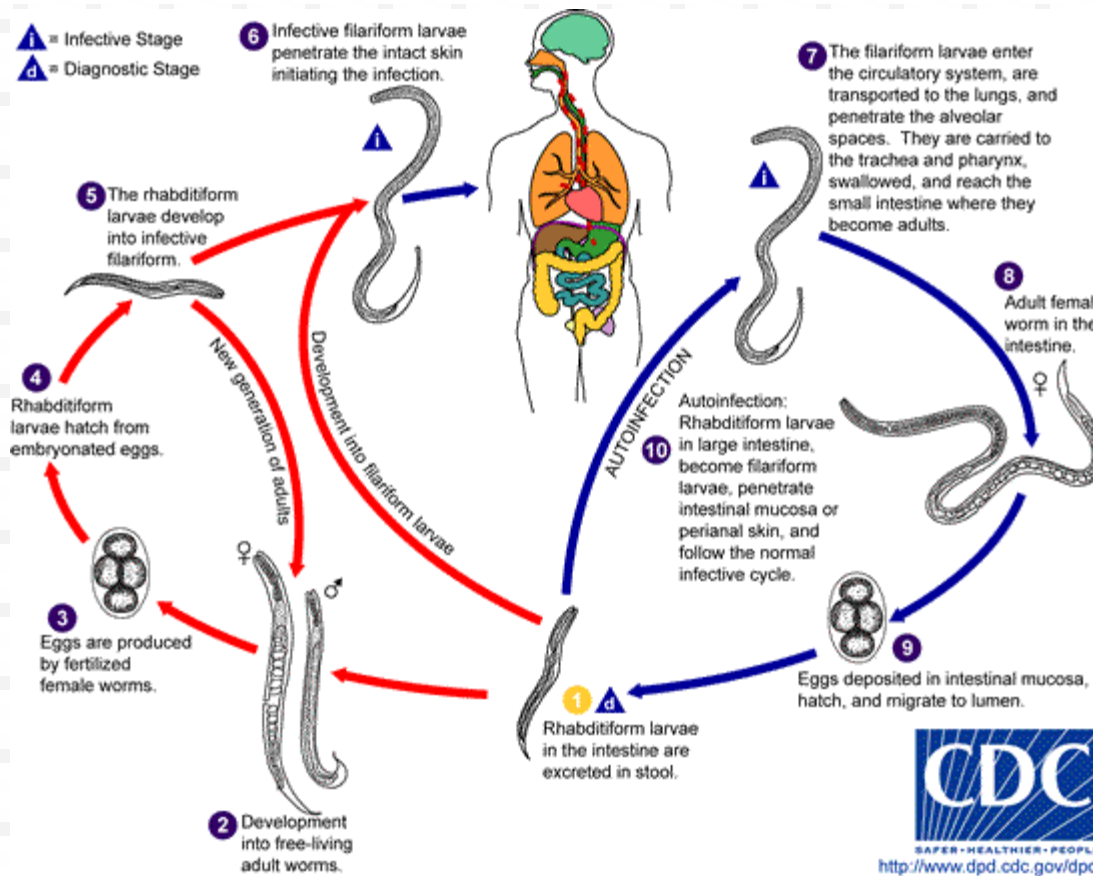
Adult Worm –white Arrow(Coli Cyst)



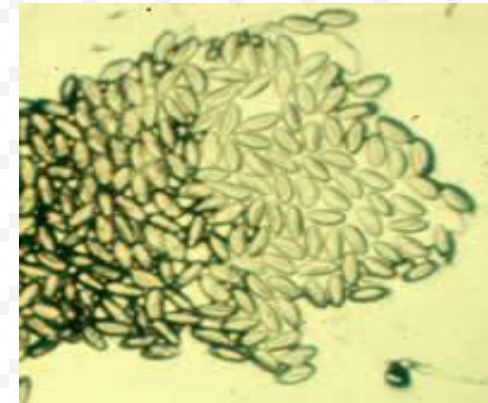
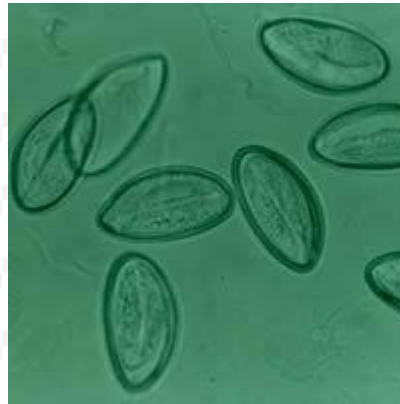
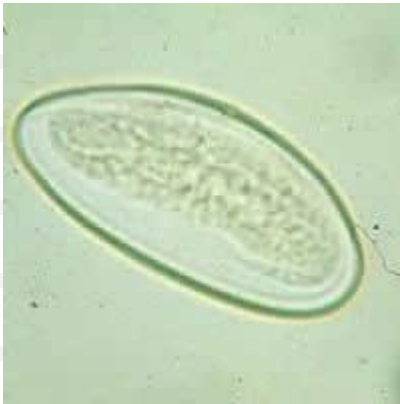

وزارت بهداشت، درمان و آموزش پزشکی

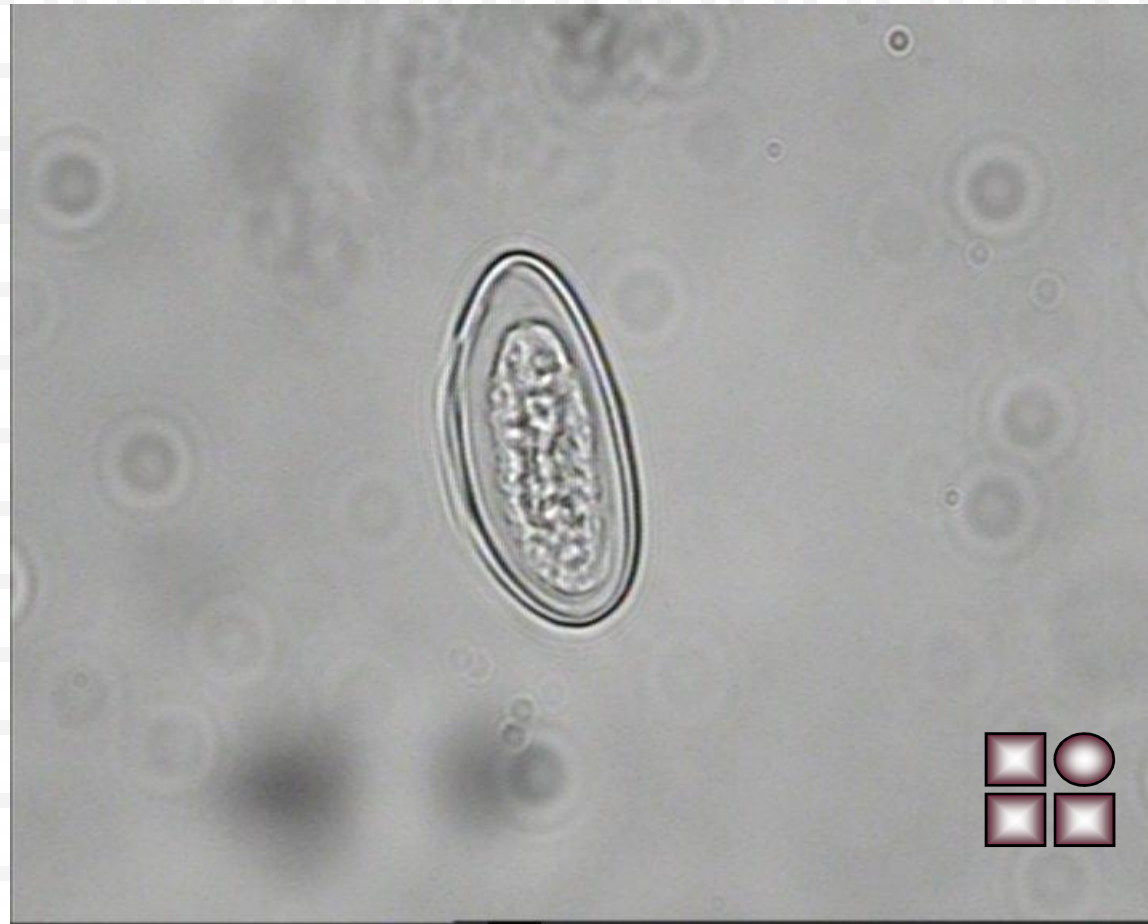Life cycle of *Strongyloides stercoralis*



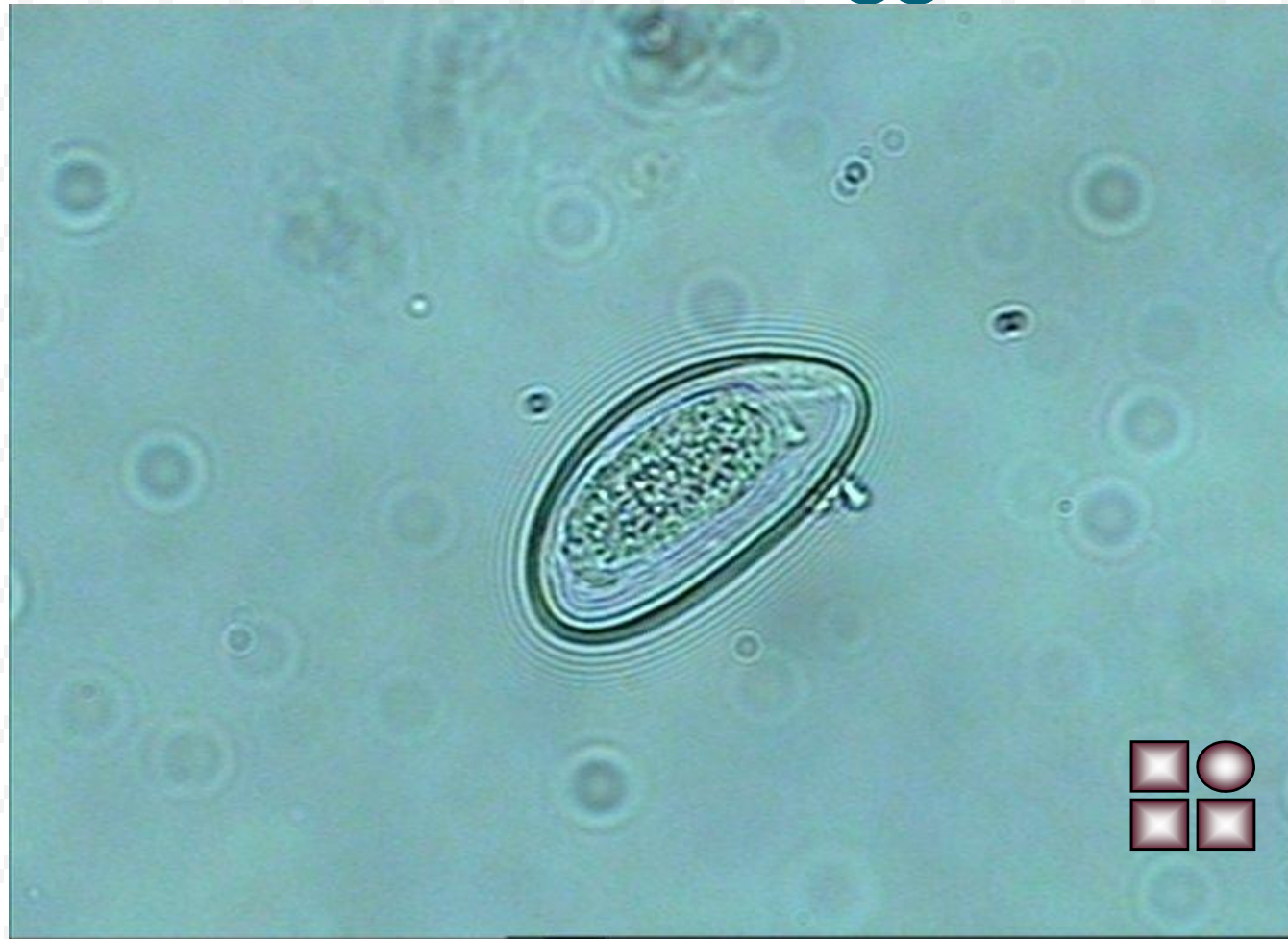
Enterobius Vermicularis eggs



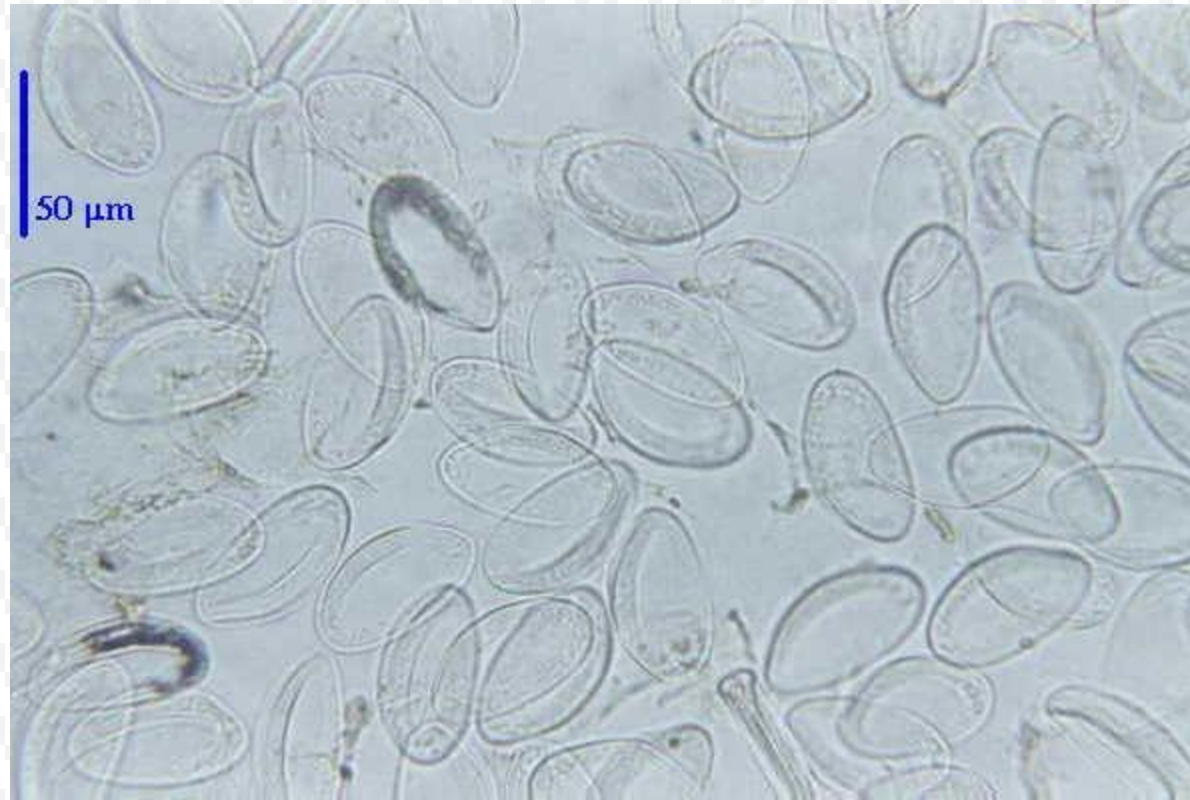Enterobius Vermicularis egg




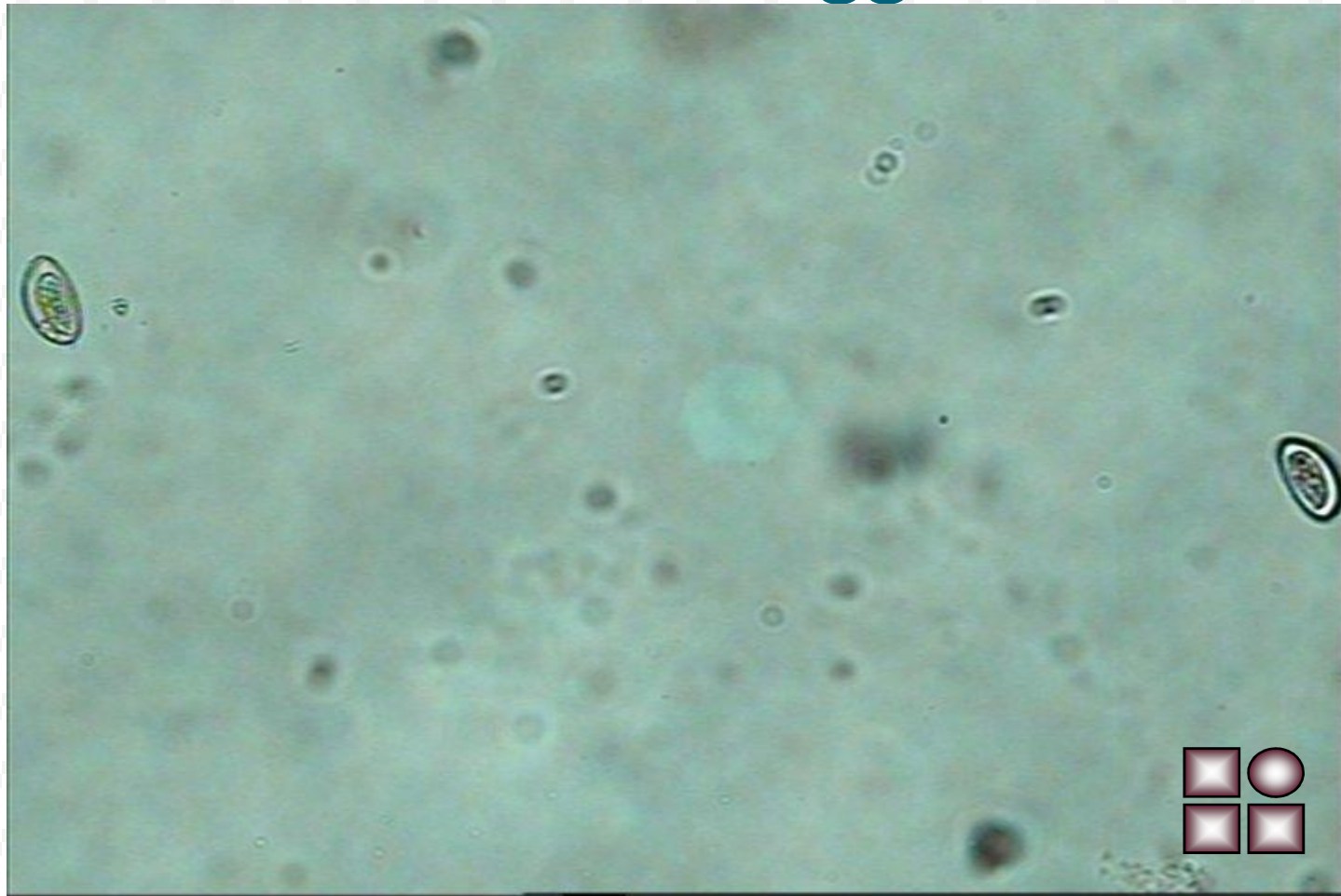
Enterobius Vermicularis egg

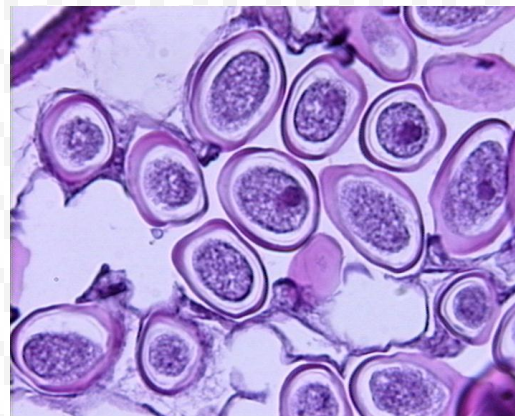
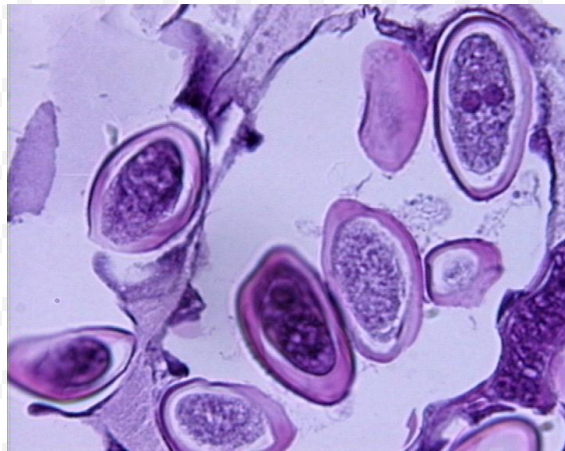
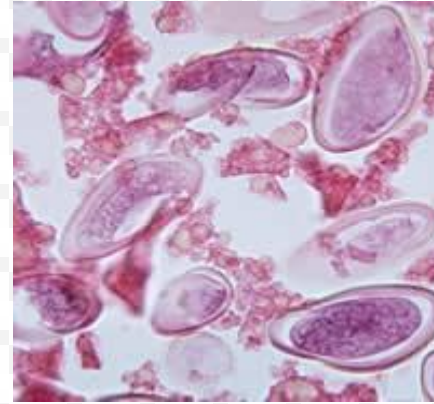
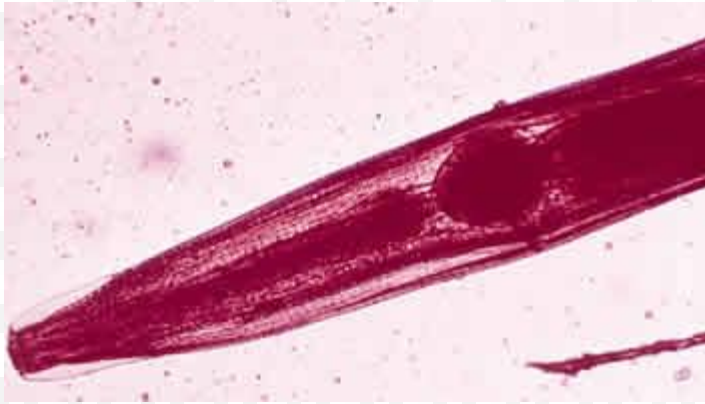

Enterobius Vermicularis eggs



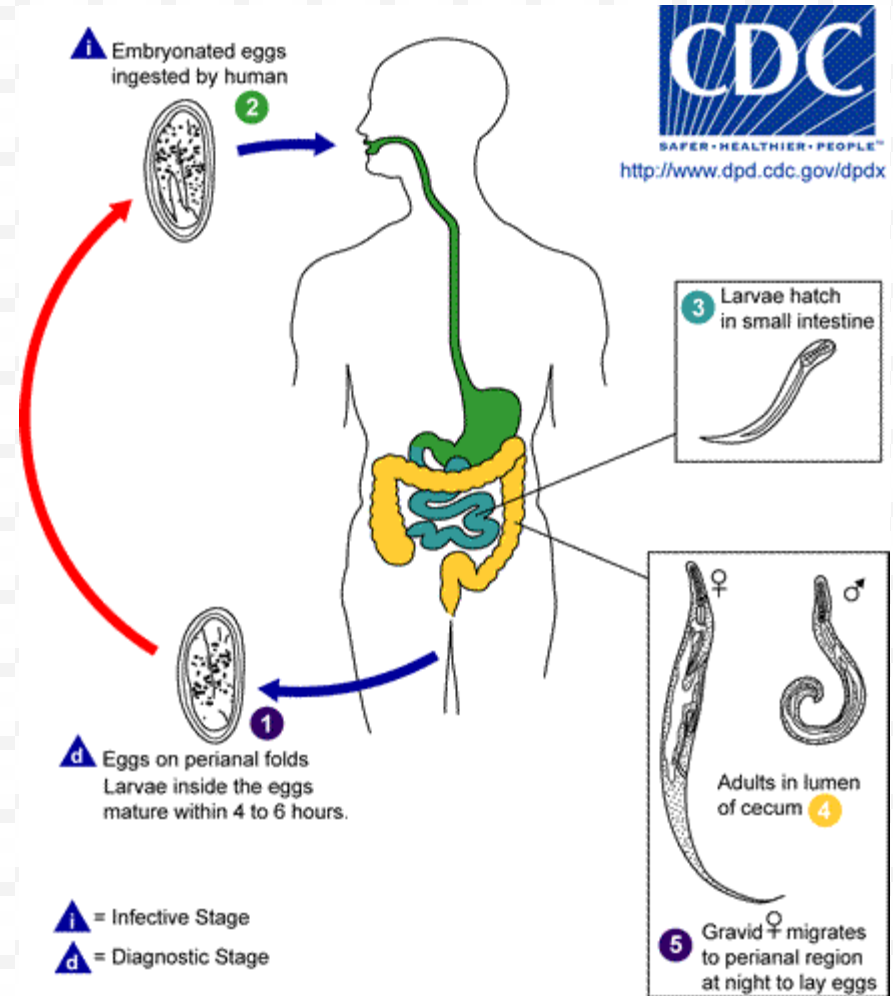
Enterobius Vermicularis eggs



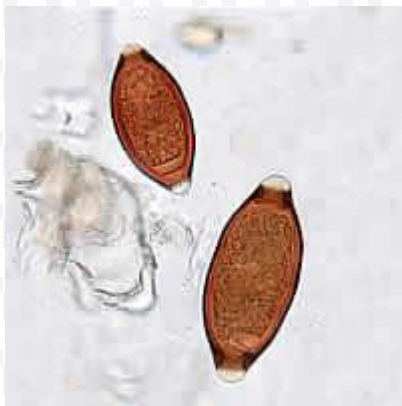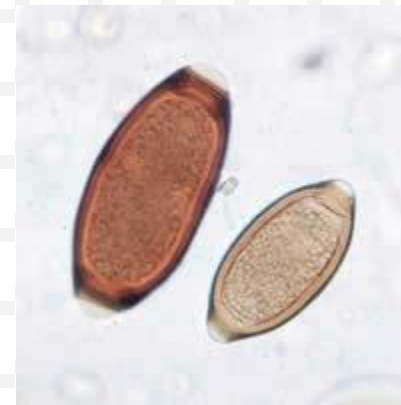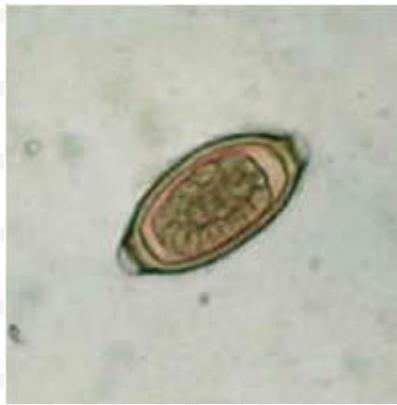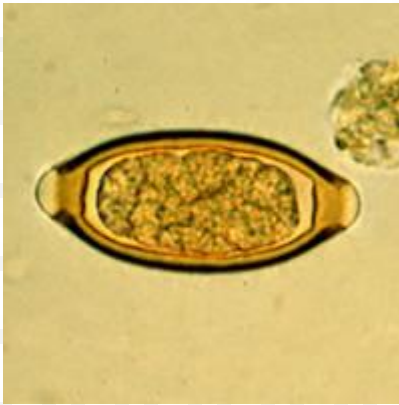




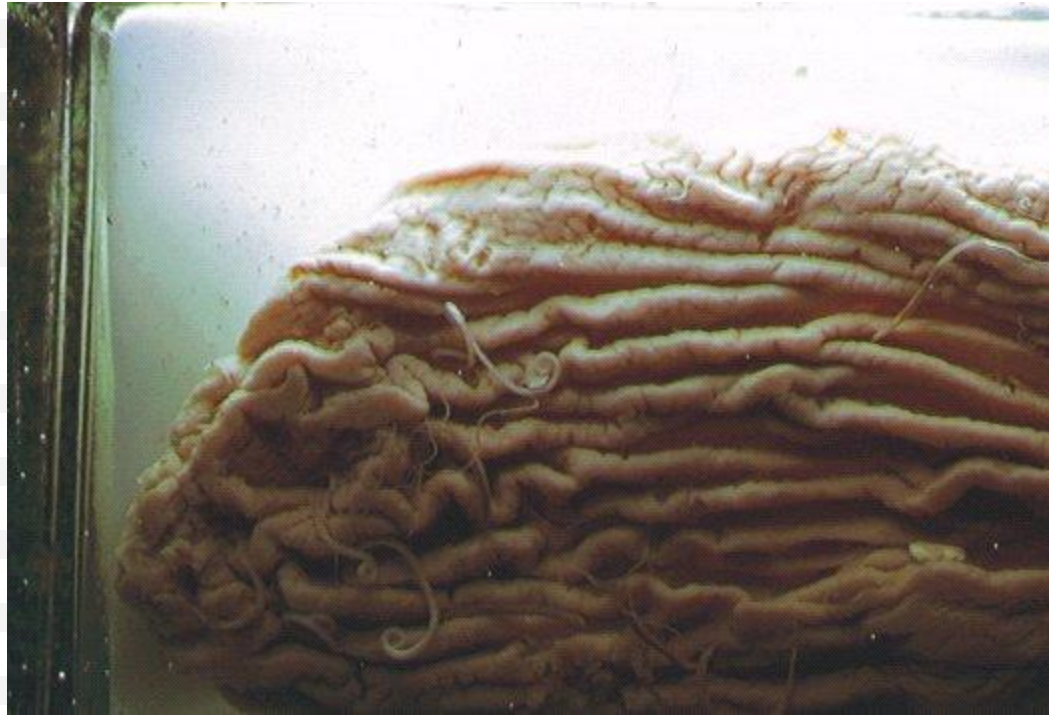
Life cycle of *Enterobius vermicularis*



Trichuris trichiura eggs

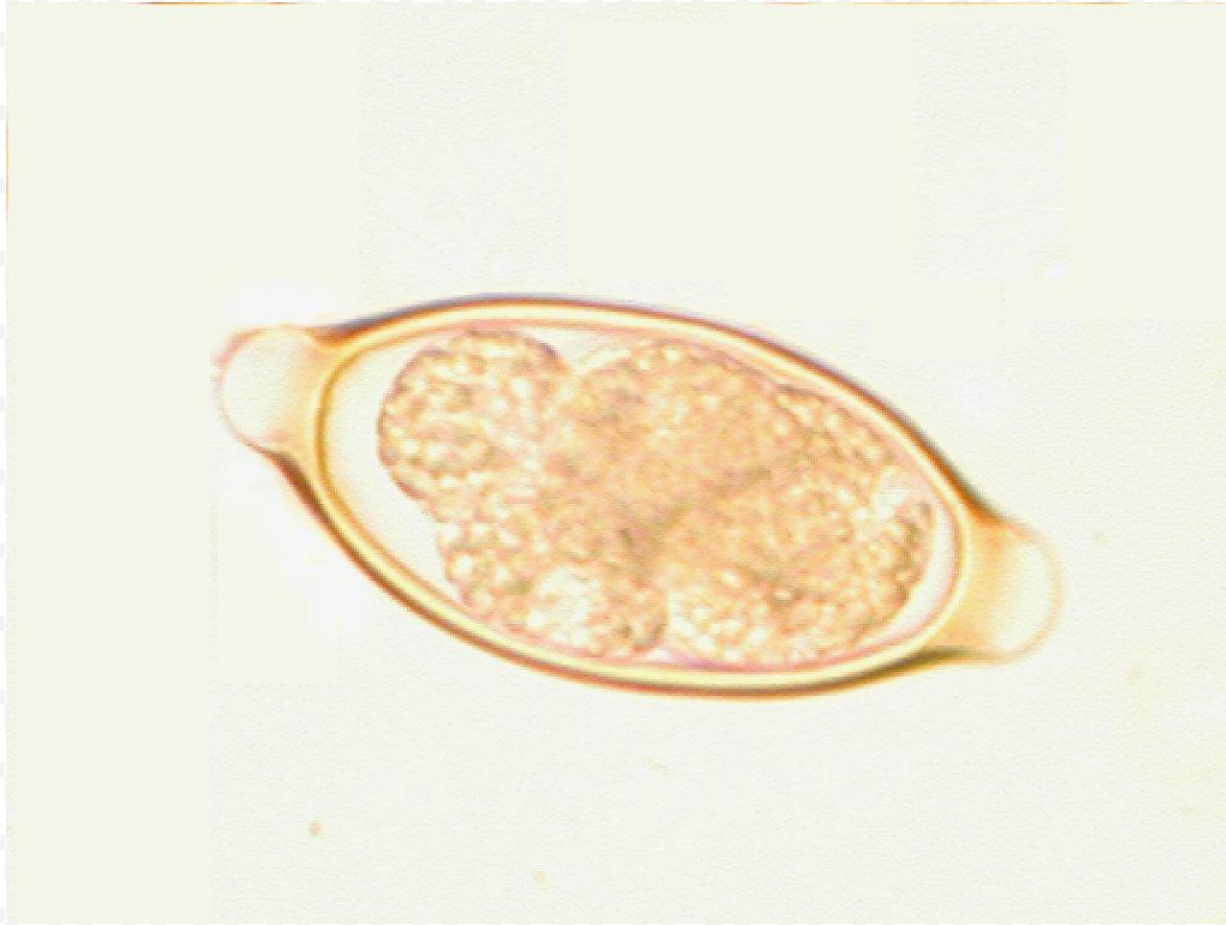

Adult Worms

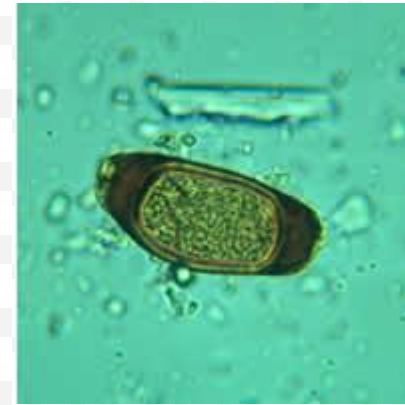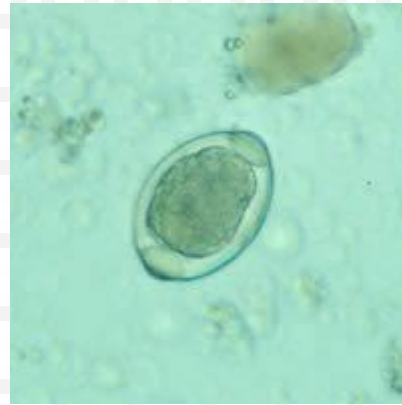


Trichuris trichiura
adults in gut (preserved post mortem specimen)

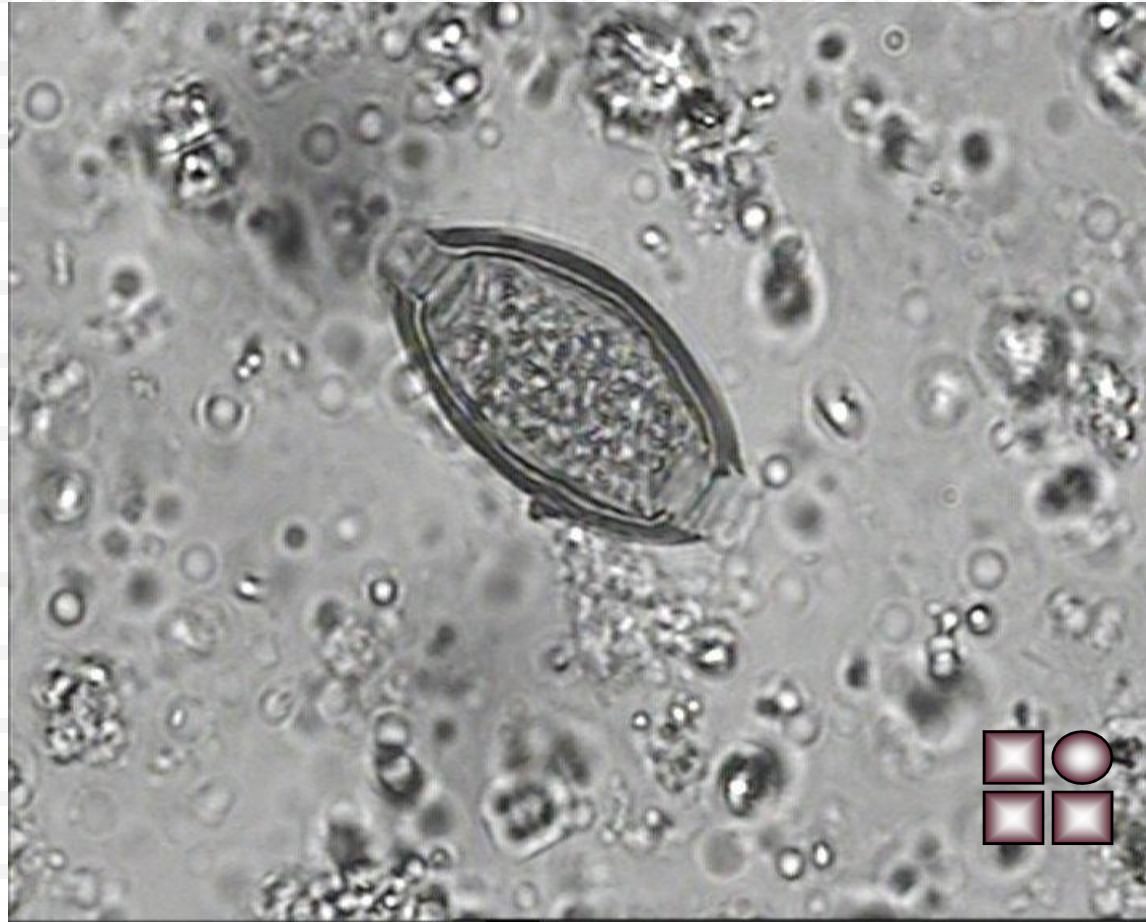Trichuris trichiura egg



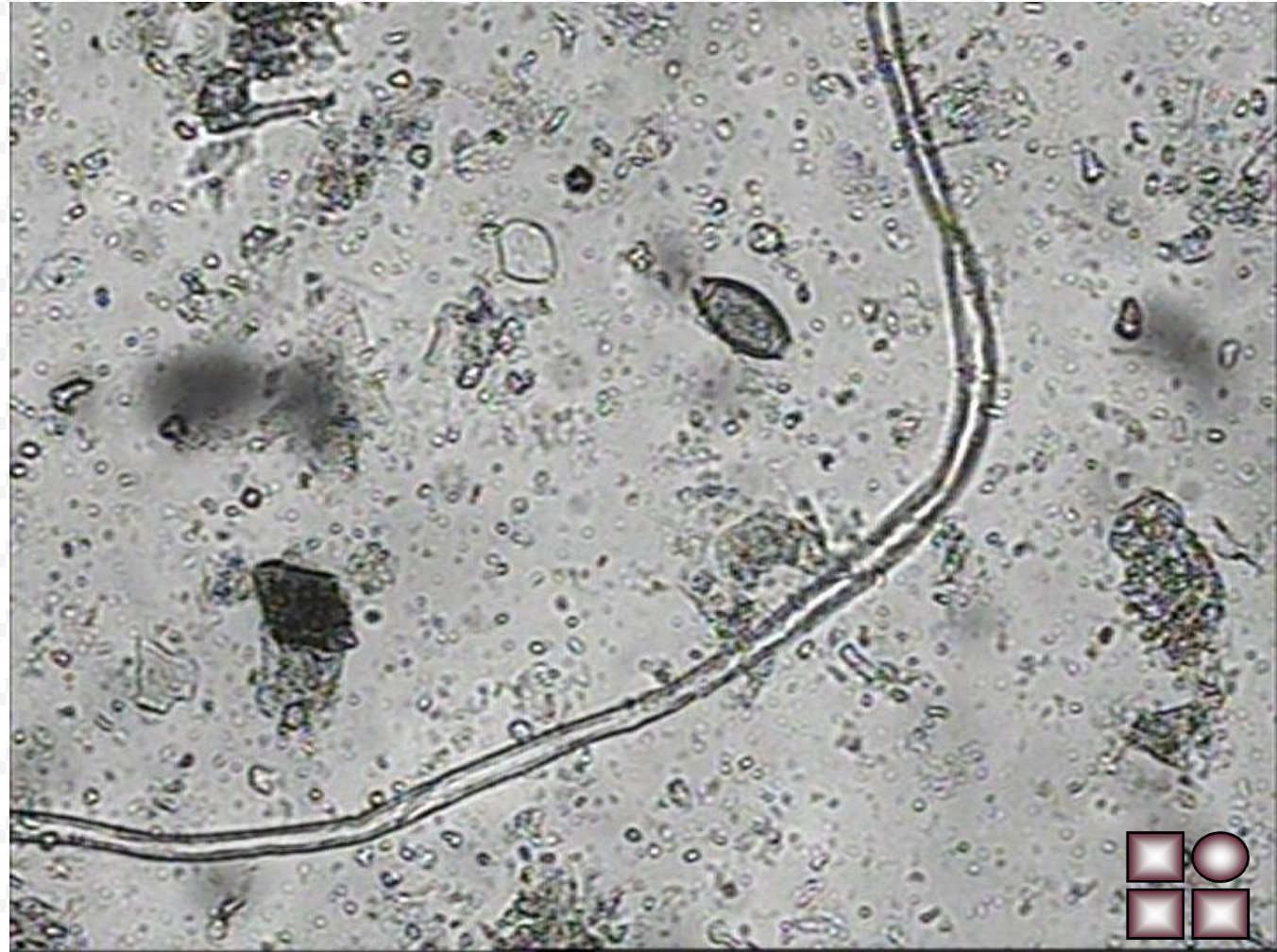
Atypical *Trichuris* sp. eggs.



Trichuris trichiura egg

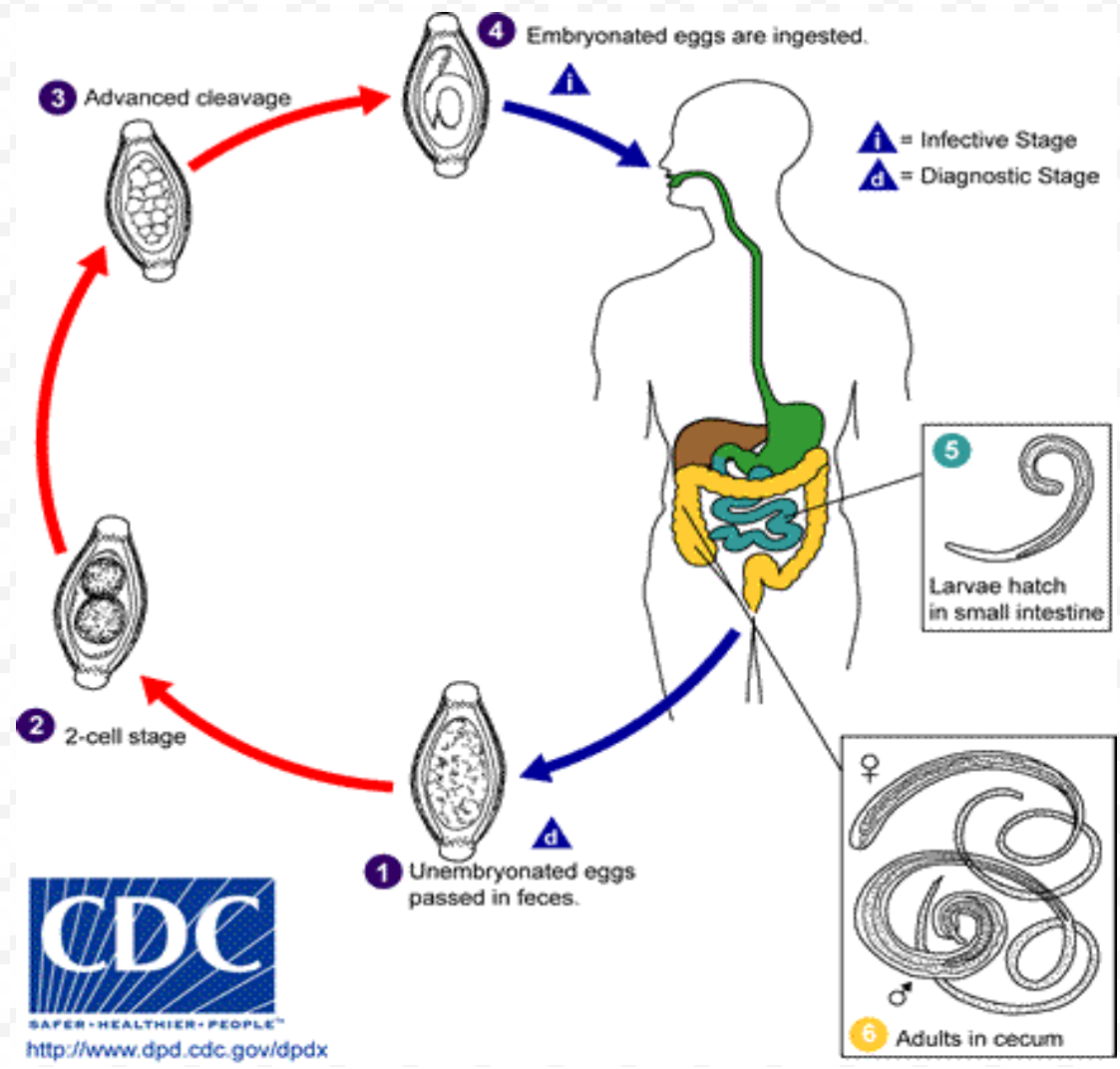


Trichuris trichiura egg

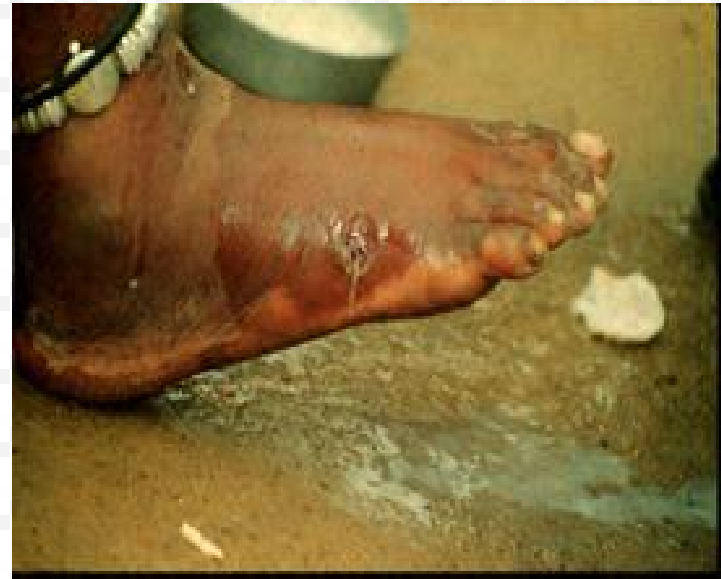
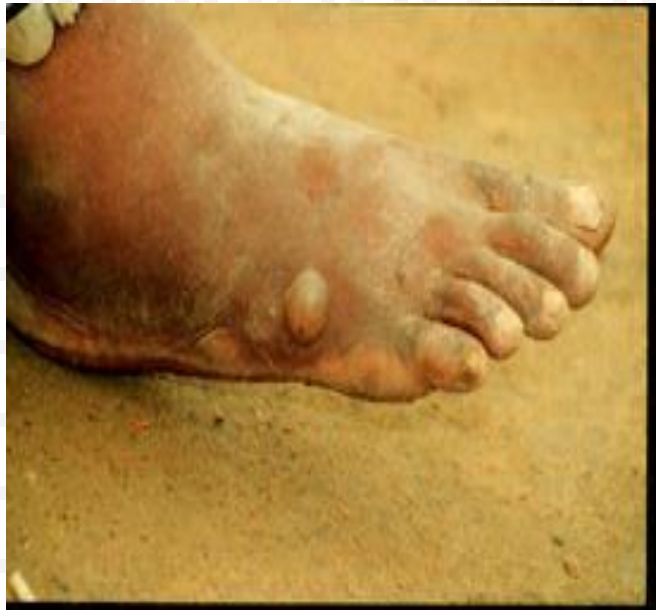


Life cycle of *Trichuris trichiura*

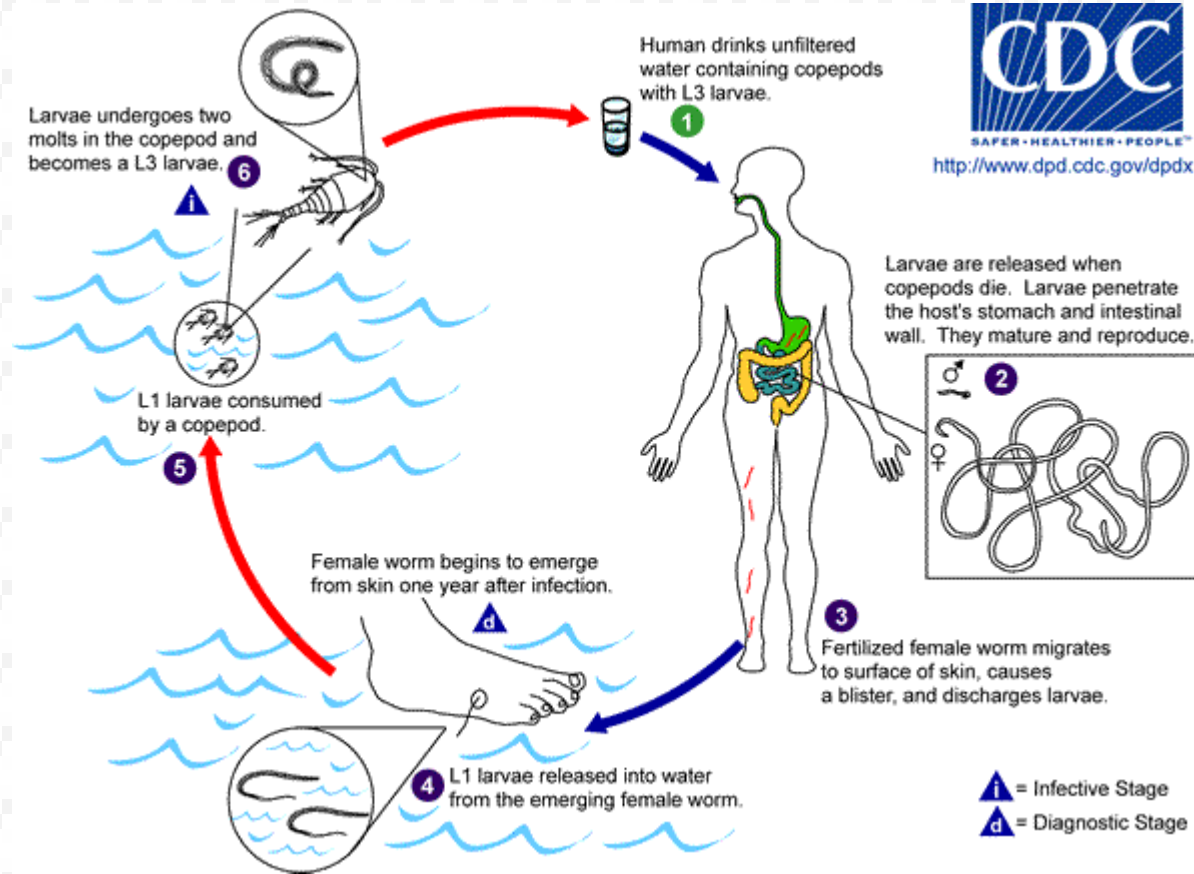


Dracunculus medinensis

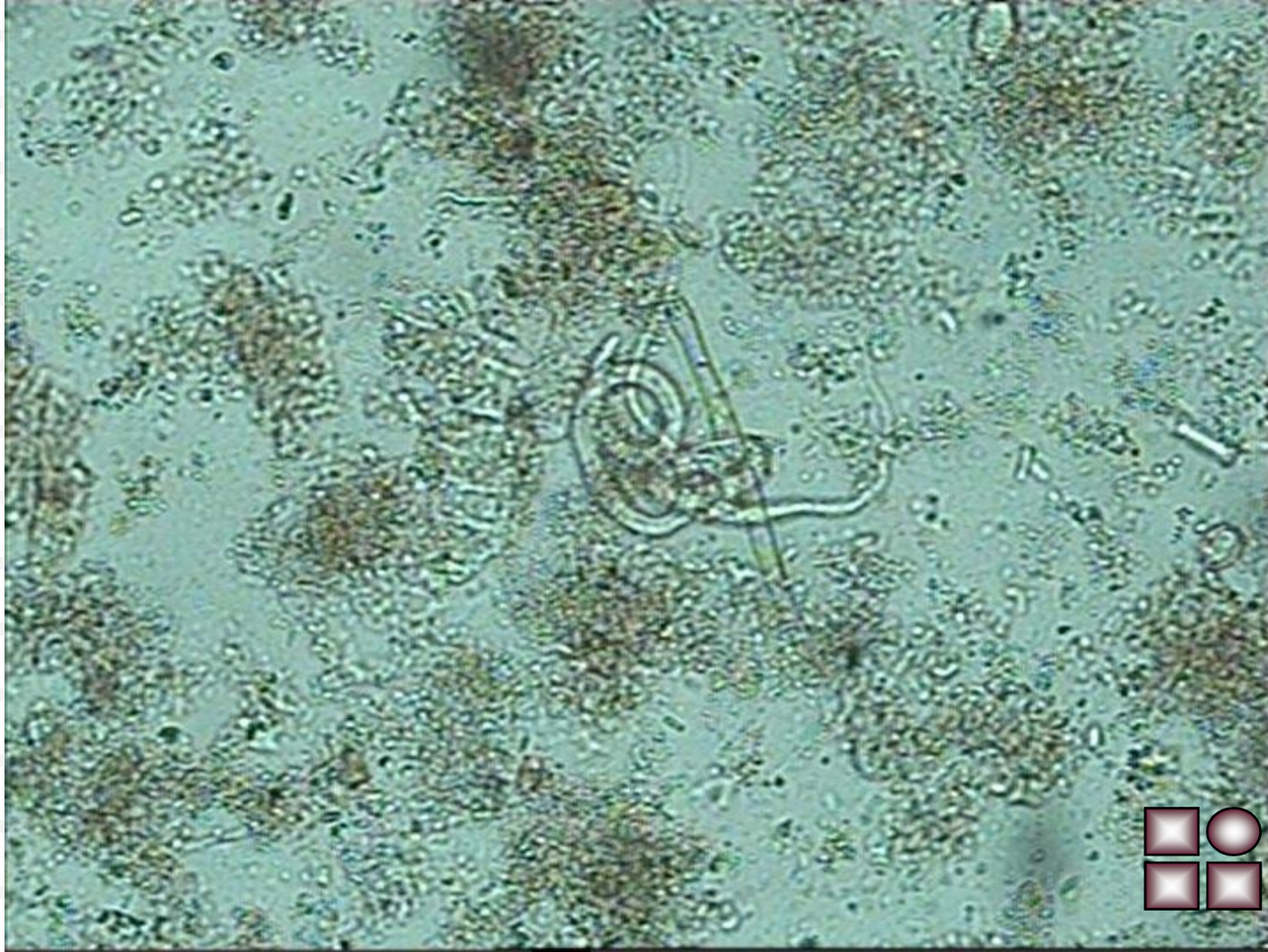


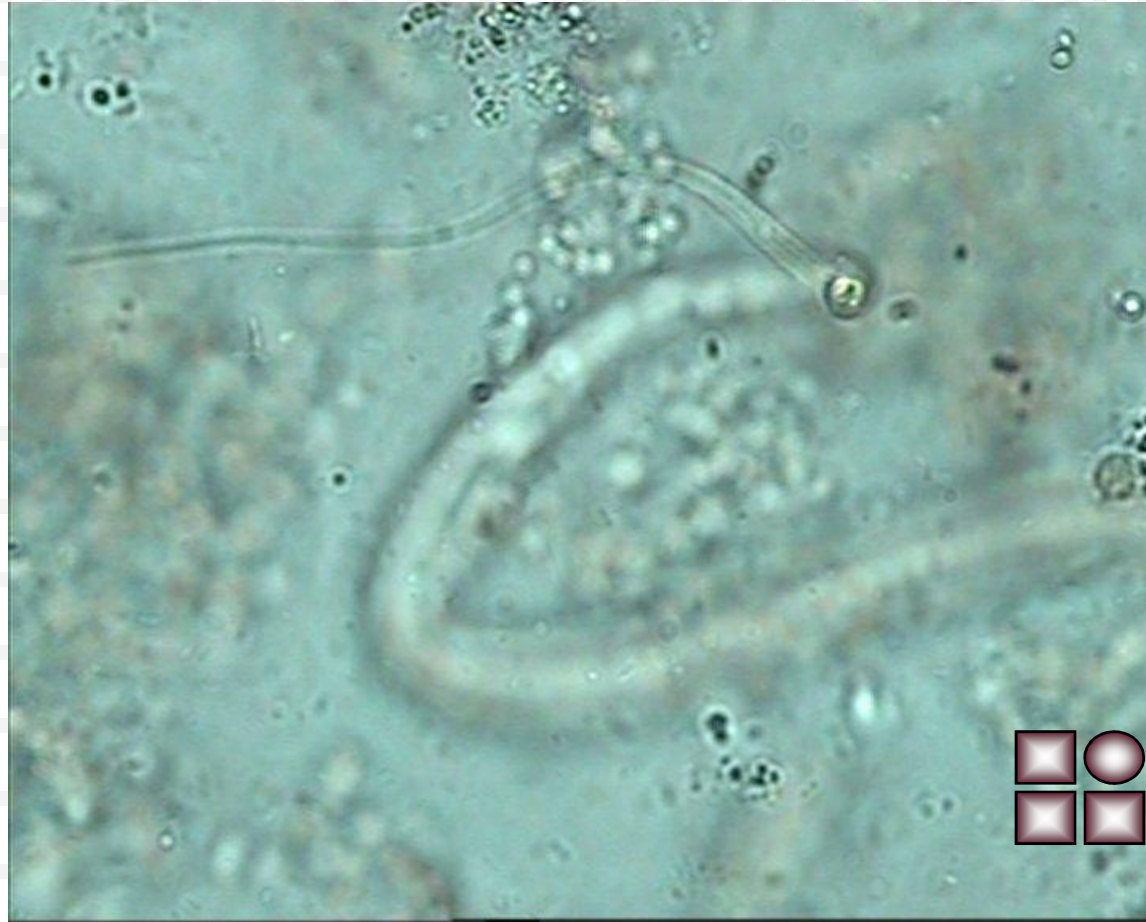

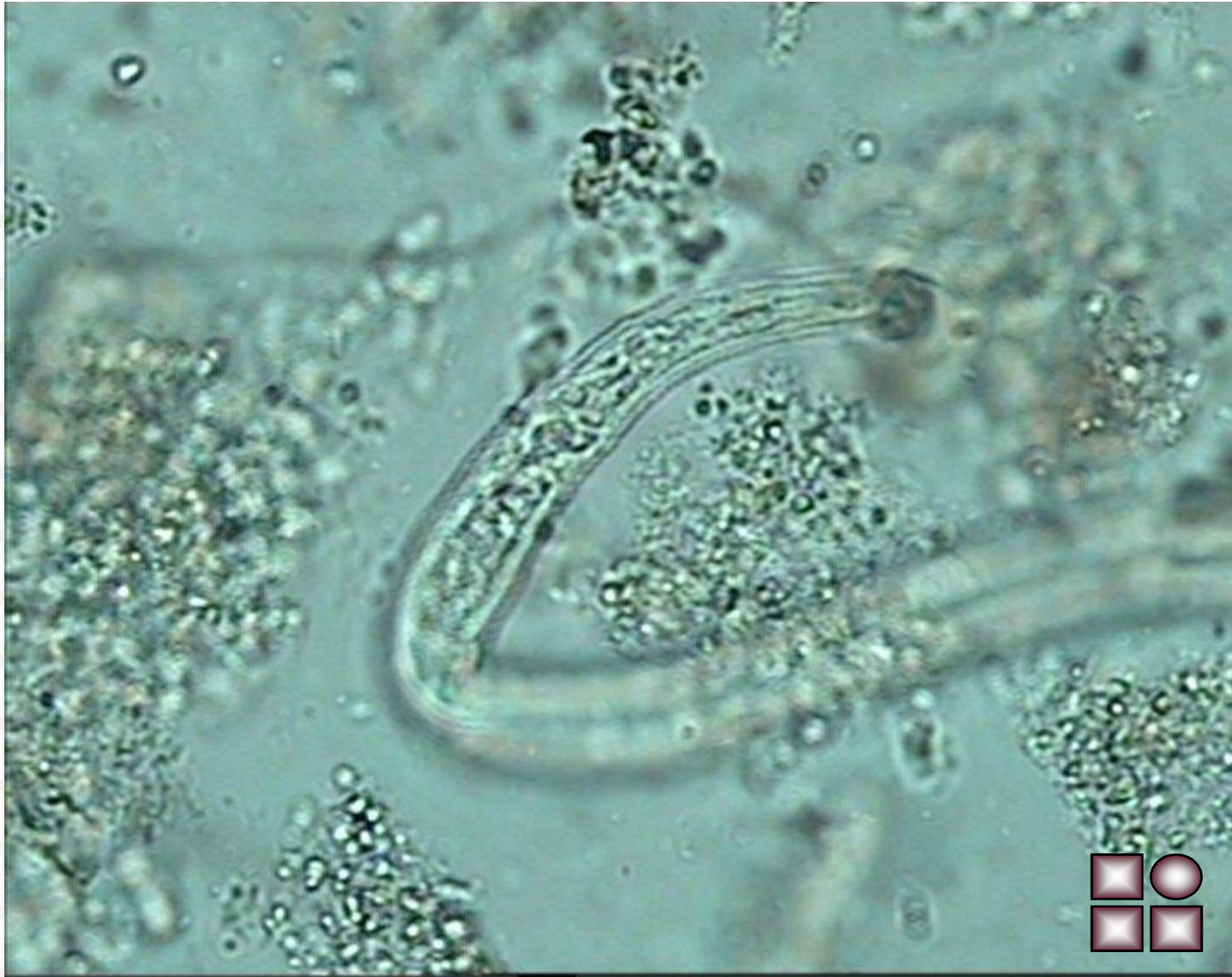Life cycle of *Dracunculus medinensis*

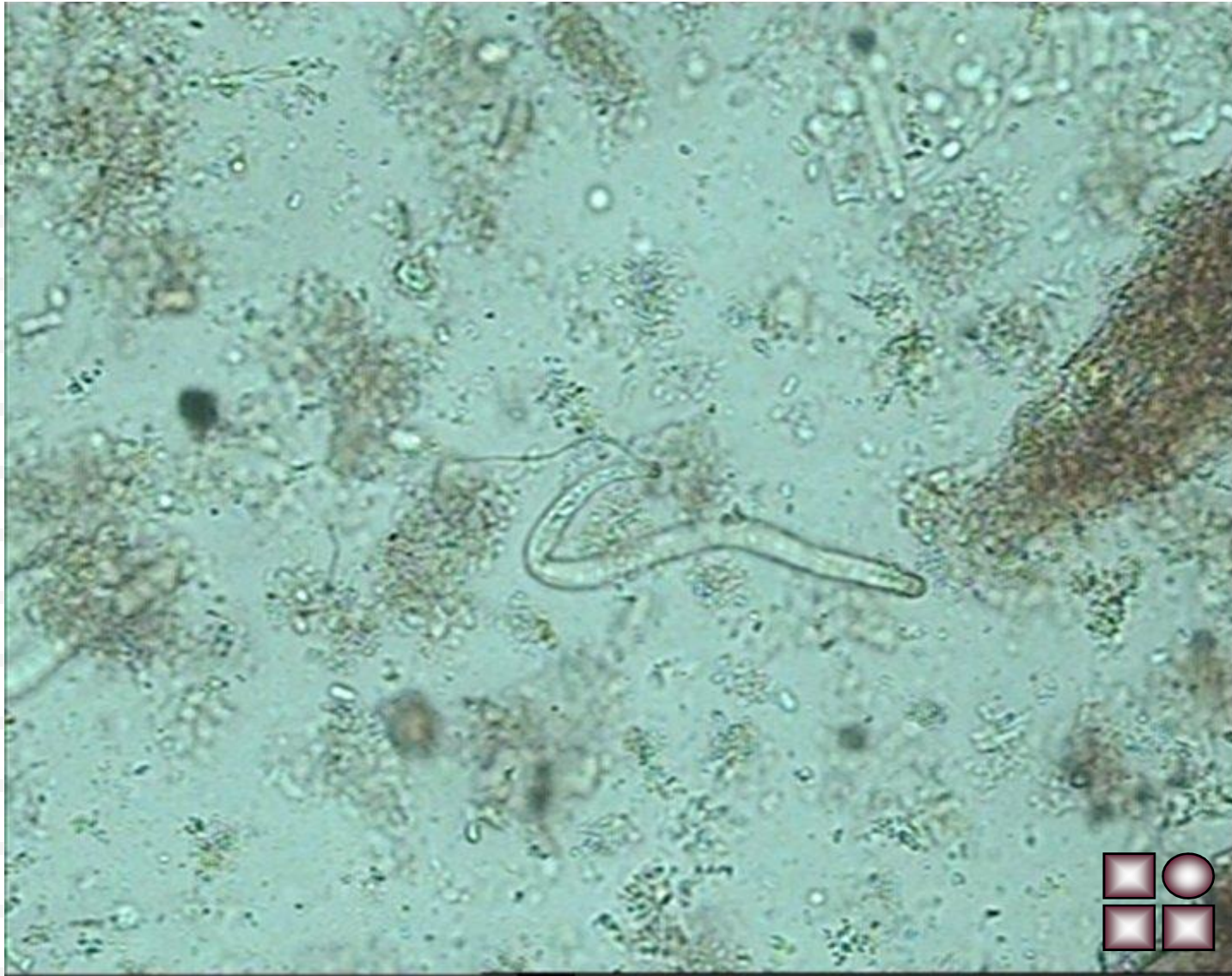


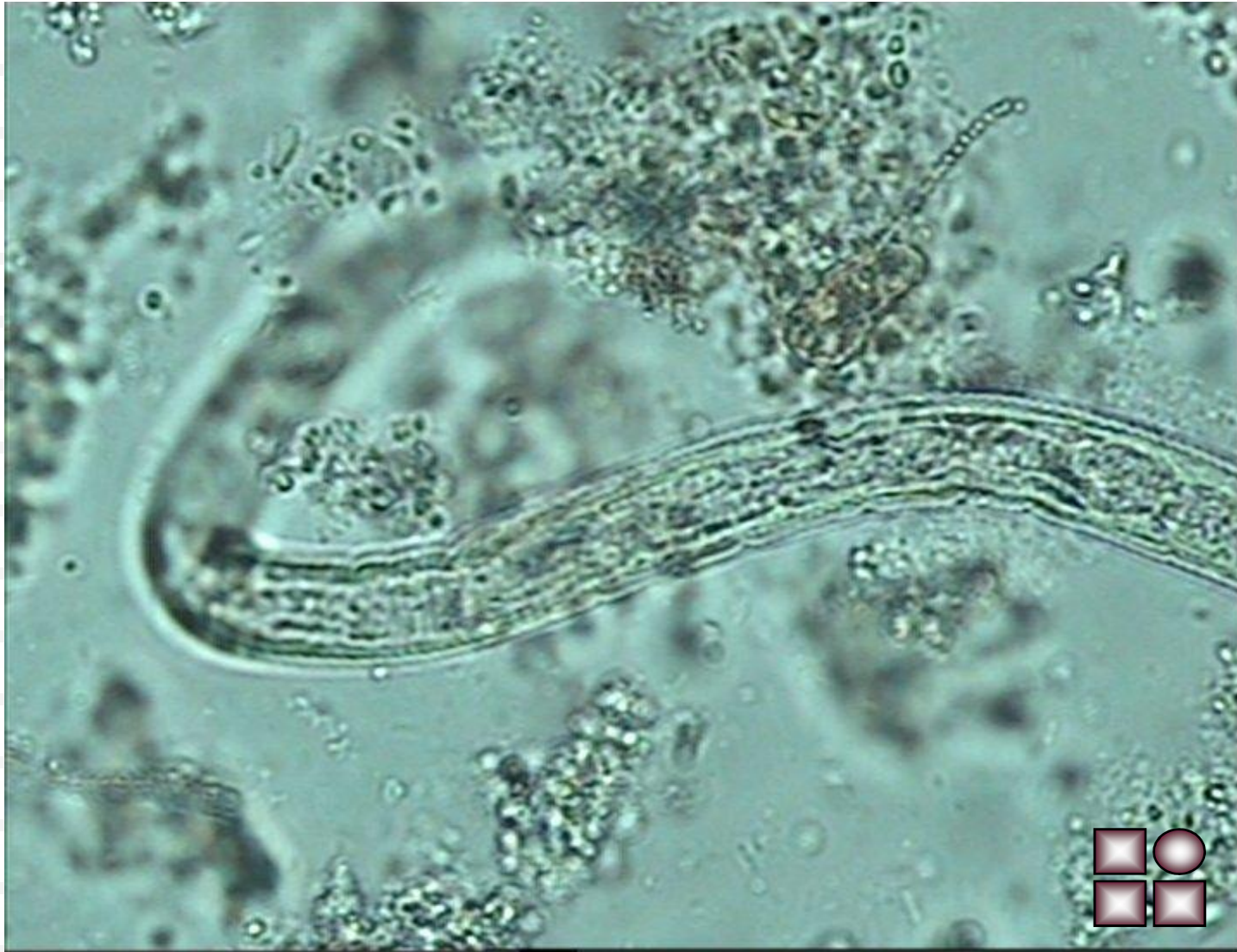لارو پیوک



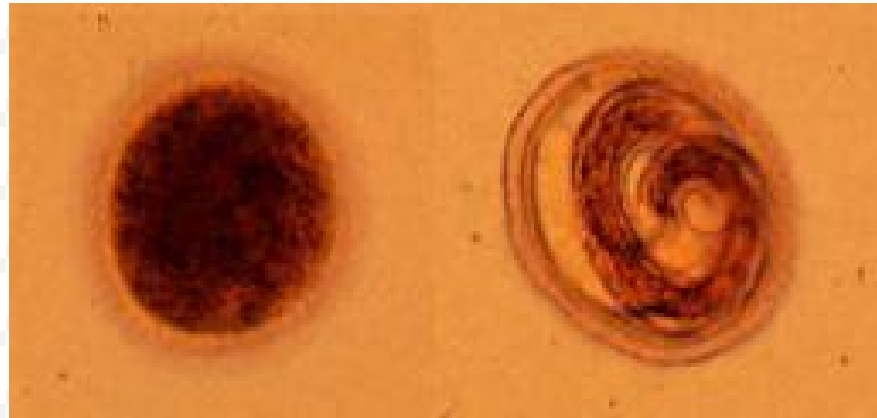








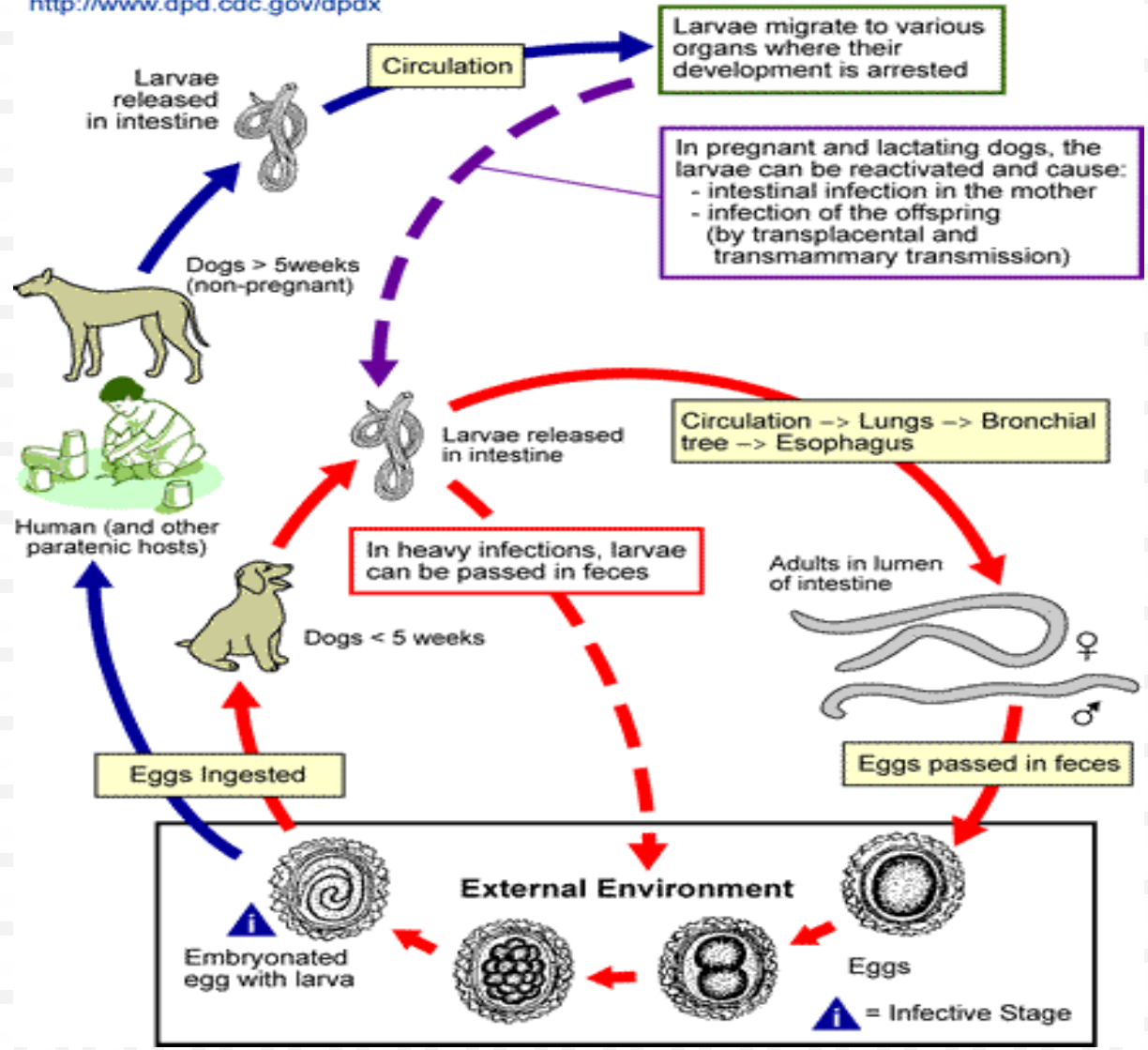
Toxocara canis





Toxocara canis

Life cycle of
Toxocara canis





کرم های نواری انسان

اکینوکوکوس گرانولوزوس

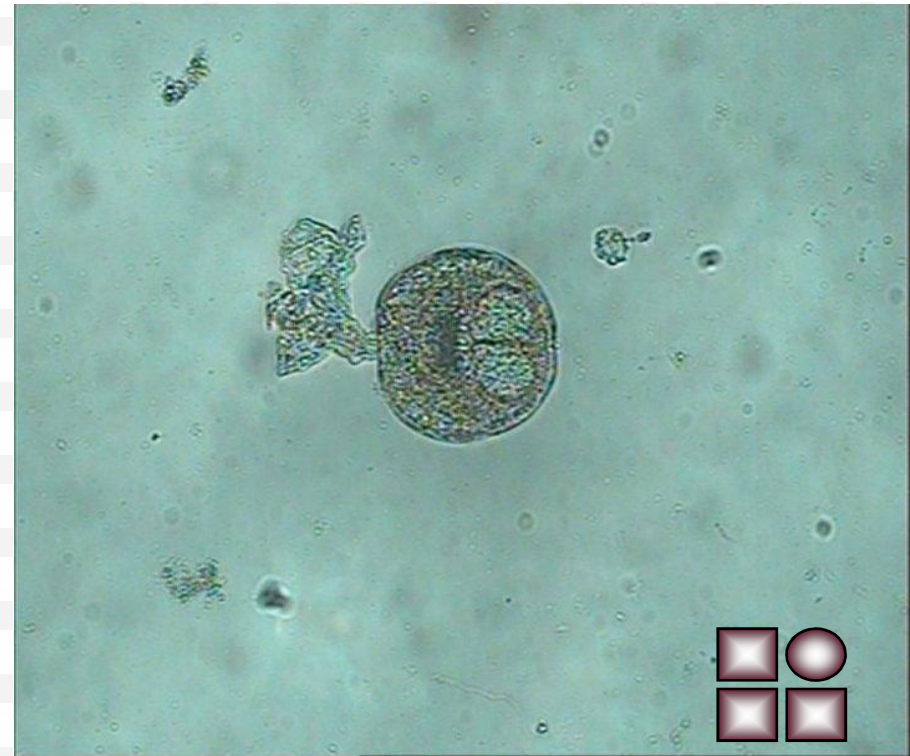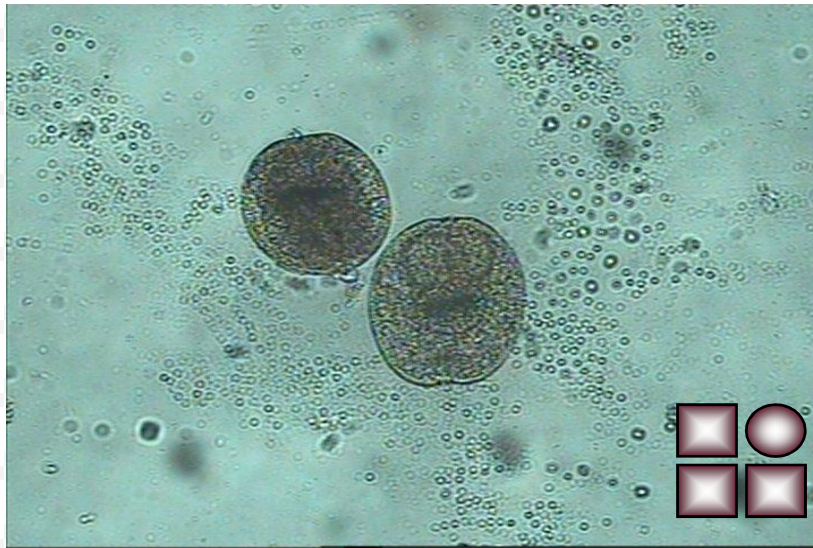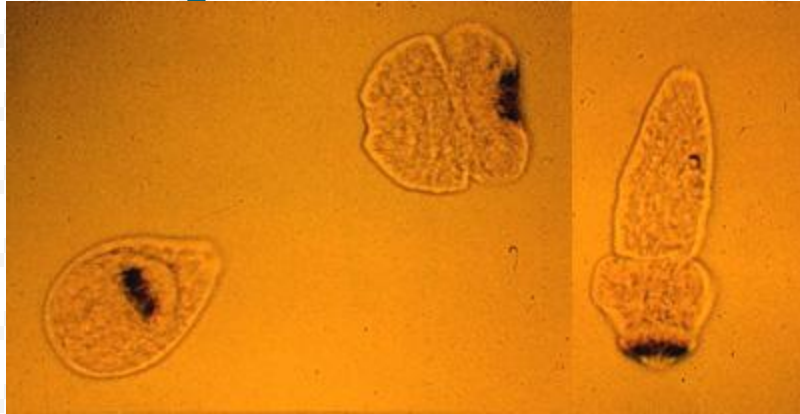
تتیا ساژیناتا

هیمنولیپیس نانا

دیفیلوبوتریوم لاتوم = کرم نواری ماهی

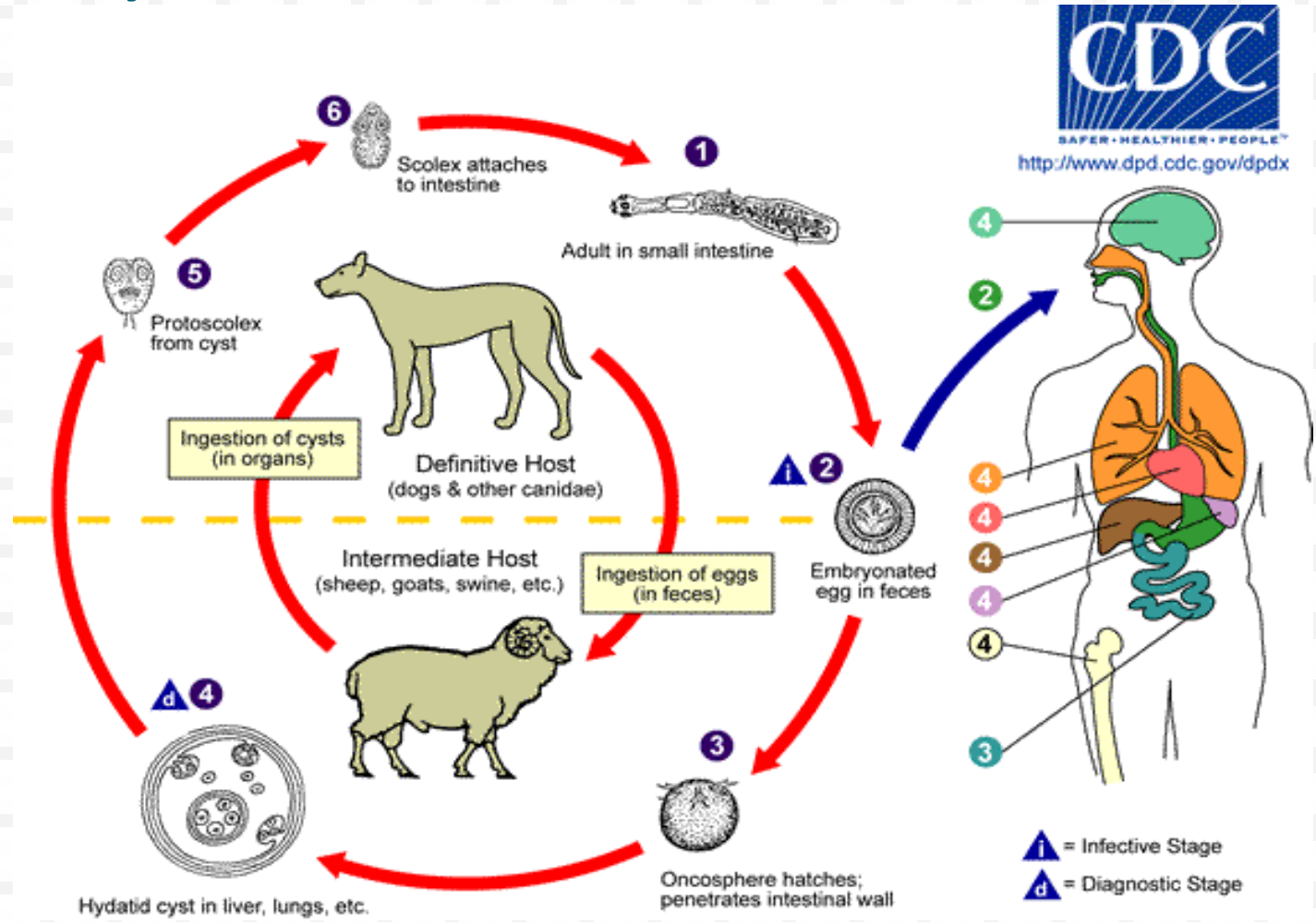


Hydatid sand

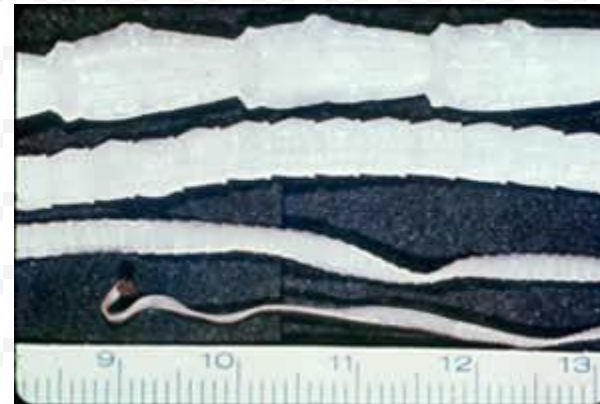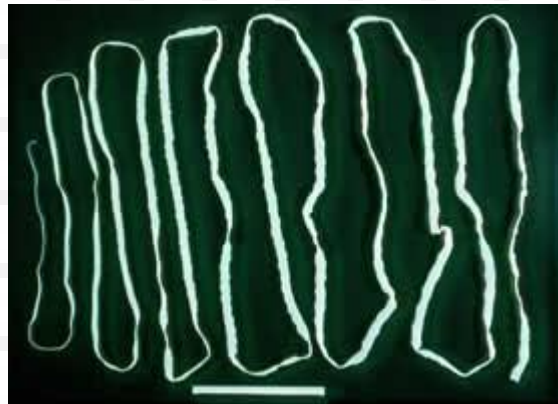
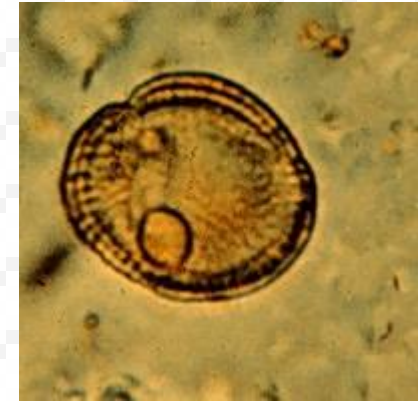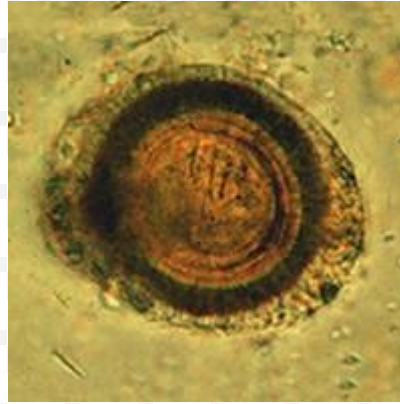


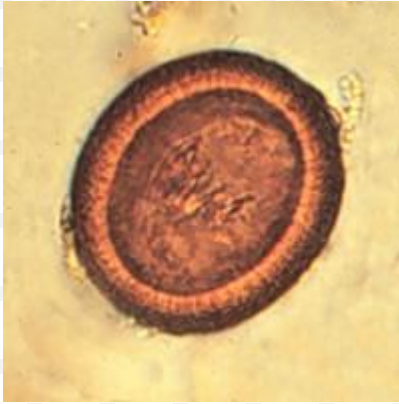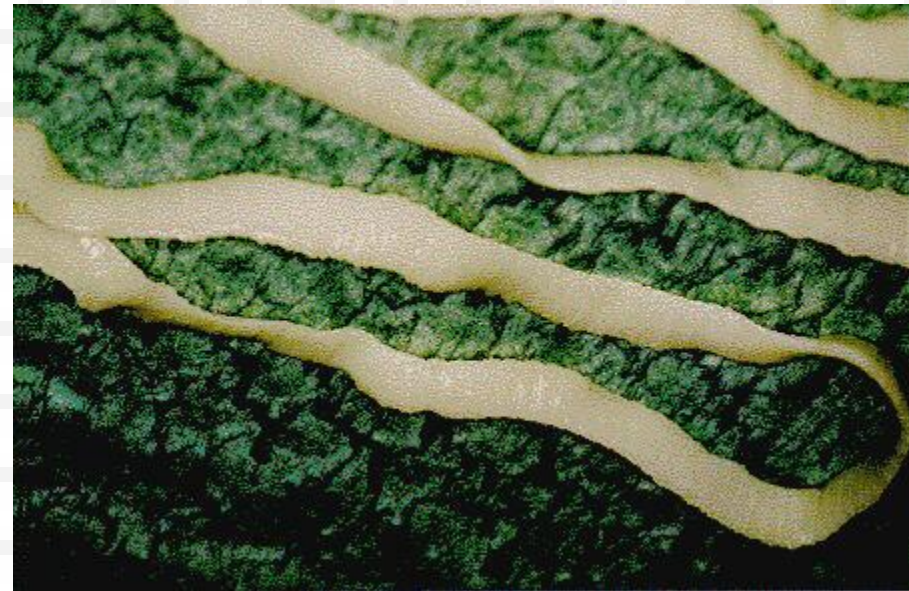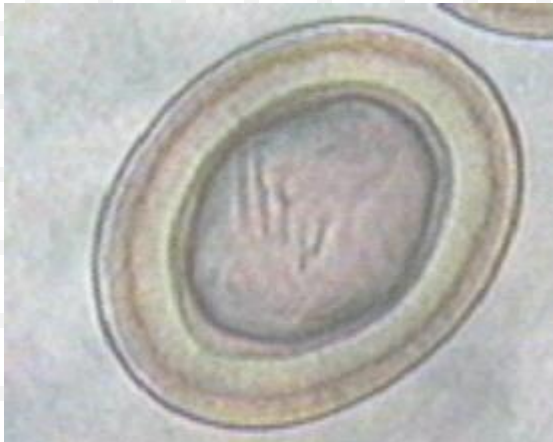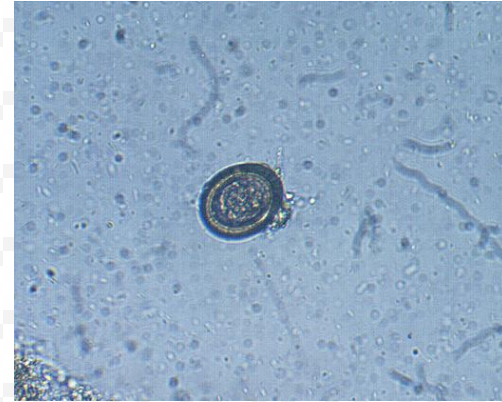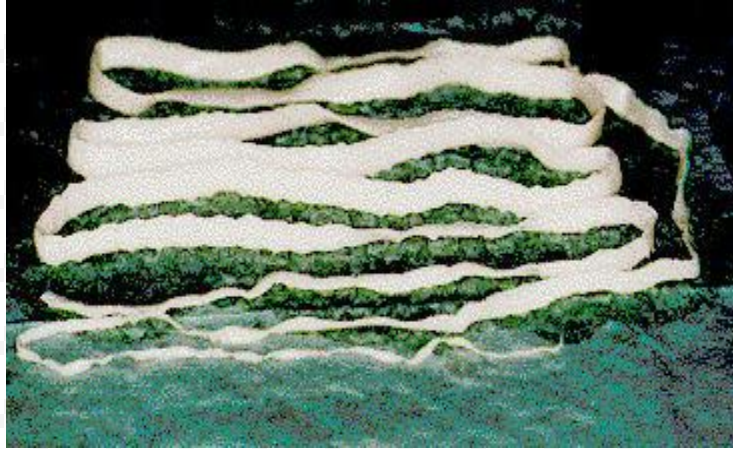


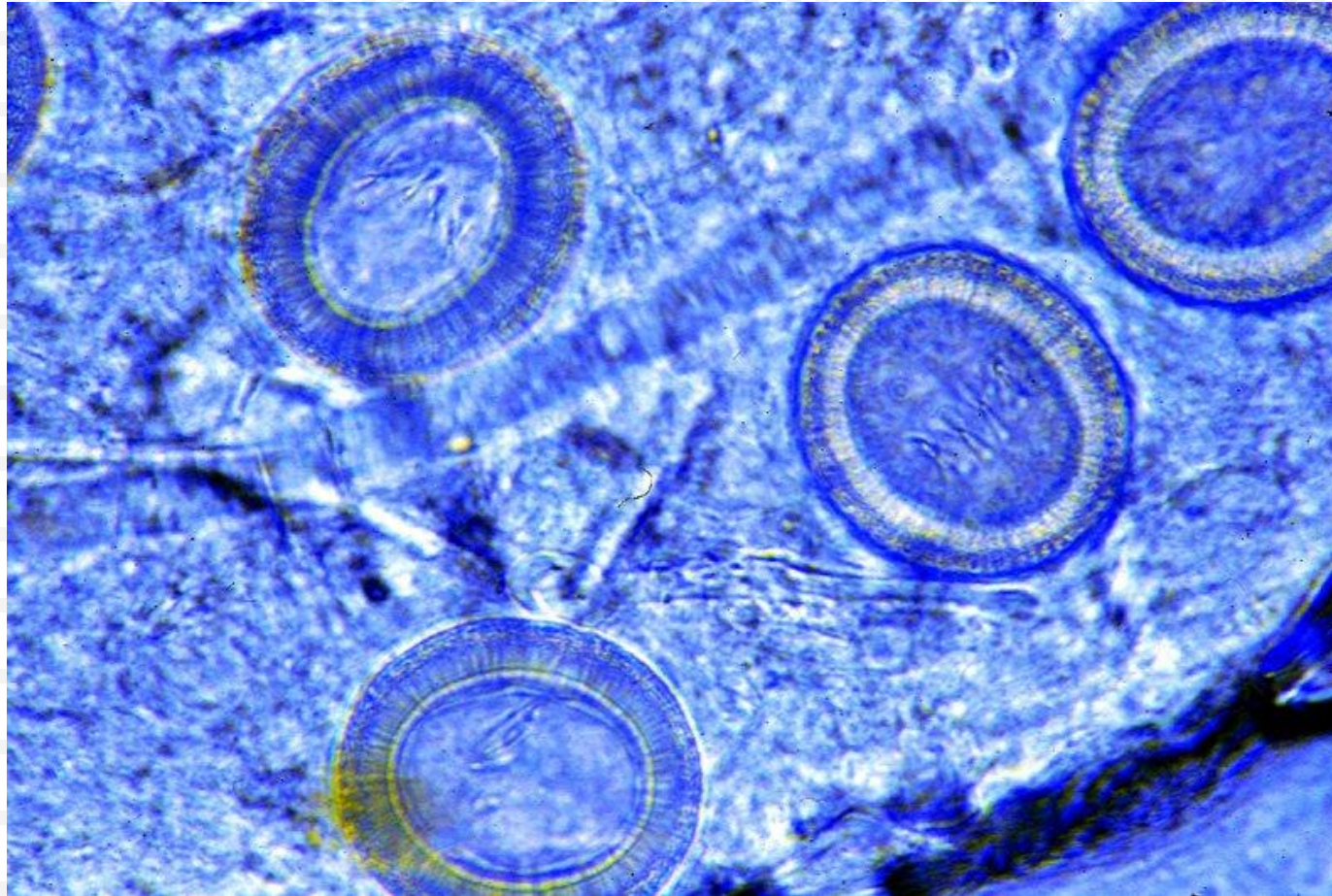
Life cycle of *Echinococcus*

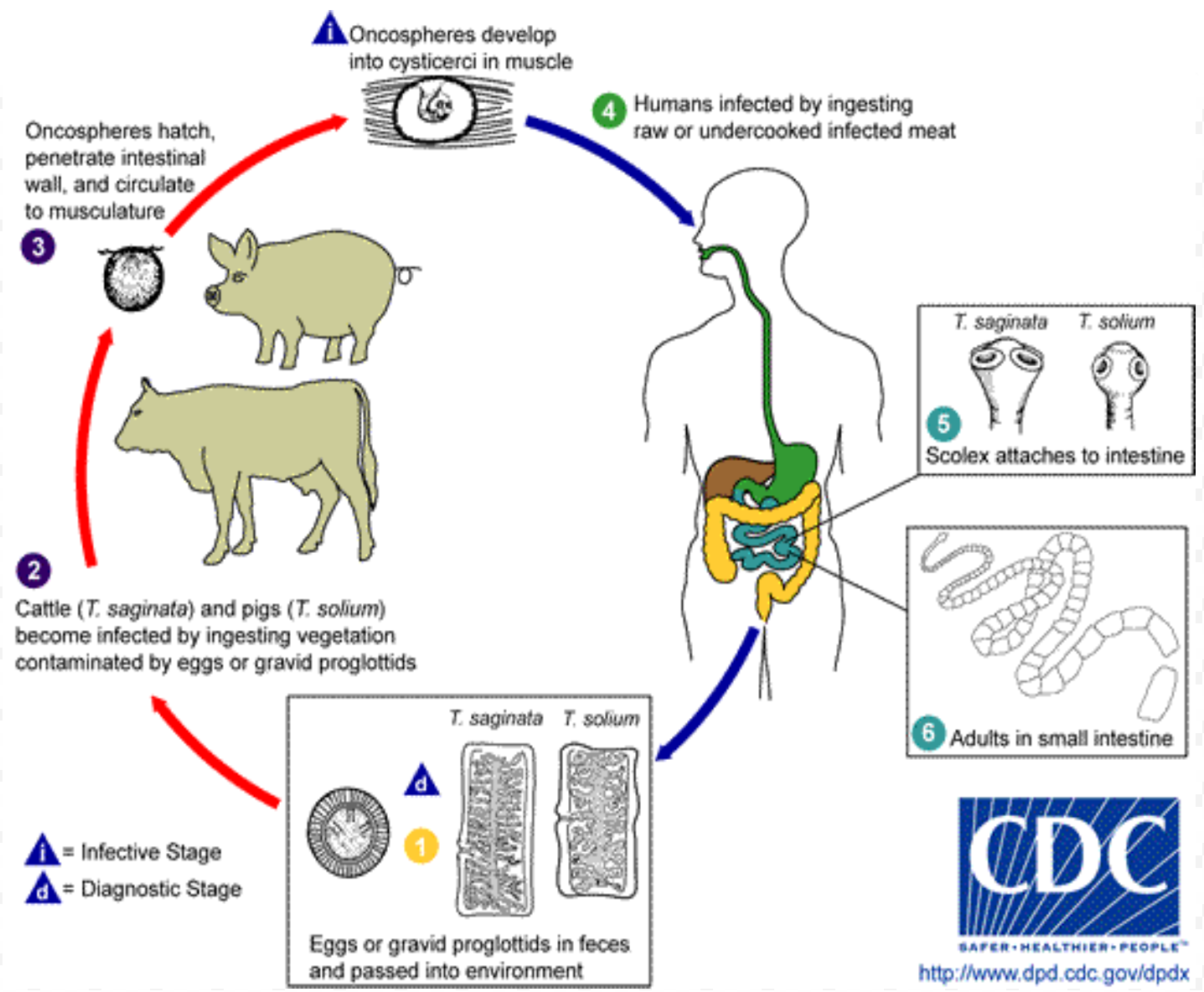


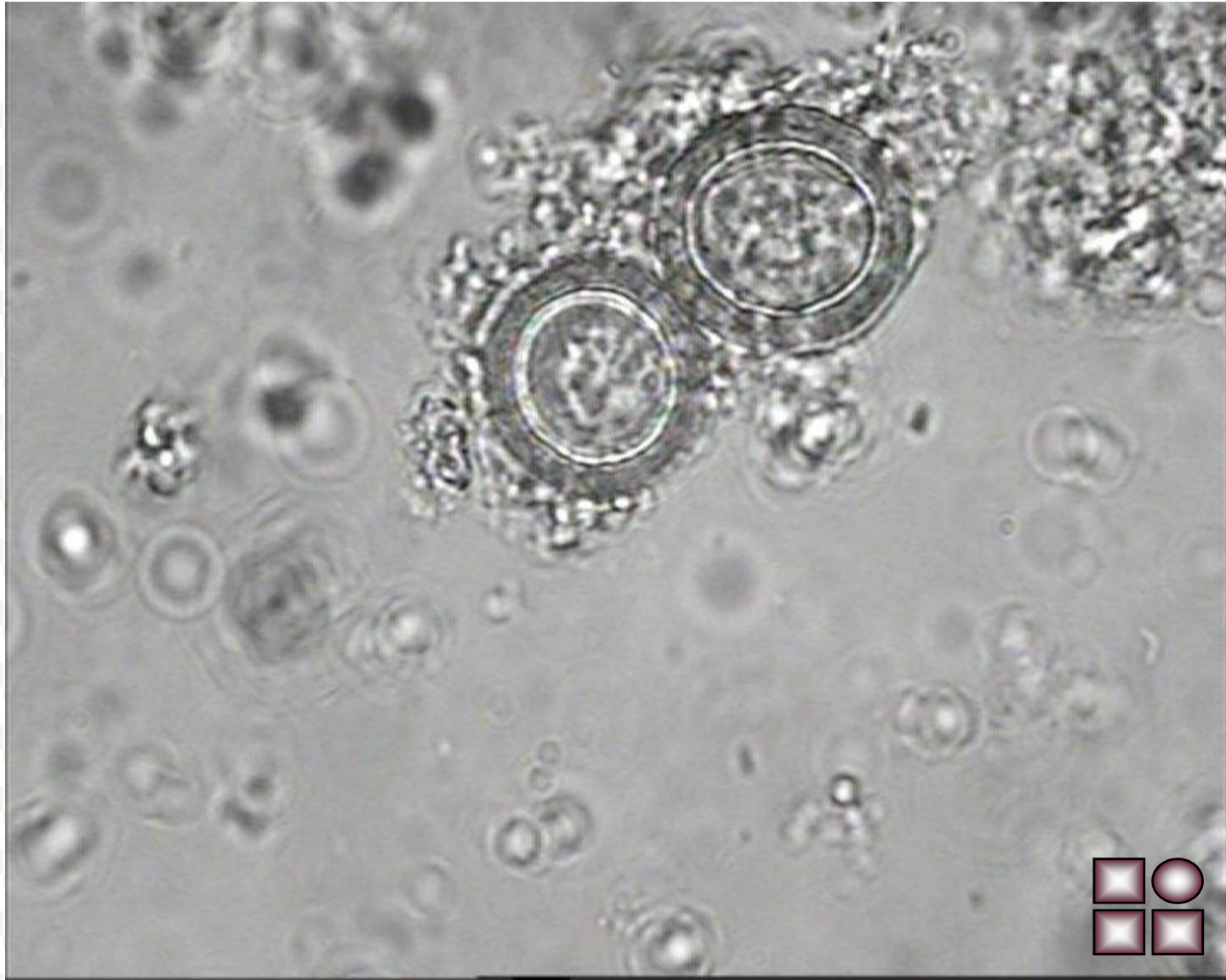Taenia saginata T. solium

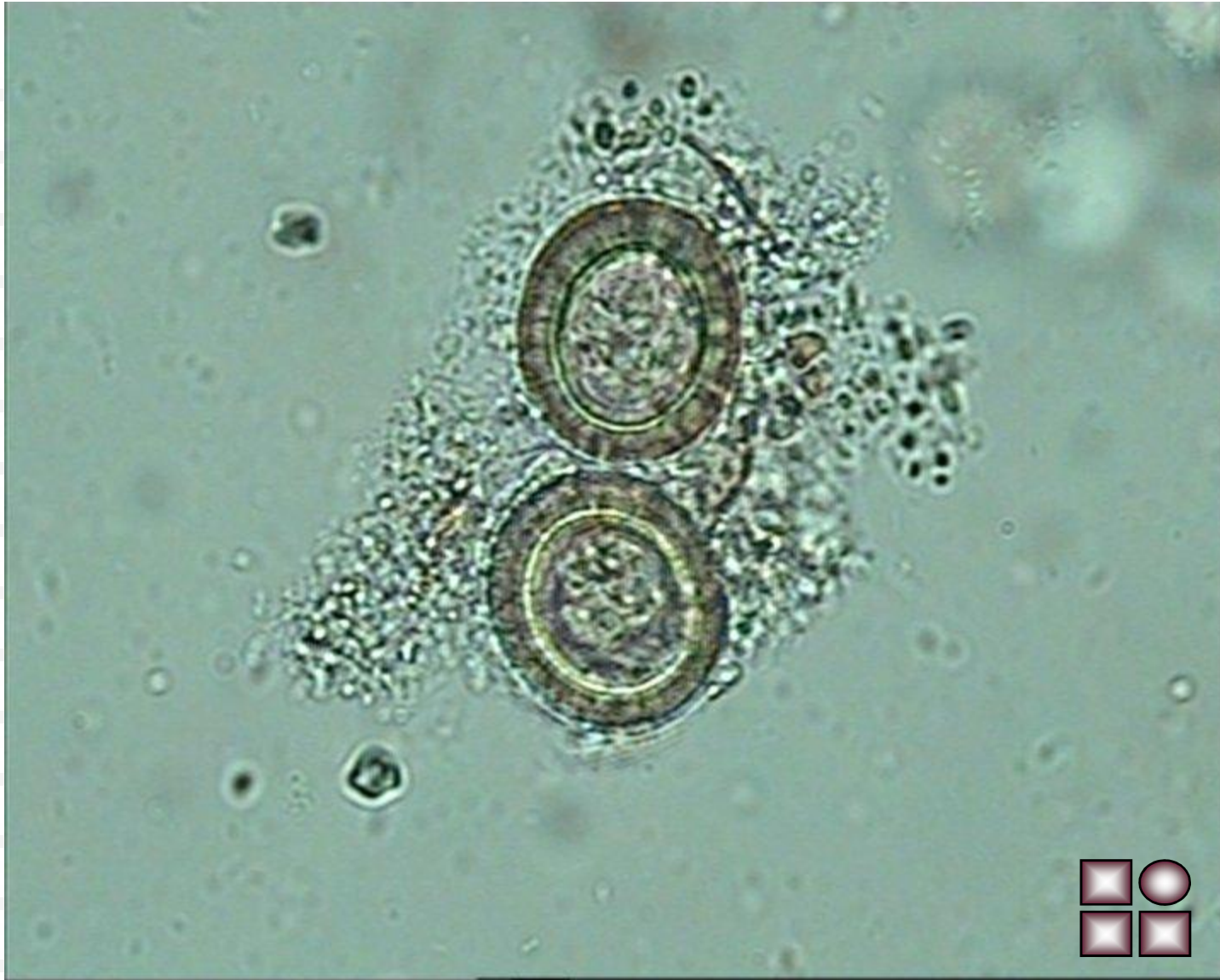






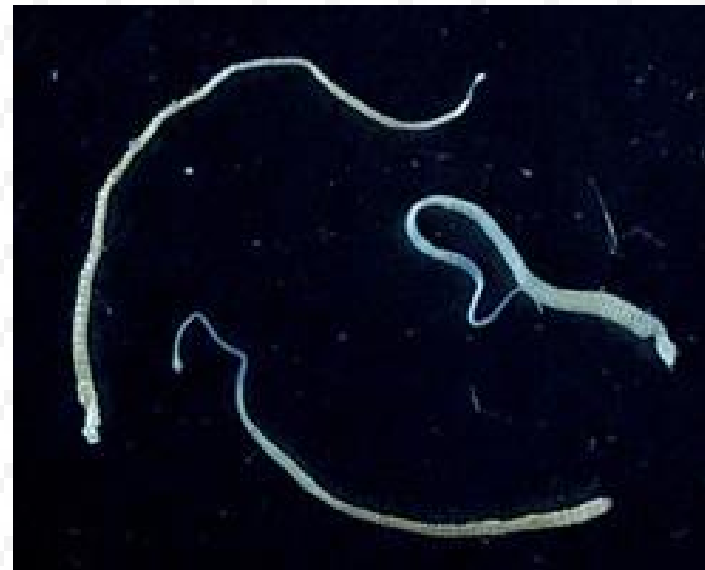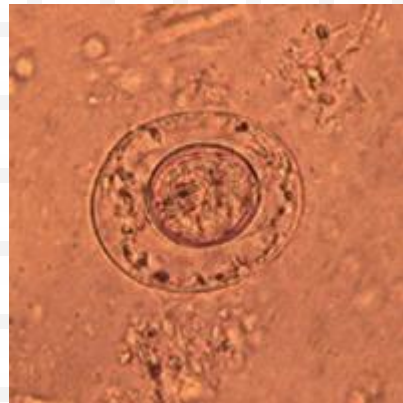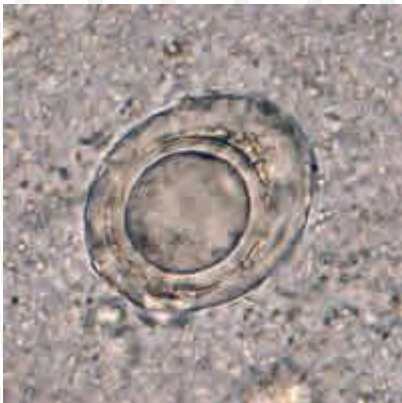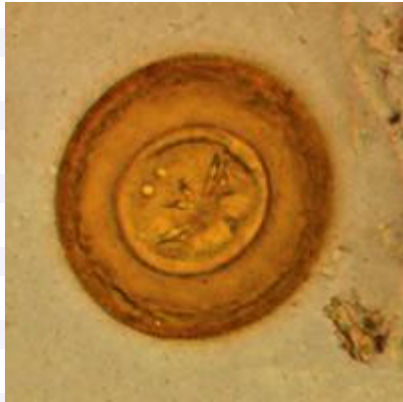








Hymenolepis nana





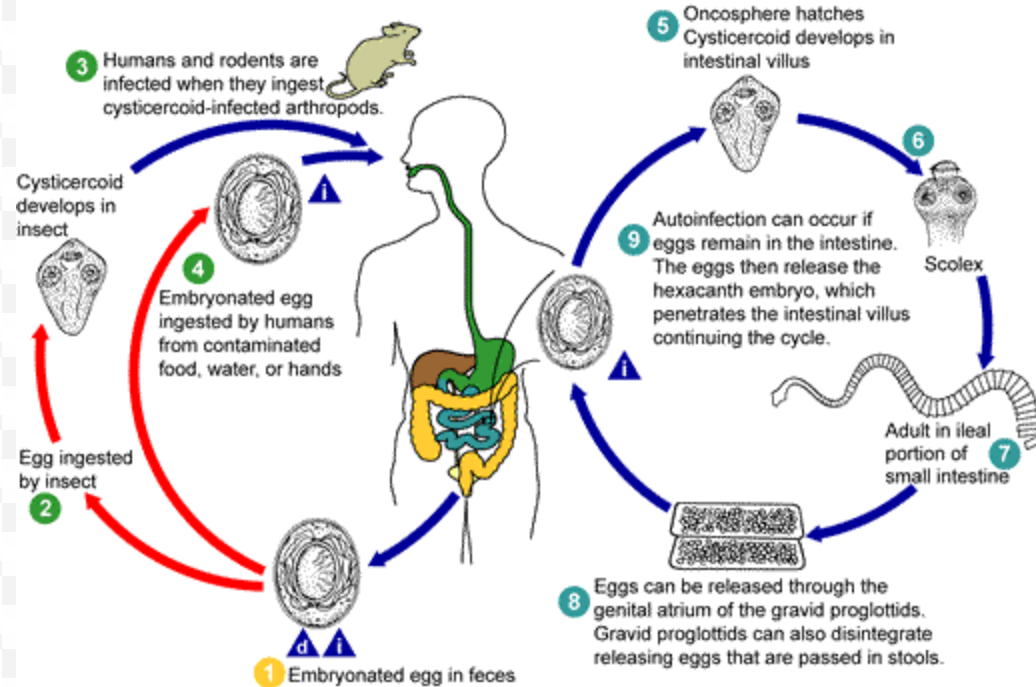
وزارت بهداشت، درمان و آموزش پزشکی

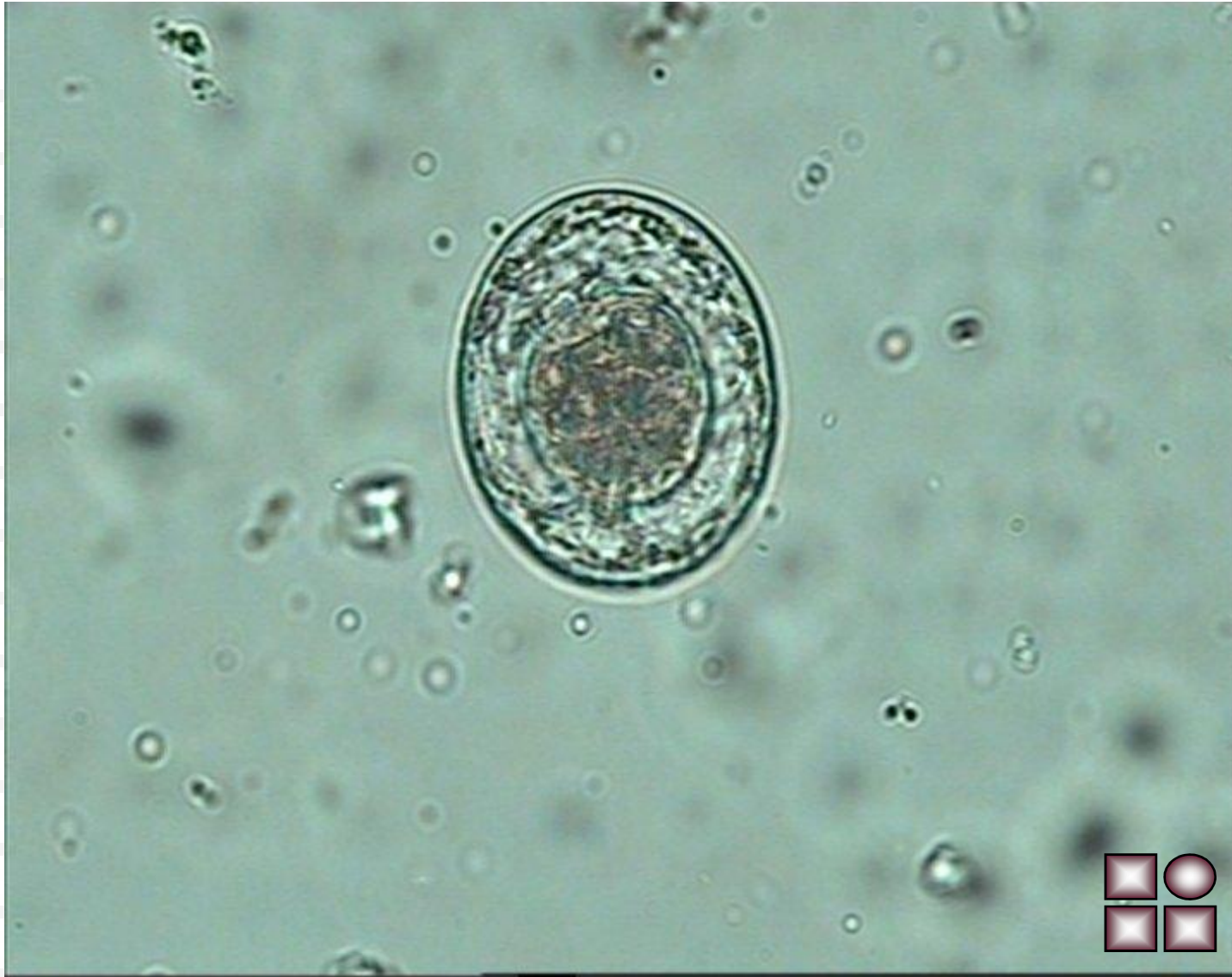
Life cycle of *Hymenolepis nana*

▲ = Infective Stage
△ = Diagnostic Stage

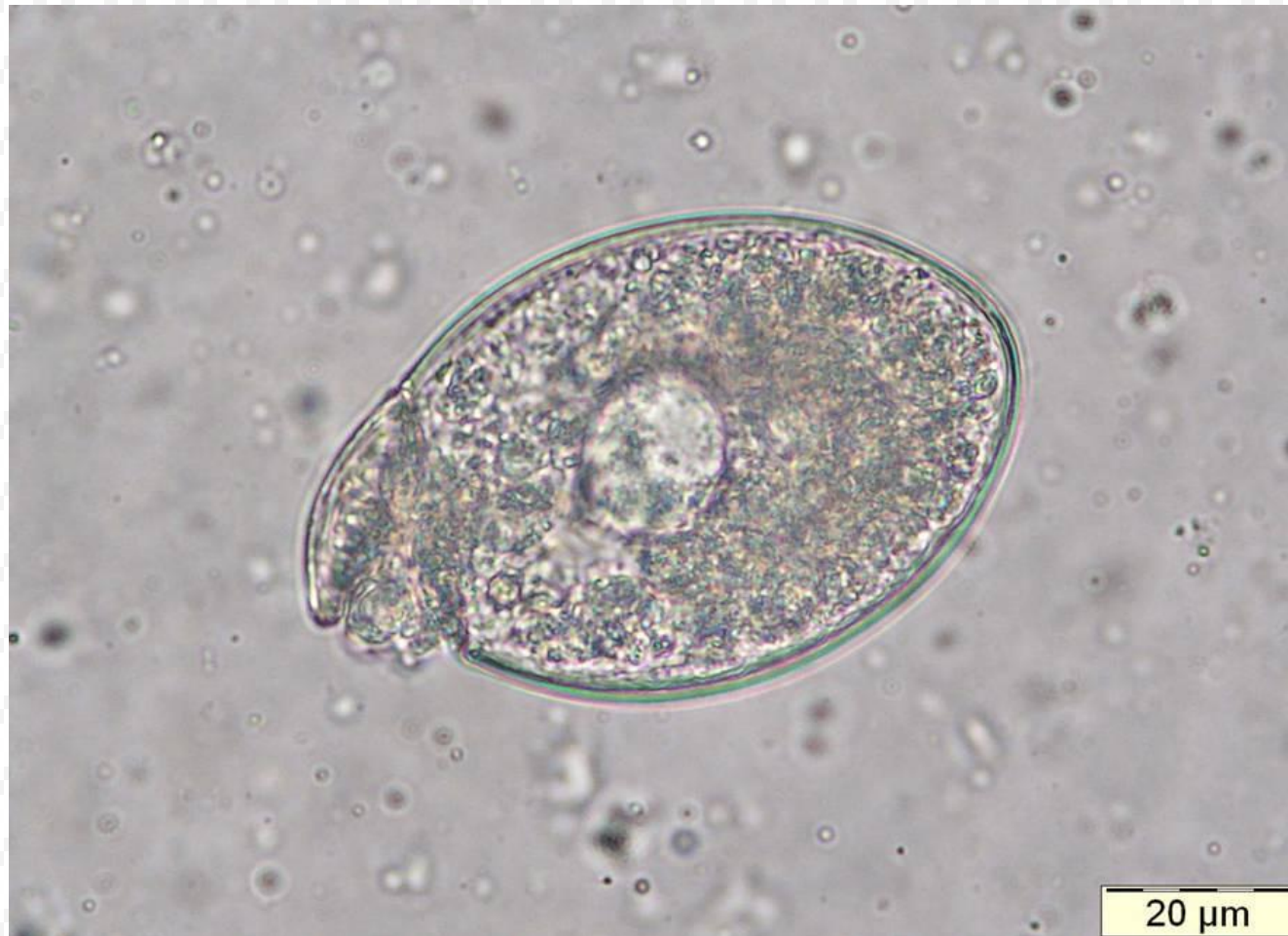

<http://www.dpd.cdc.gov/dpdx>





Diphyllobothrium latum egg

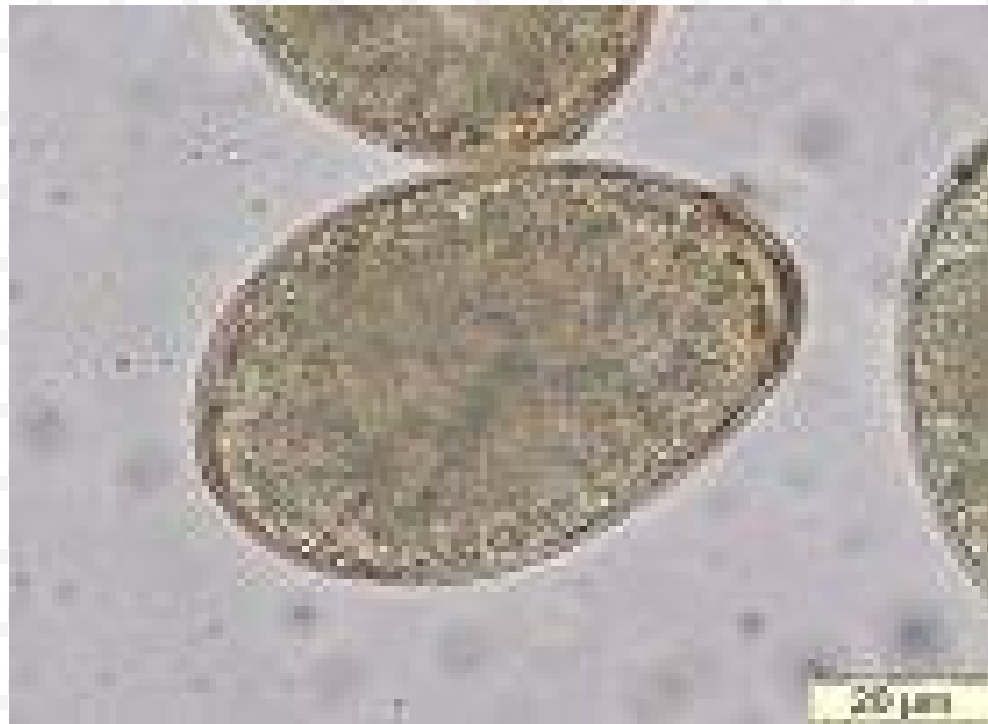




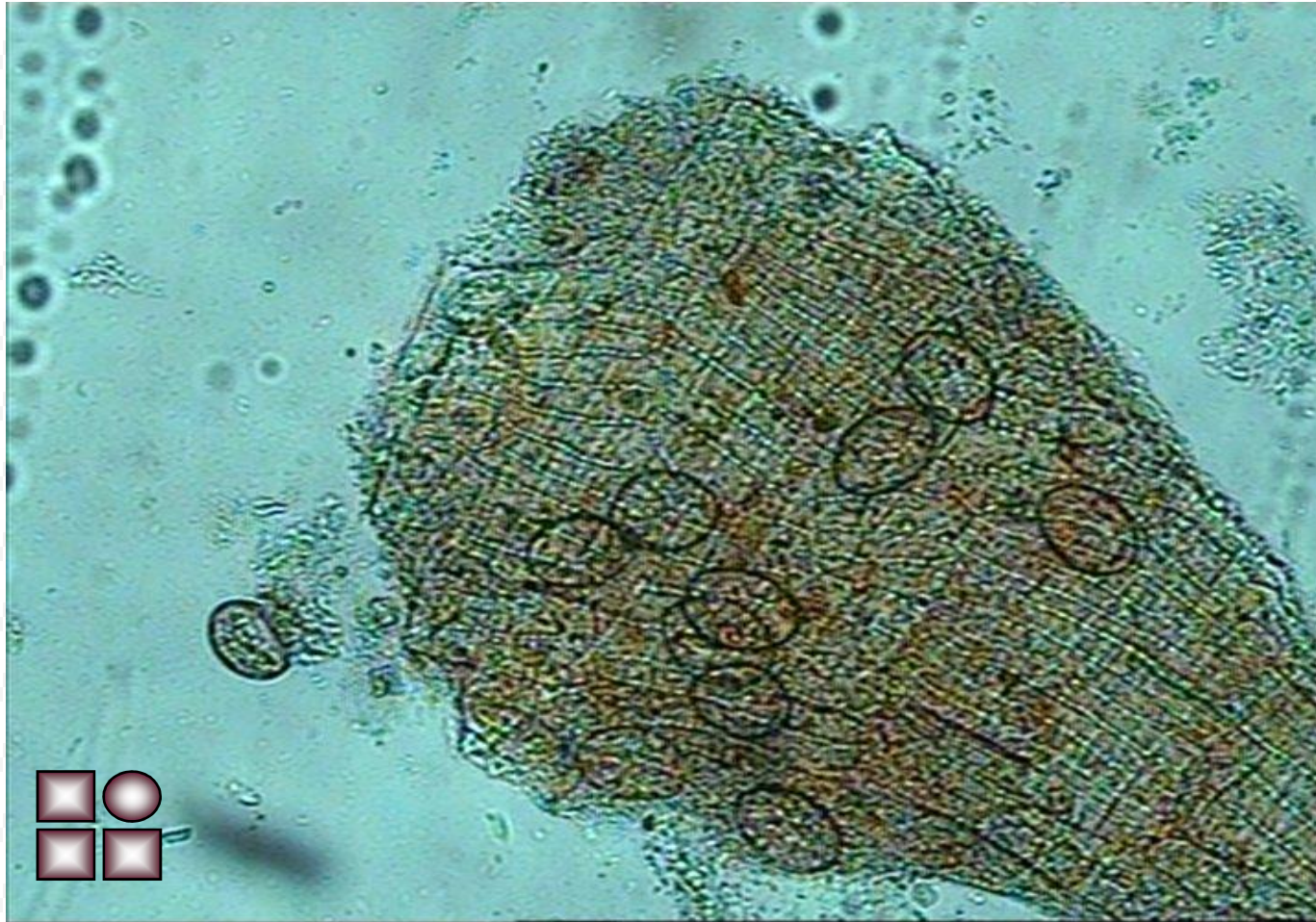
Diphyllobothrium latum Proglotid



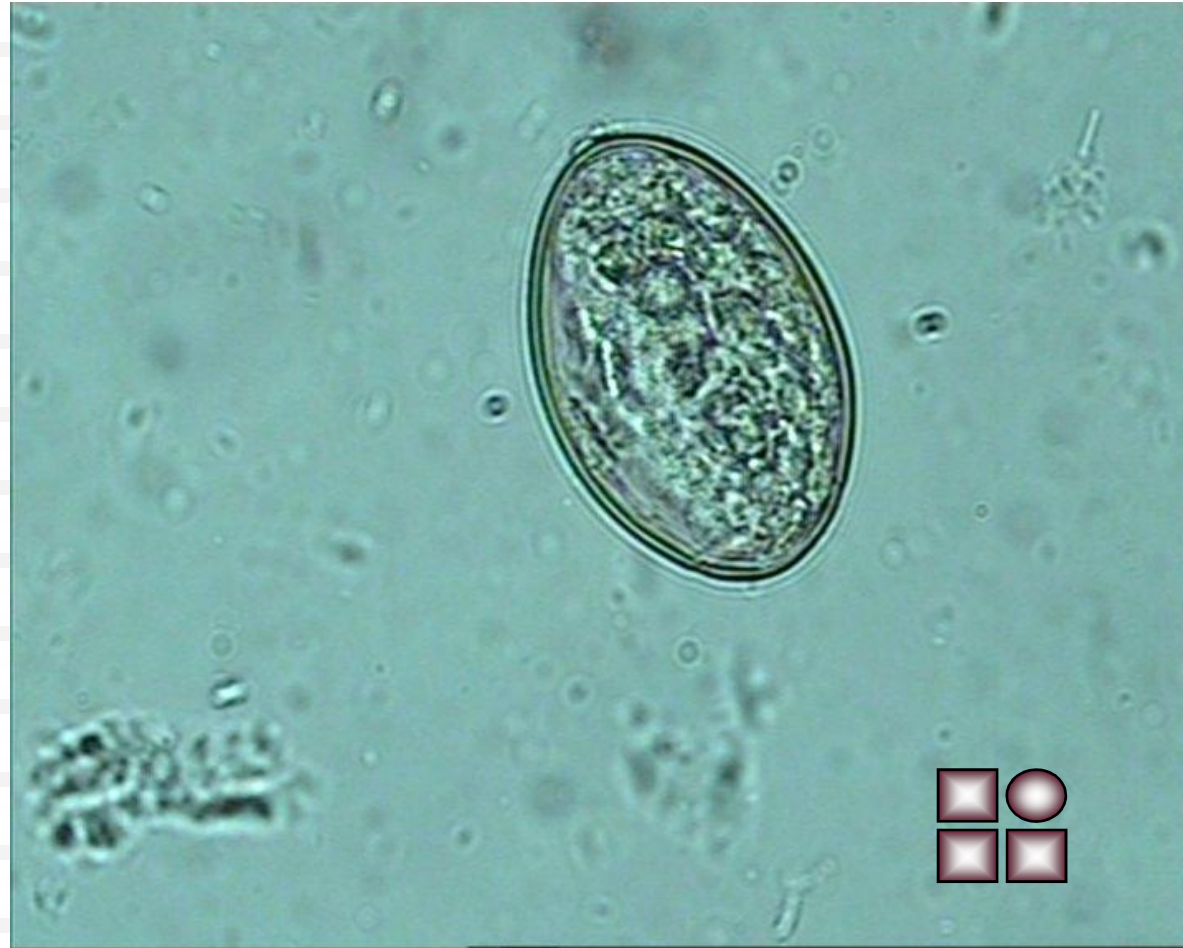
Diphyllobothrium latum egg



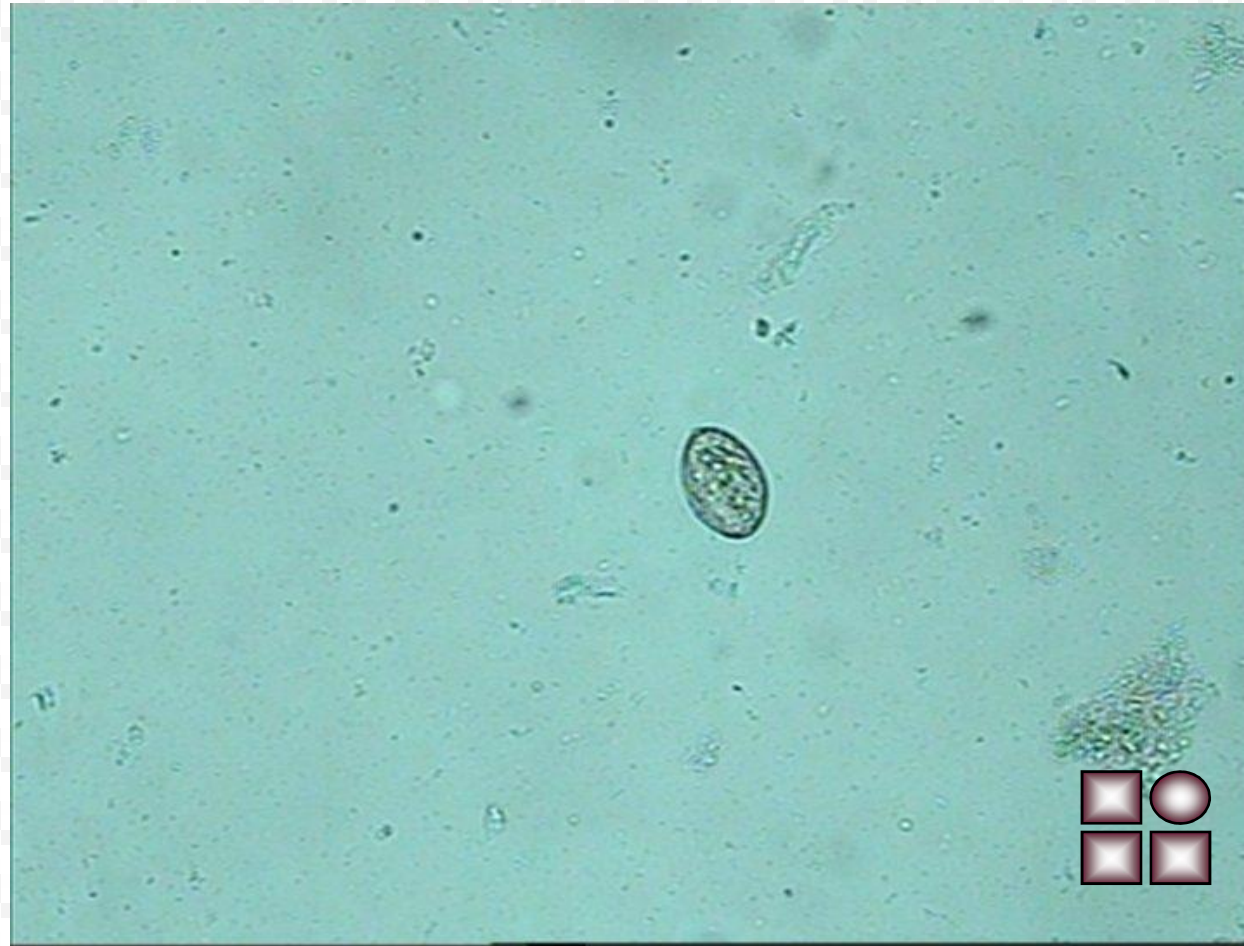Diphyllobothrium latum egg



Diphyllobothrium latum egg



Diphyllobothrium latum egg



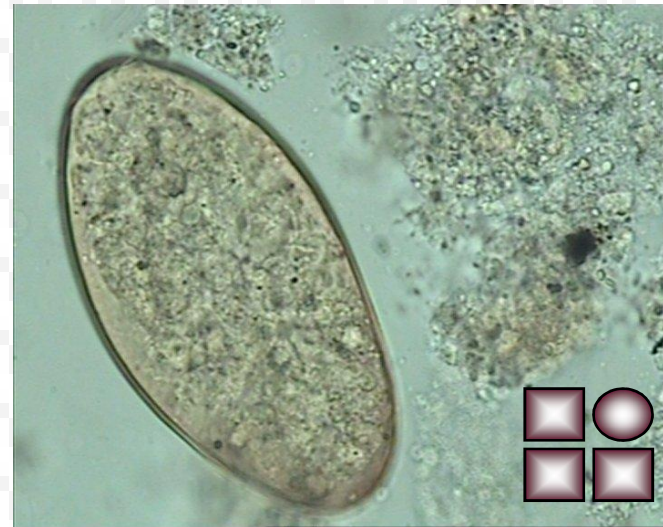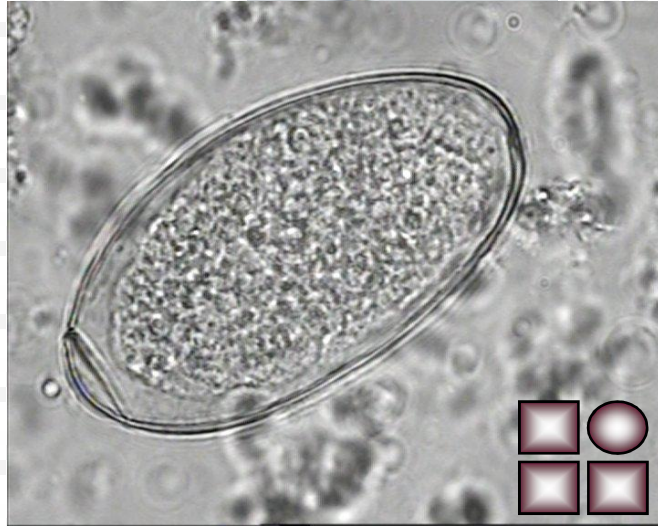
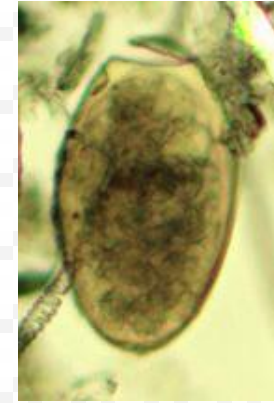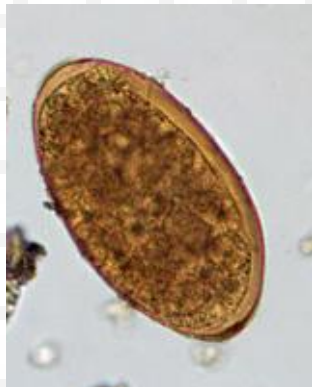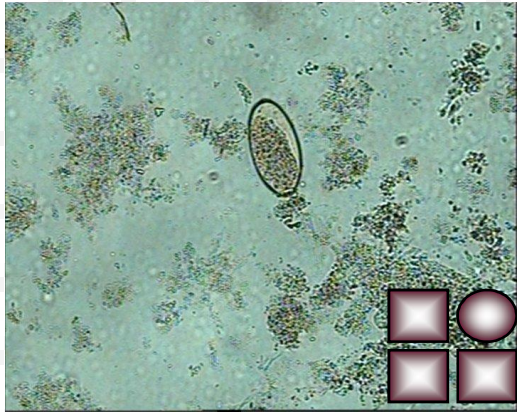


کرمهای پهن یا فلوک های روده ای انسان

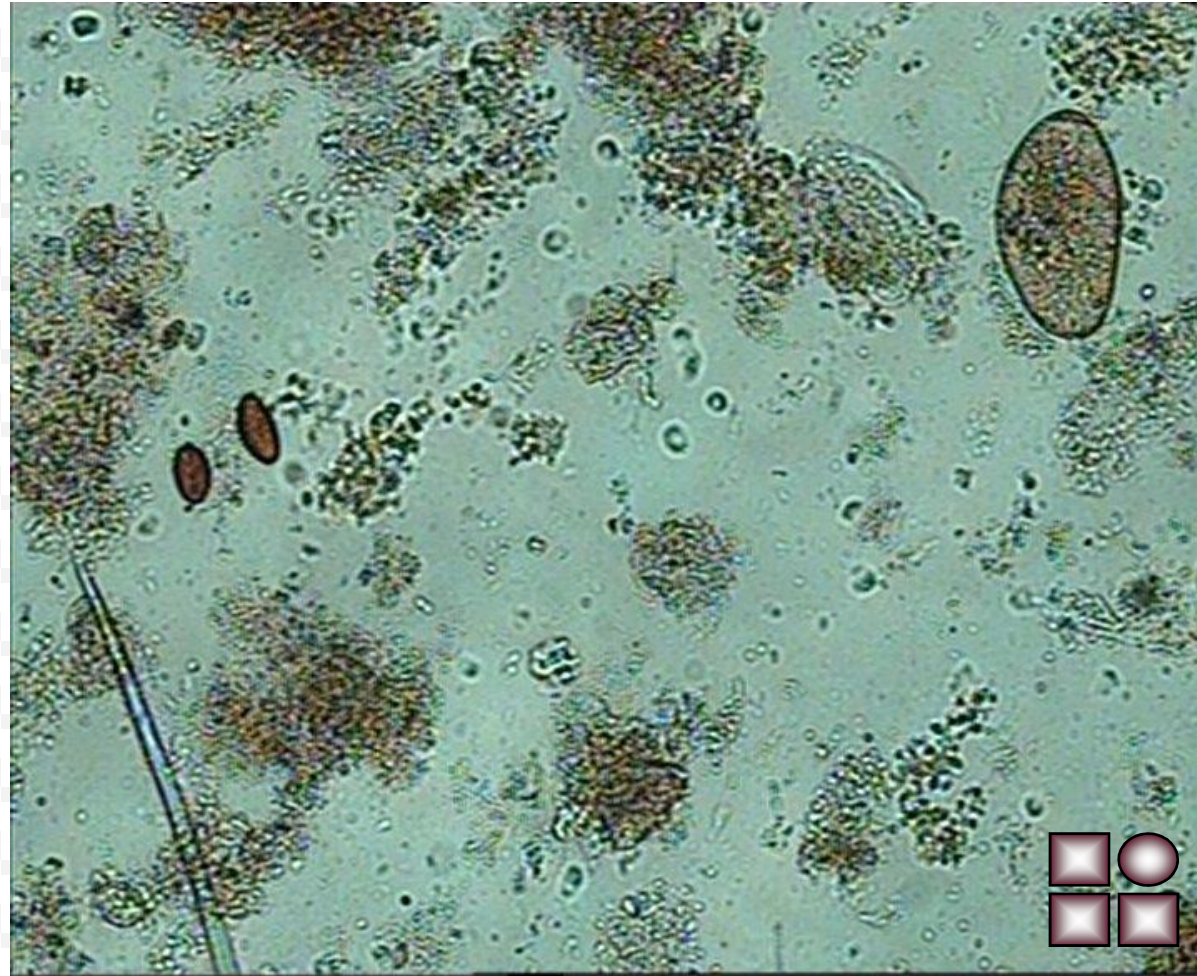فاسیولا هپاتیکا = کرم کبدگوسفند = کیلی
دیگروسولیوم دندریتیوم



Fasciola hepatica eggs

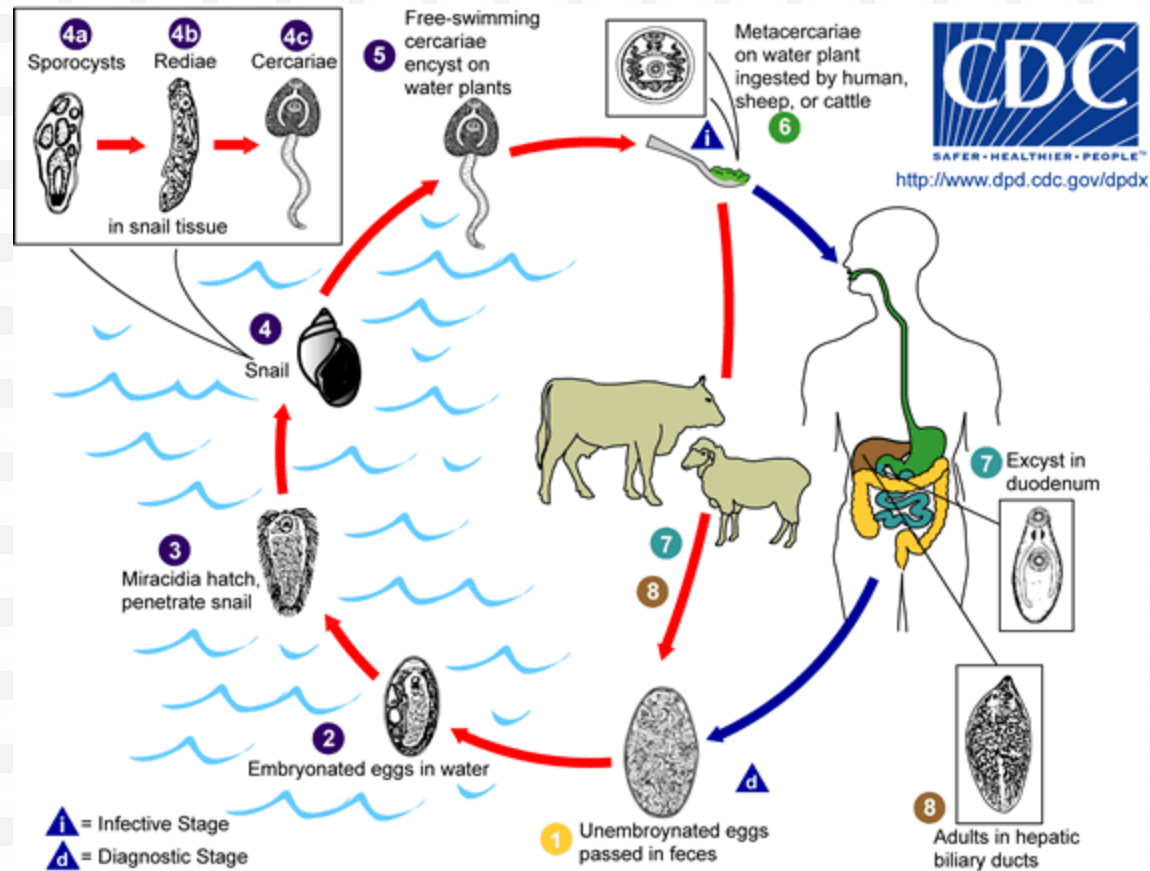


Fasciola hepatica & *Dicrosolium dendriticum* egg

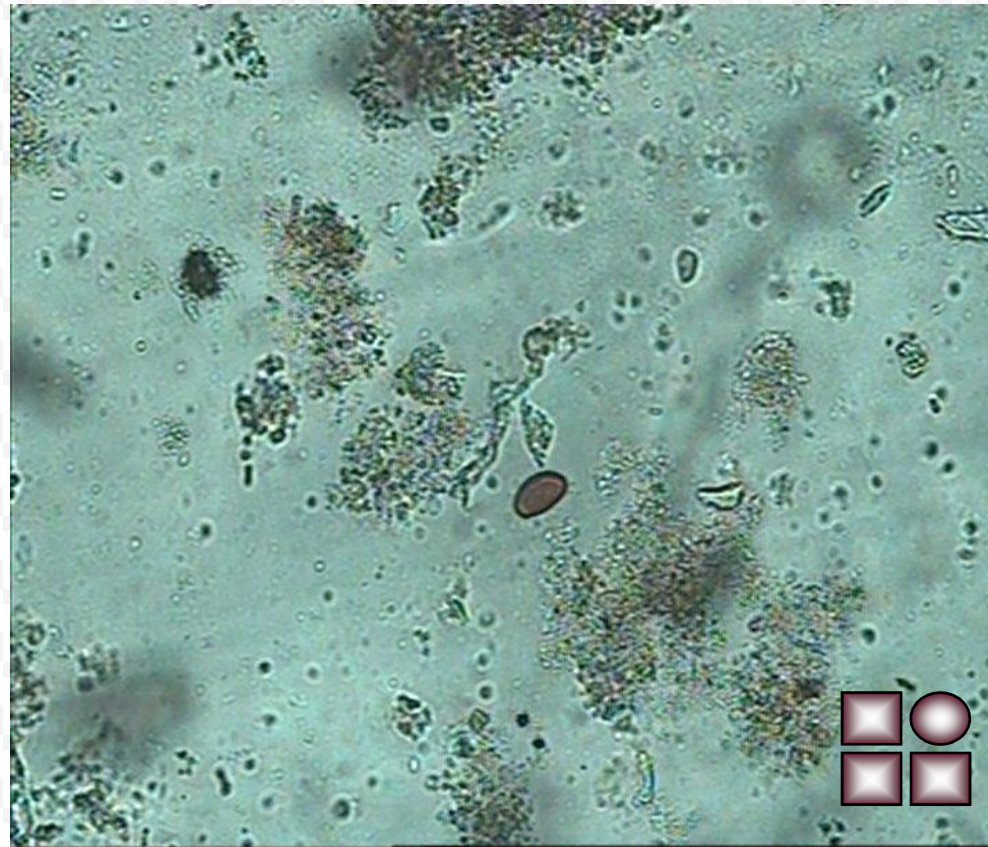



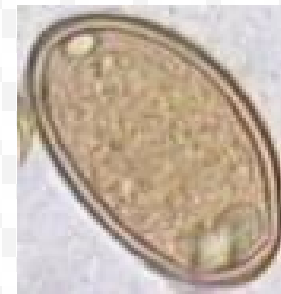
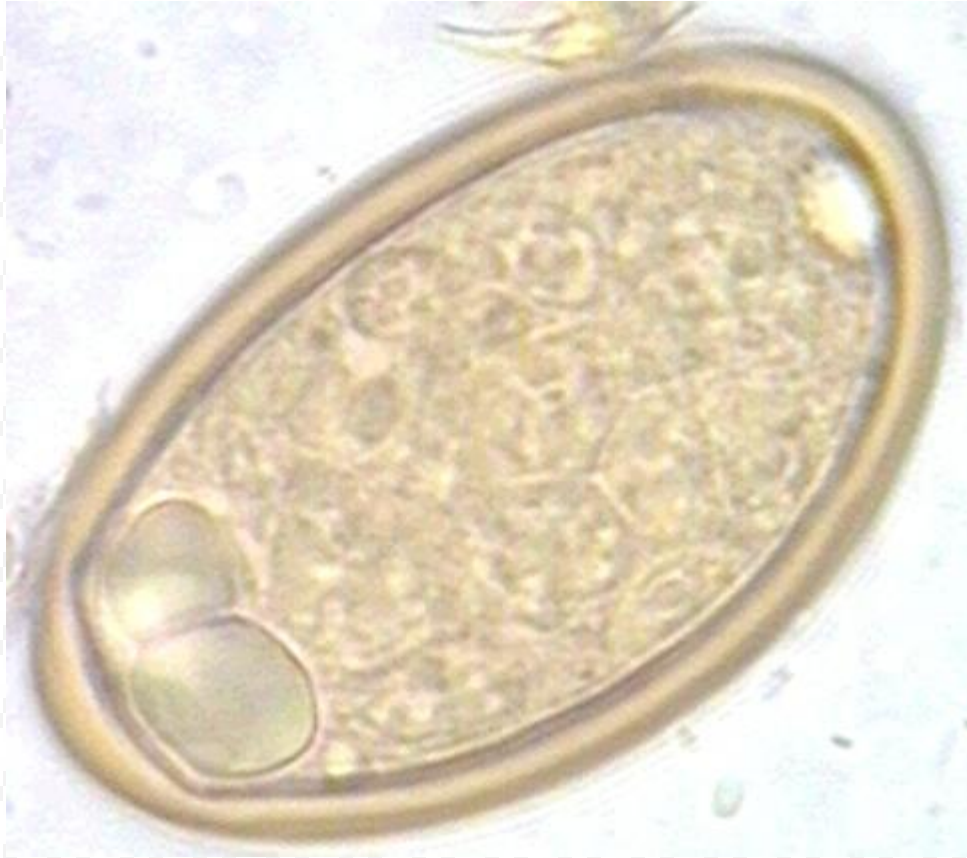Life cycle of *Fasciola hepatica*




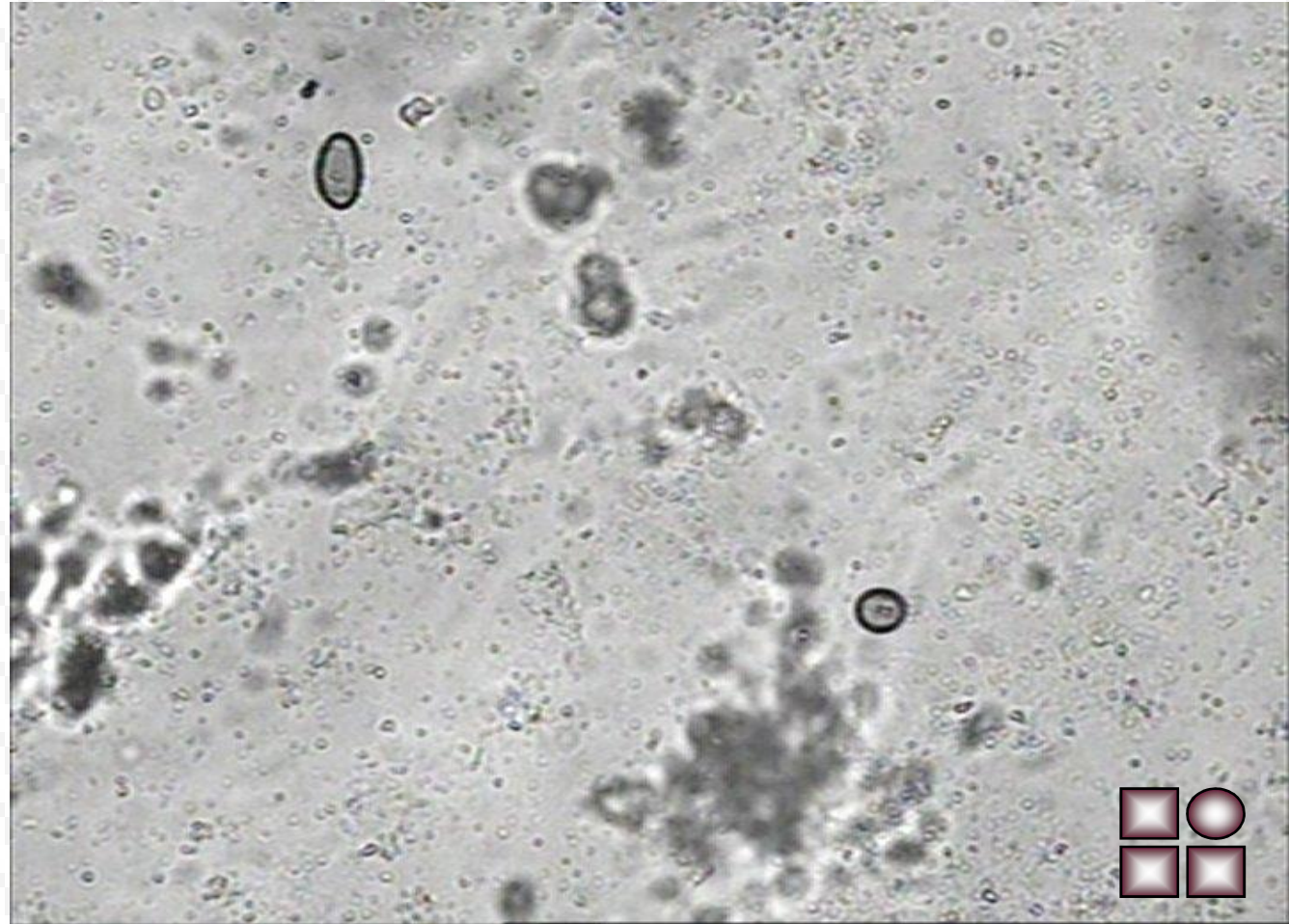
Dicrosolum dendriticum egg




Dicrosolium dendriticum egg



Dicrosolium dendriticum egg





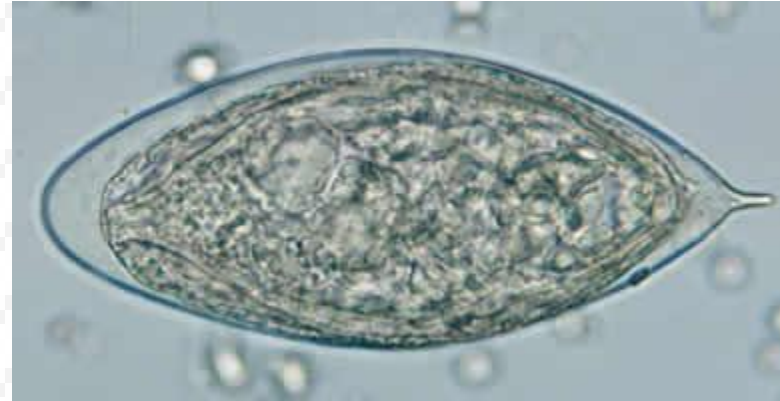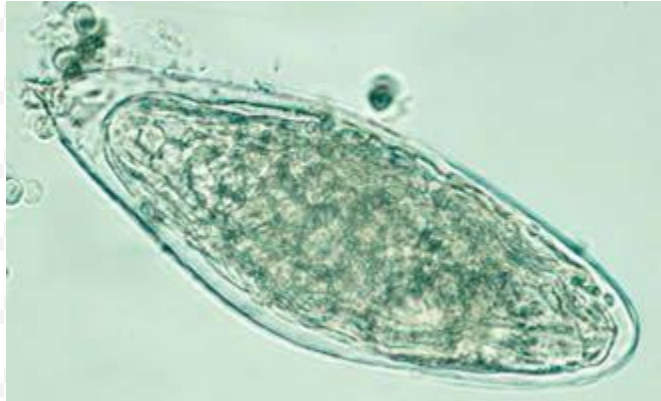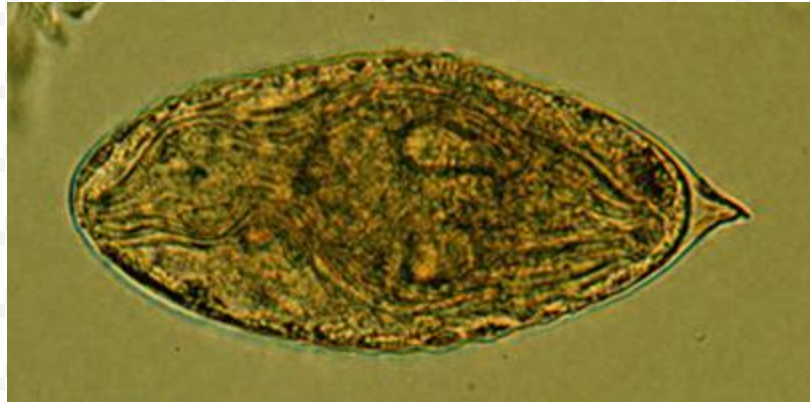
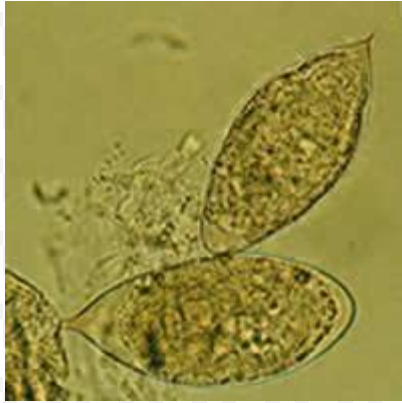گرمهای پن یافلوك هاي خوني انسان

شيستوزوما هماتوبیوم

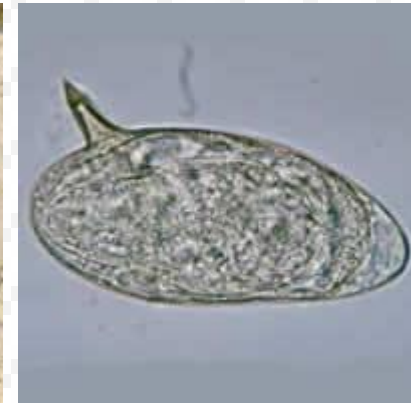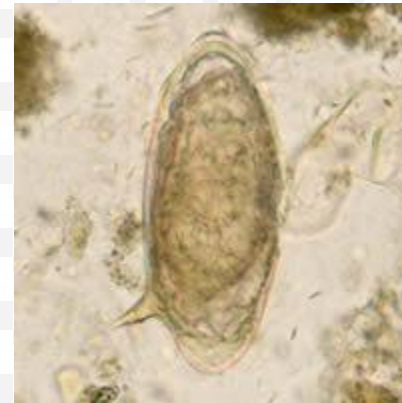
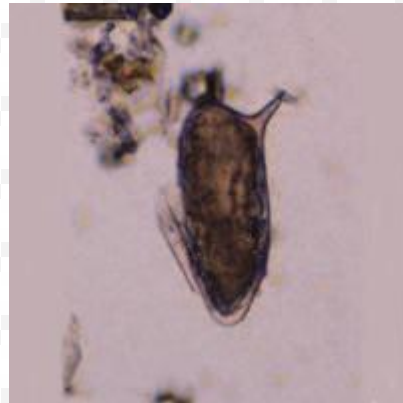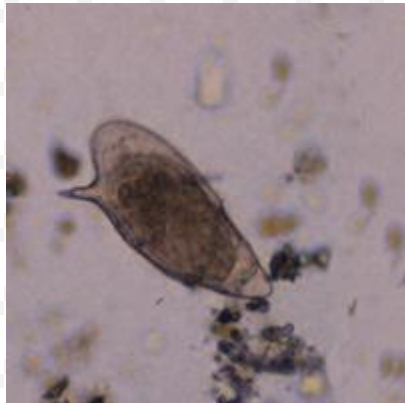
شيستوزوما مانسوني

شيستوزوما ژاپونيكوم

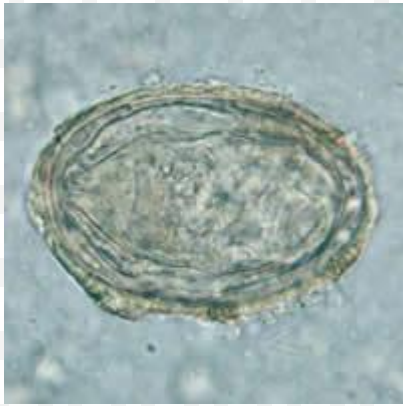
Schistosoma haematobium eggs



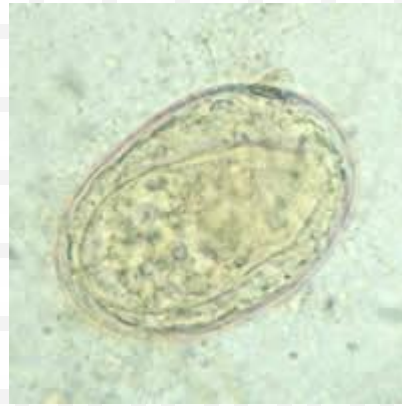Schistosoma mansoni eggs



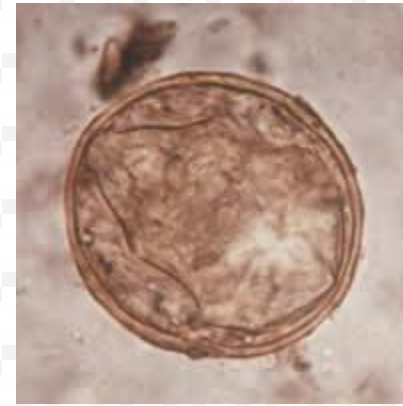
Schistosoma japonicum eggs



A



B



C

shows a visible spine The egg in Figure C

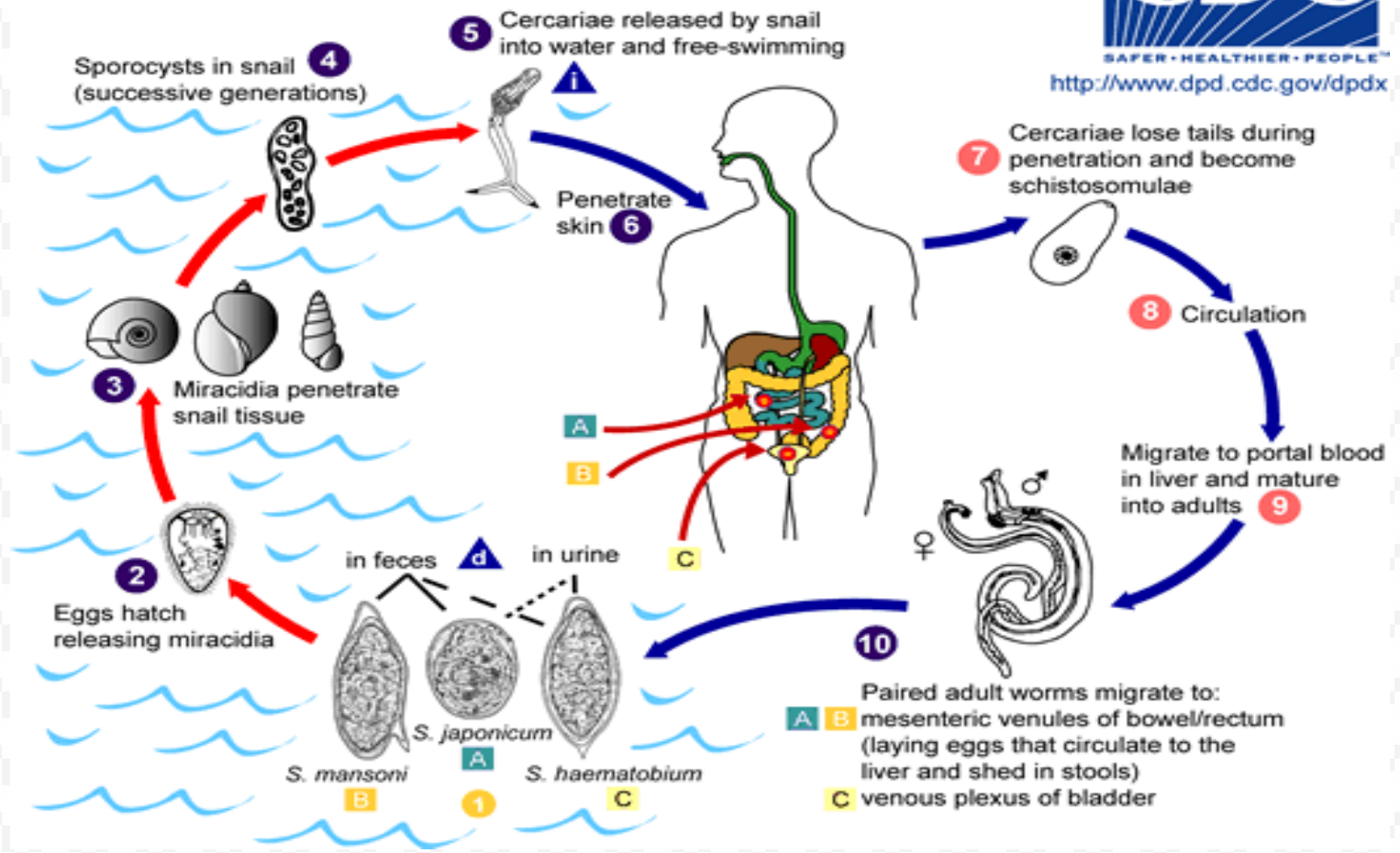



Life

i = Infective Stage
d = Diagnostic Stage



<http://www.dpd.cdc.gov/dpdx>





آمیب های روده ای انسان

انتاموبا هیستولیتیکا / انتاموبا دیسپار

انتاموبا کلی

انتاموبا هارتمانی

اندولیماکس نانا

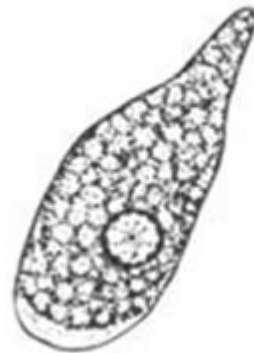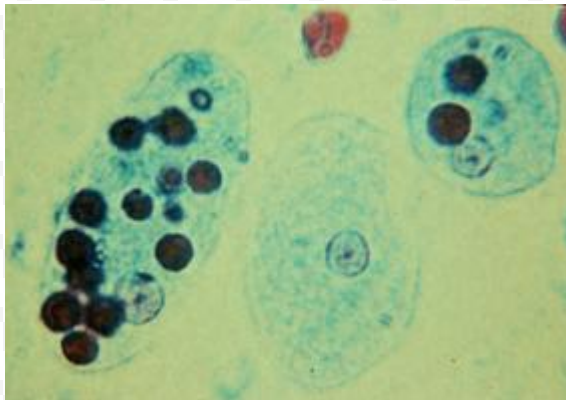
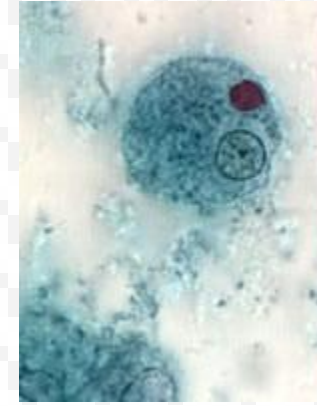
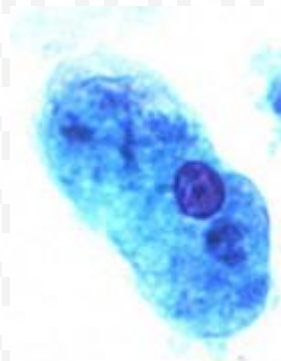
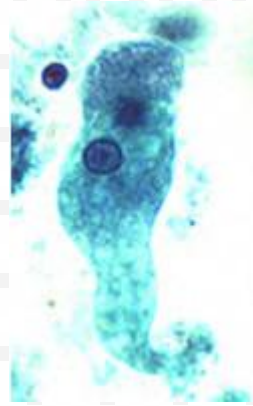
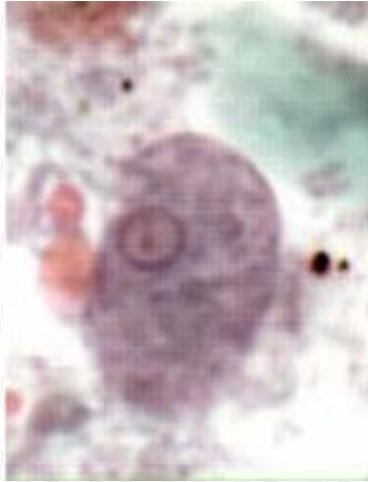
یداموبا بوتچلی

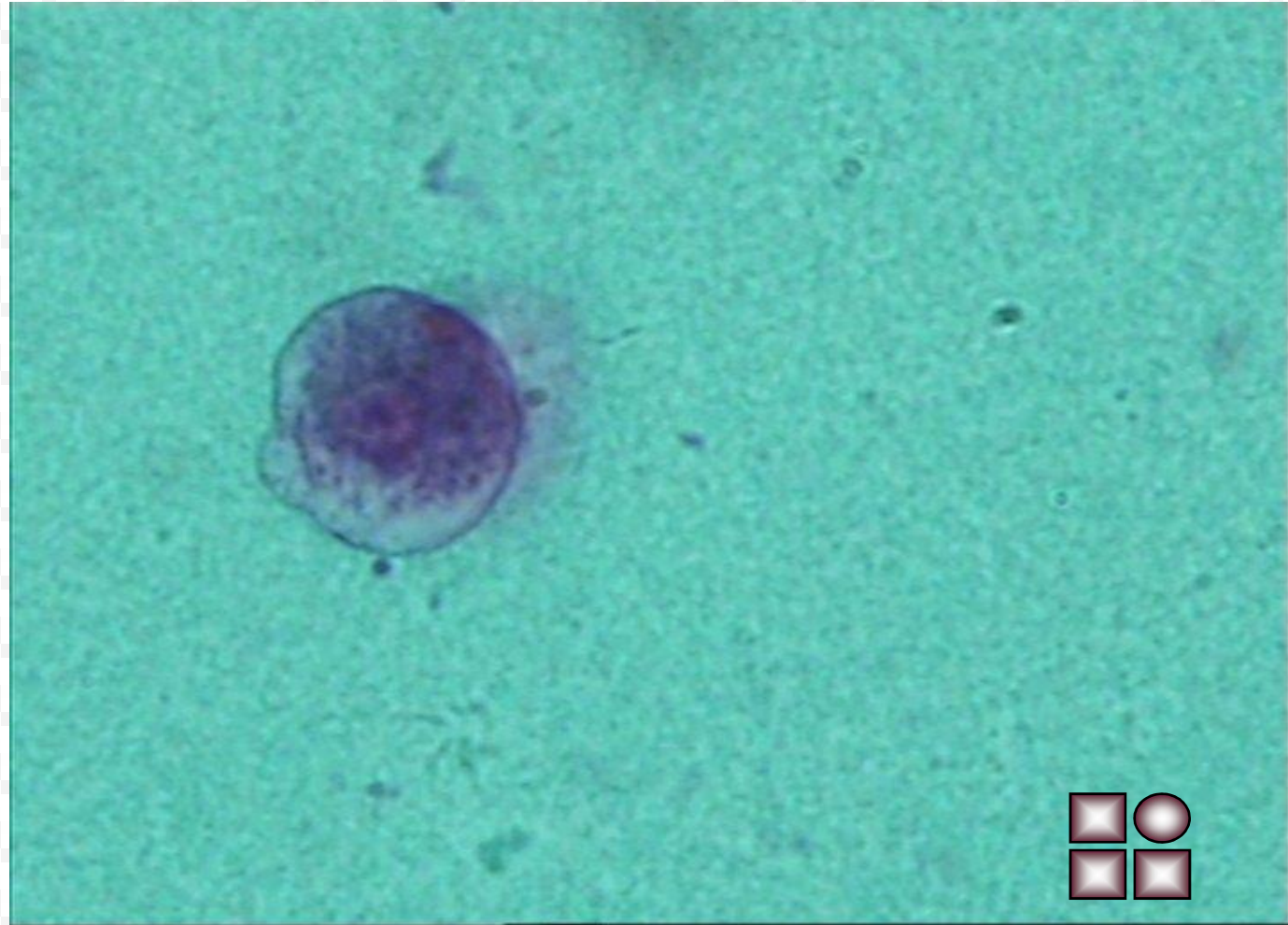
دانتاموبا فراجیلیس

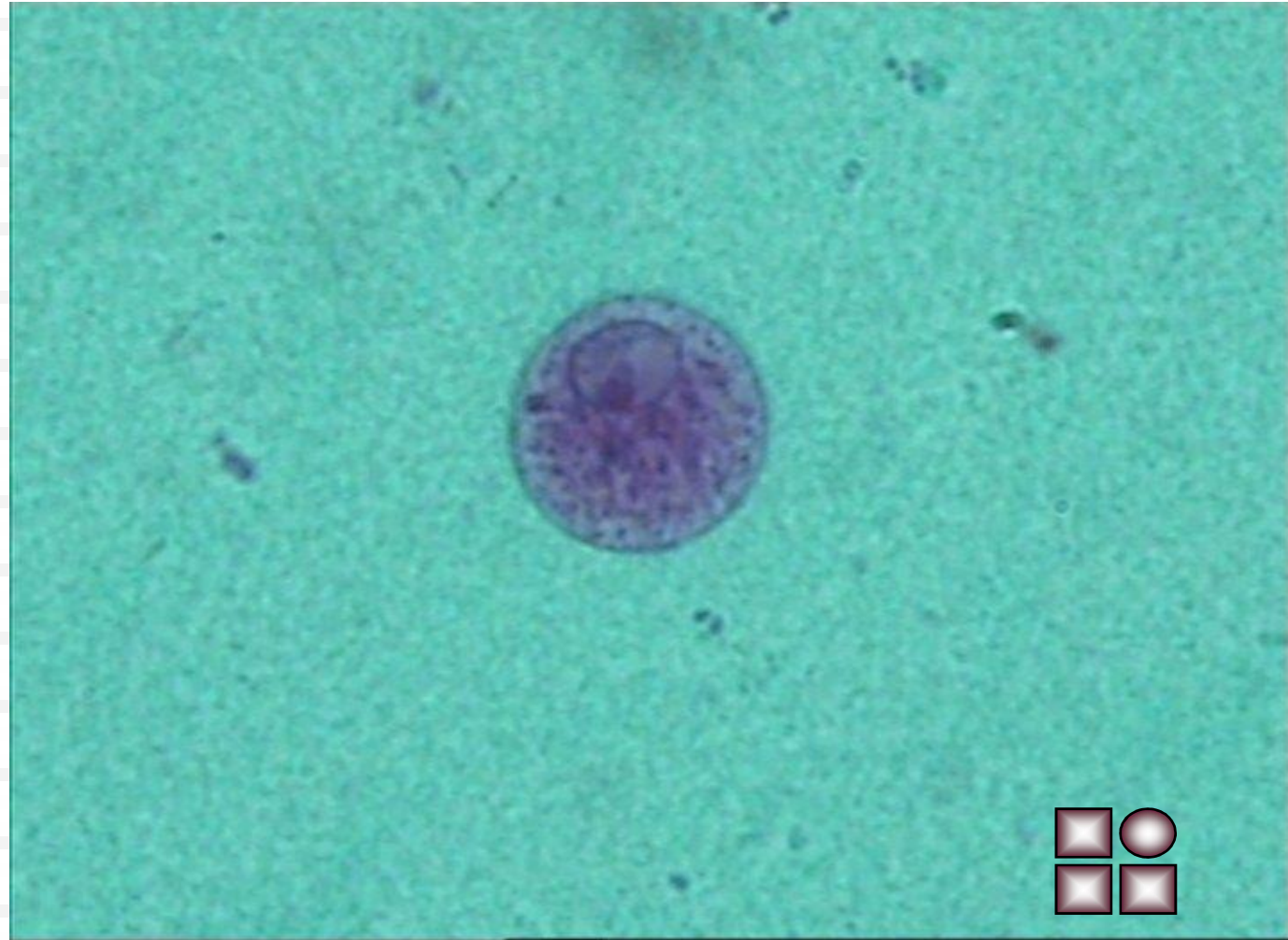


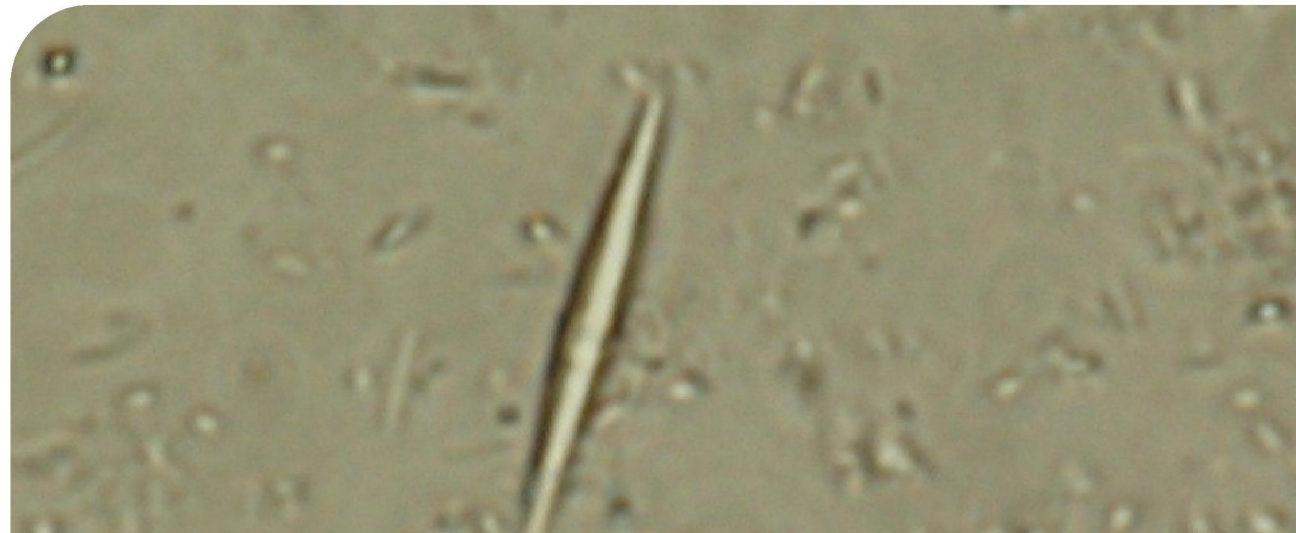Trophozoites of

Entamoeba histolytica/E. dispar





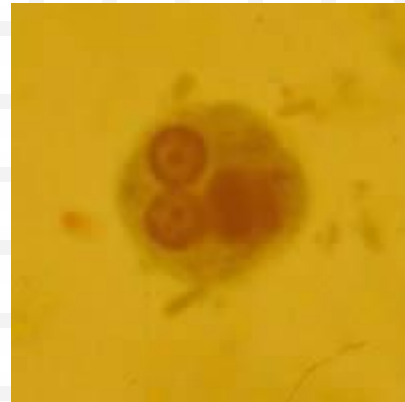
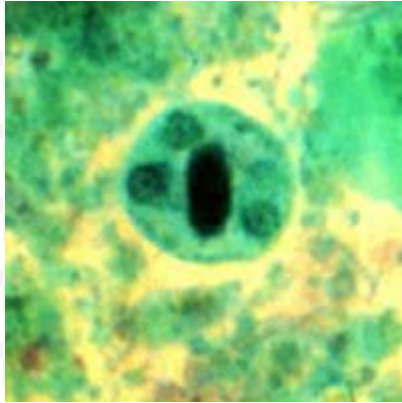
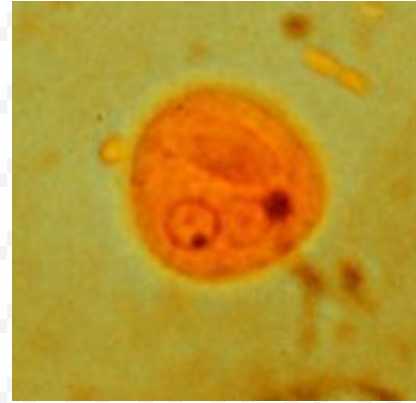
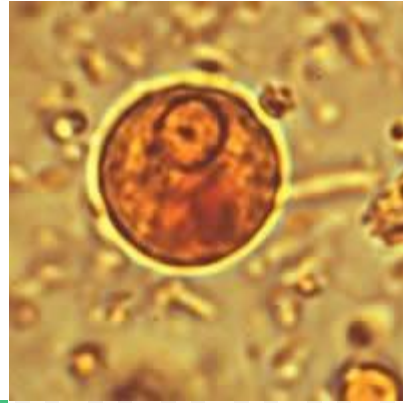



Zettore di Batteriologia
Laboratorio Patologia Clinica - P.O. Teramo



Cysts of *Entamoeba histolytica/E.dispar*

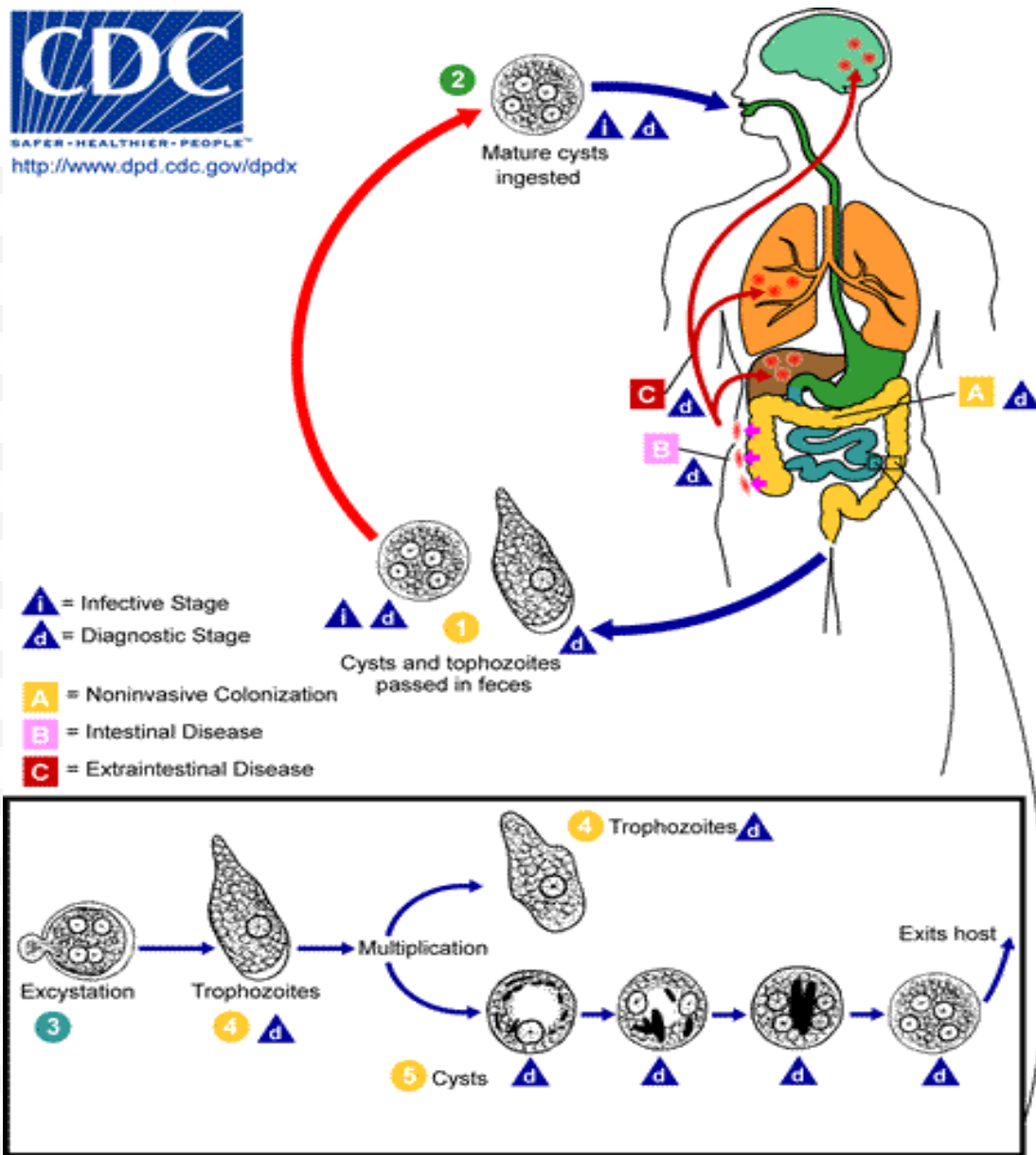


1 2 3 4 5 6 7 8 9

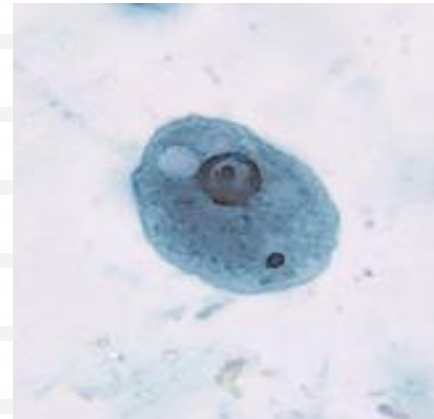
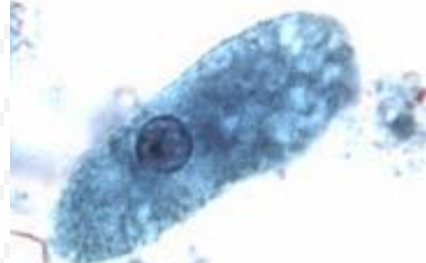
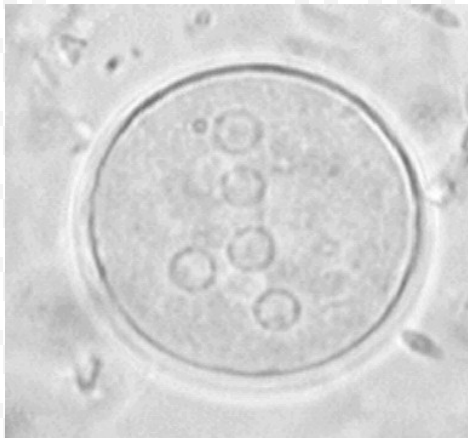
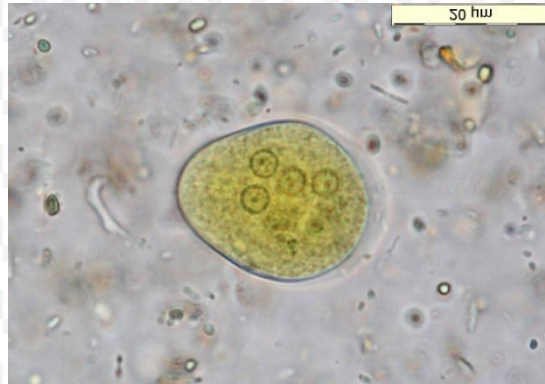
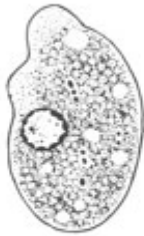
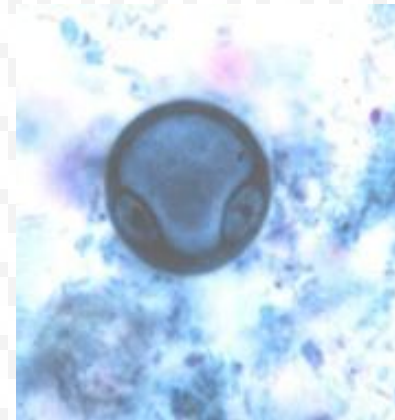
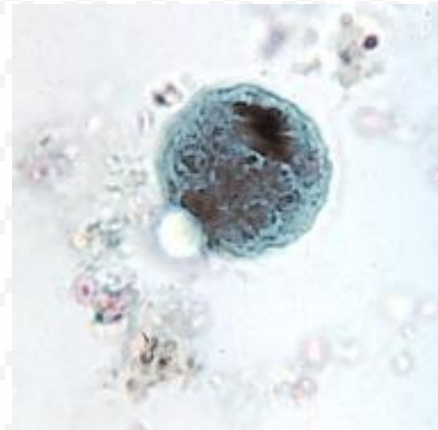
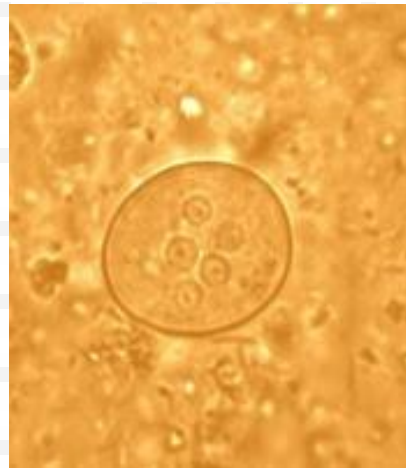ازمایشگاه سلامت

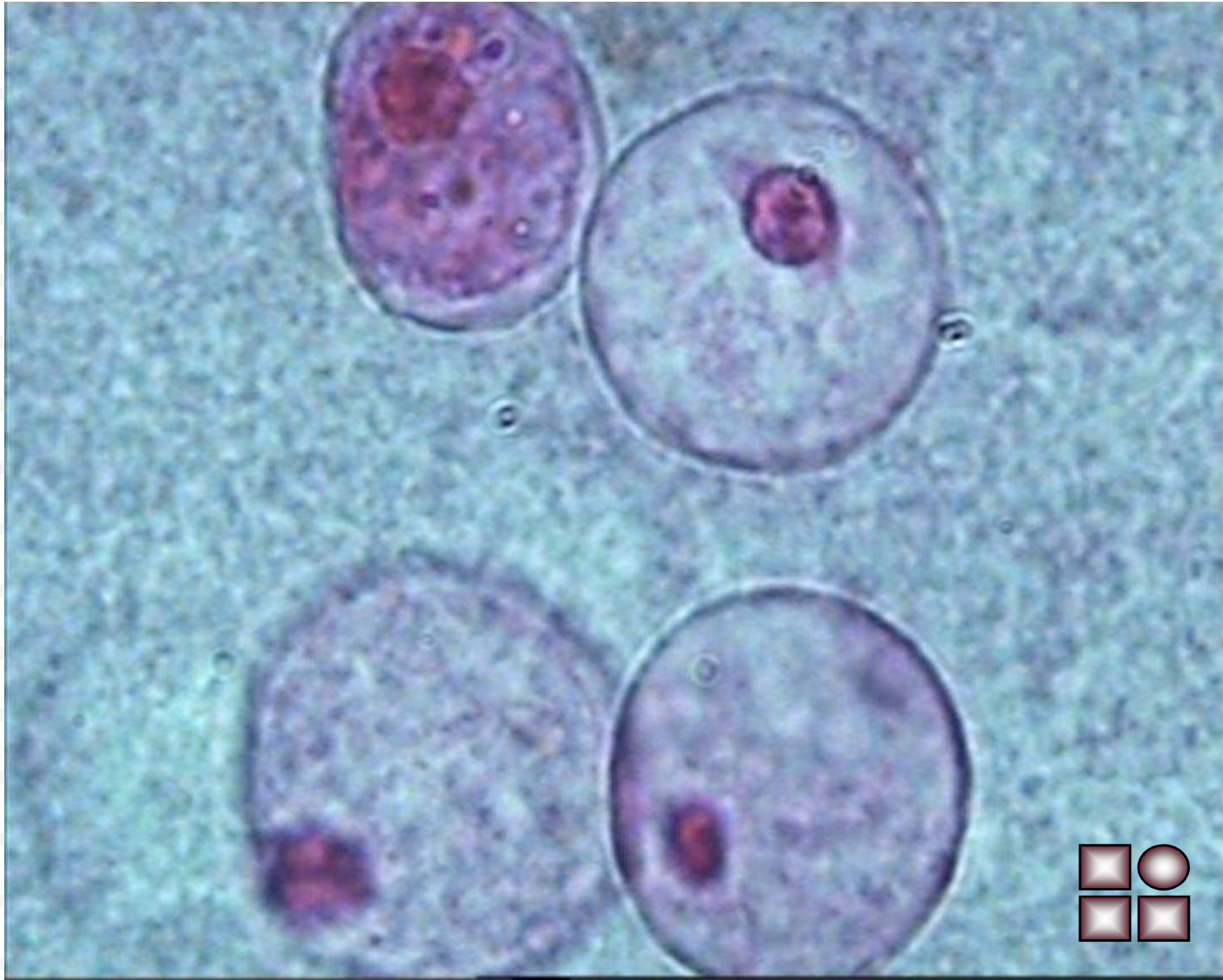


Entamoeba coli

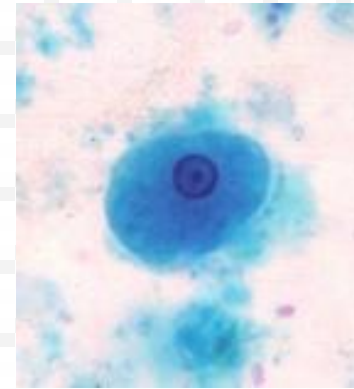
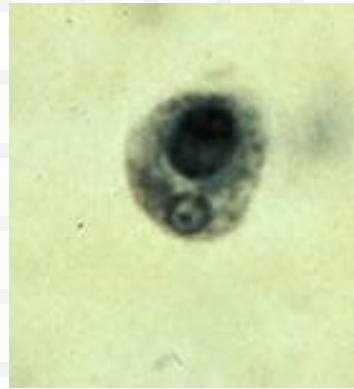
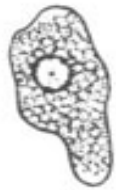

Cysts of *Entamoeba coli*



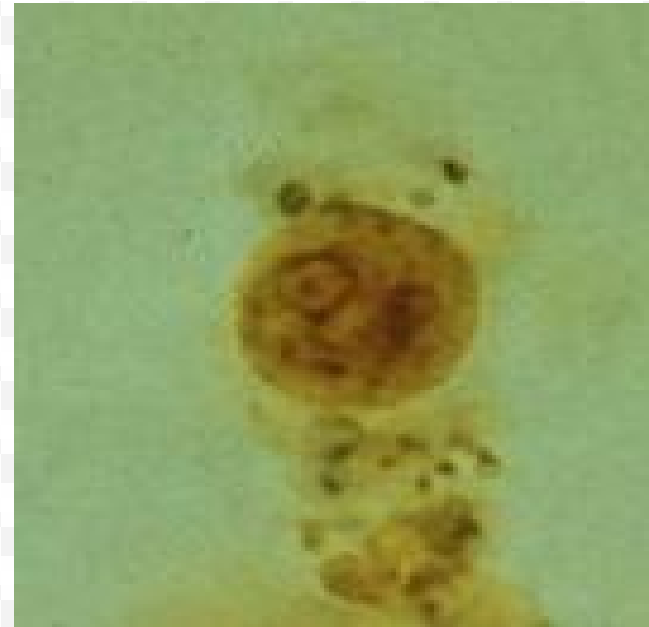
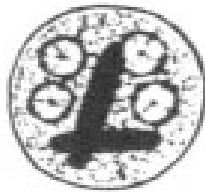

Trophozoites of *Entamoeba hartmanni*

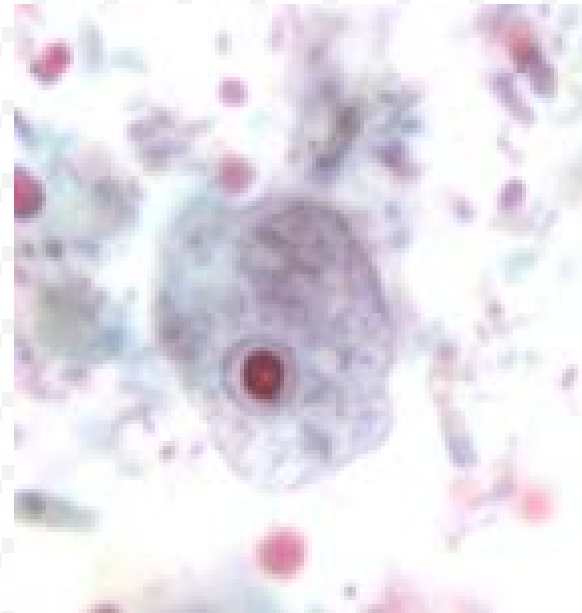
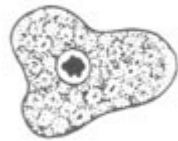




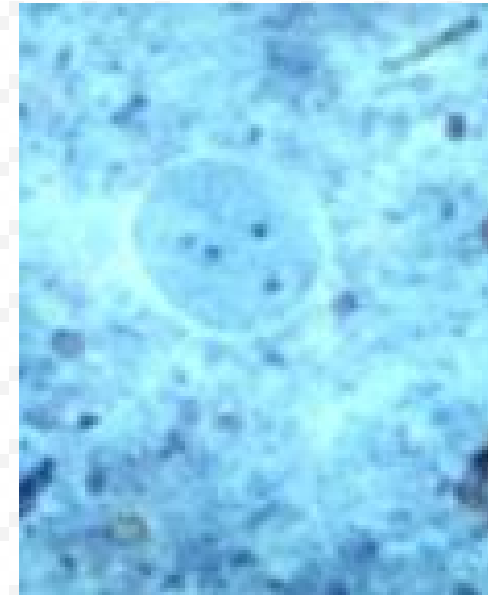
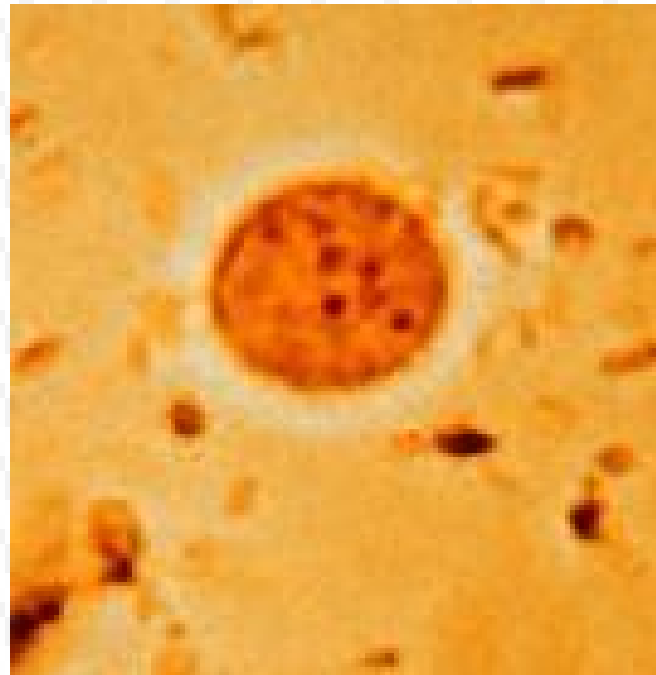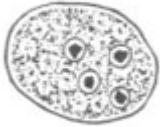
Cysts of *Entamoeba hartmanni*



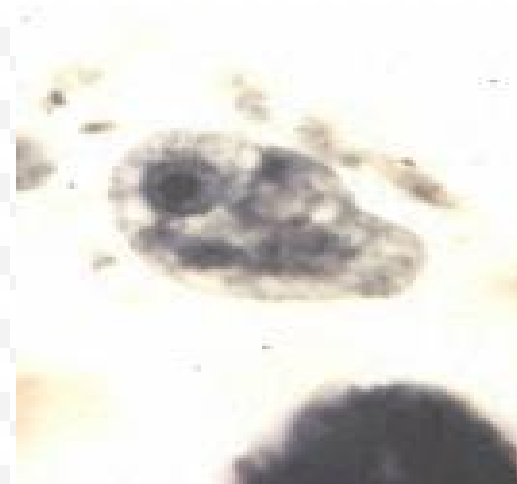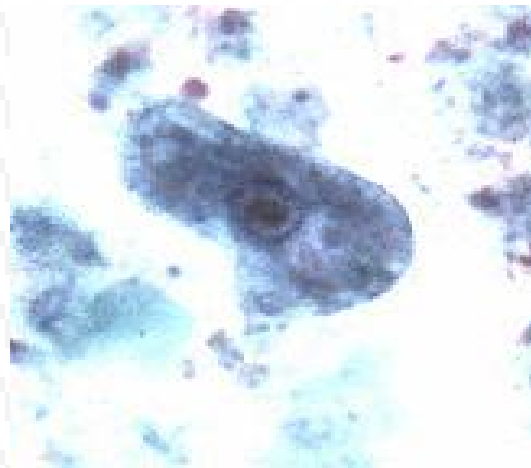
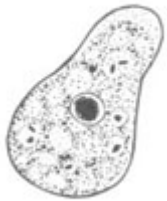
Endolimax nana trophozoites



Endolimax nana cysts

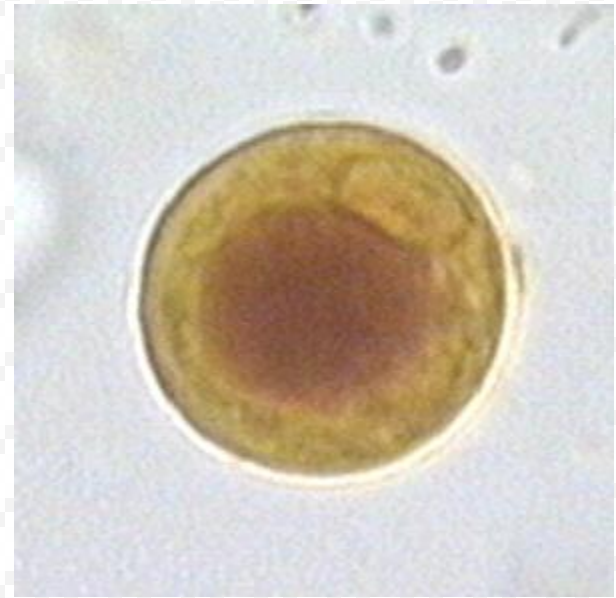
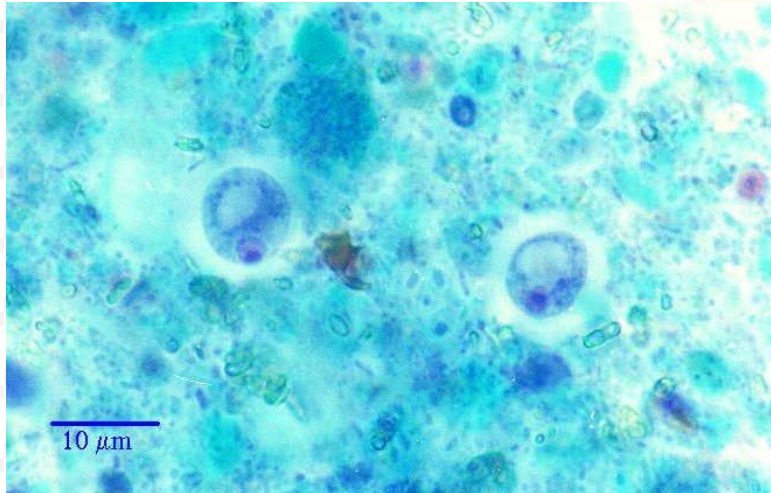
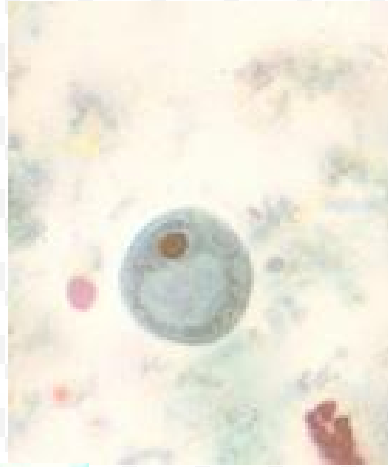
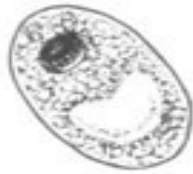

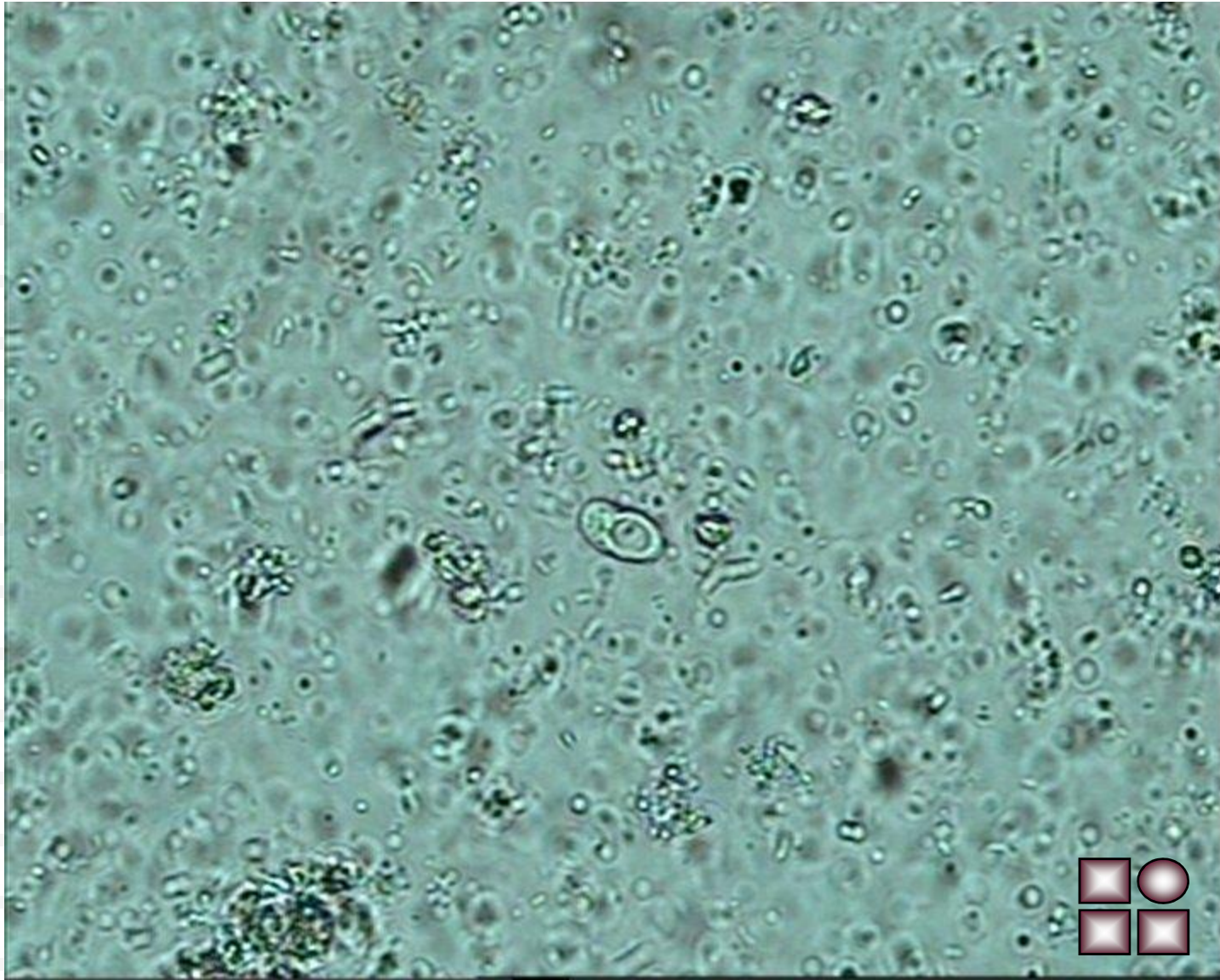
Iodamoeba buetschlii trophozoites

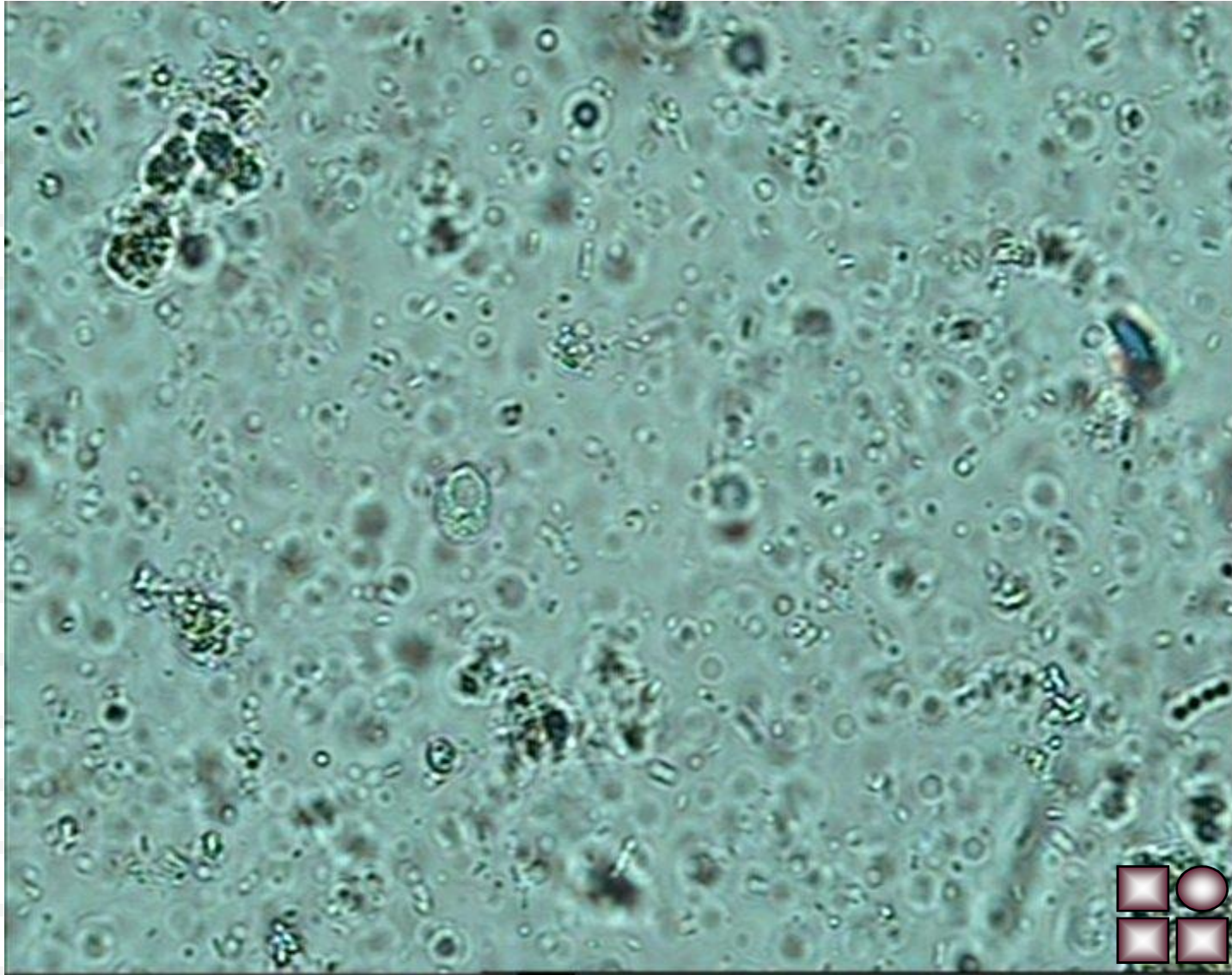


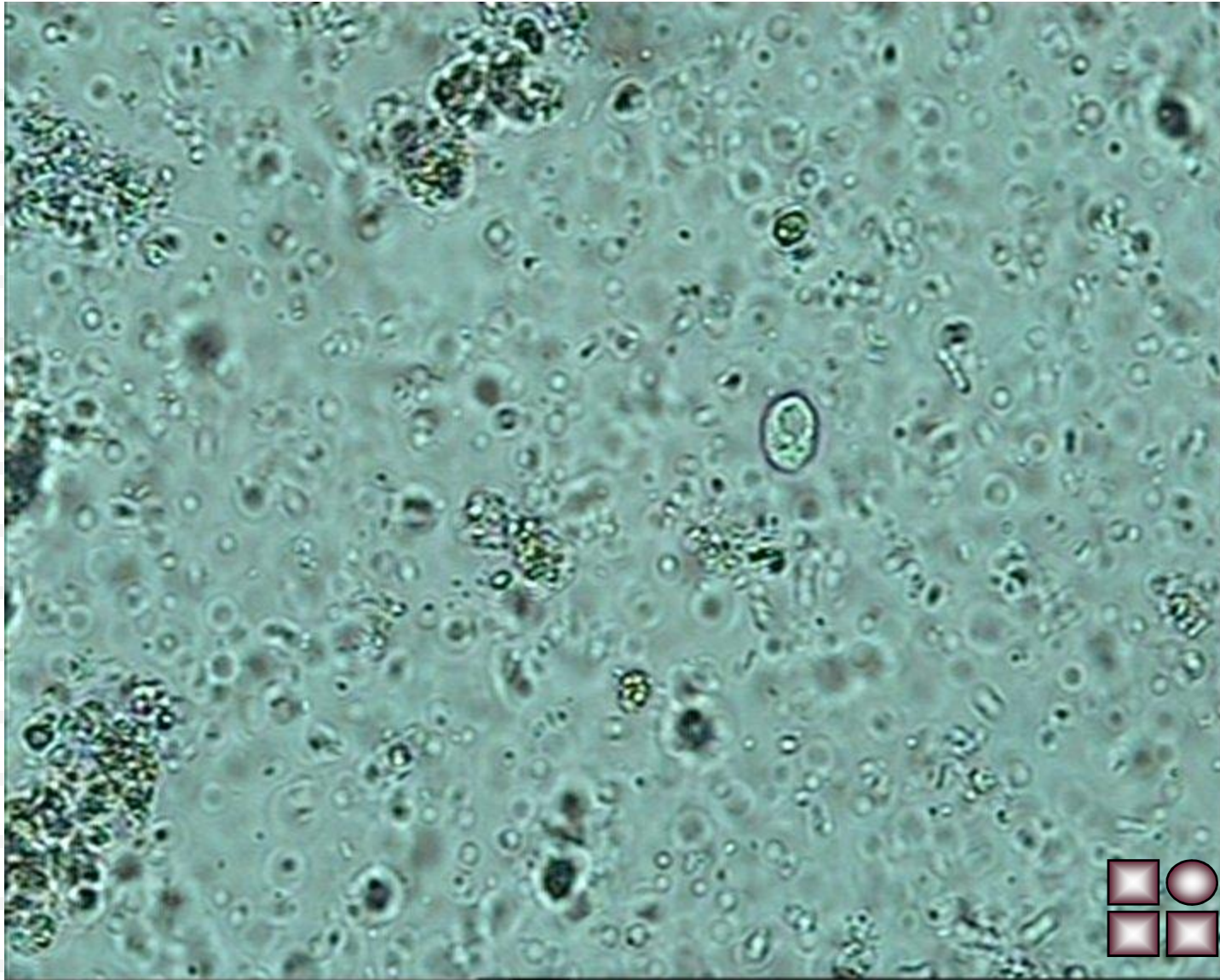



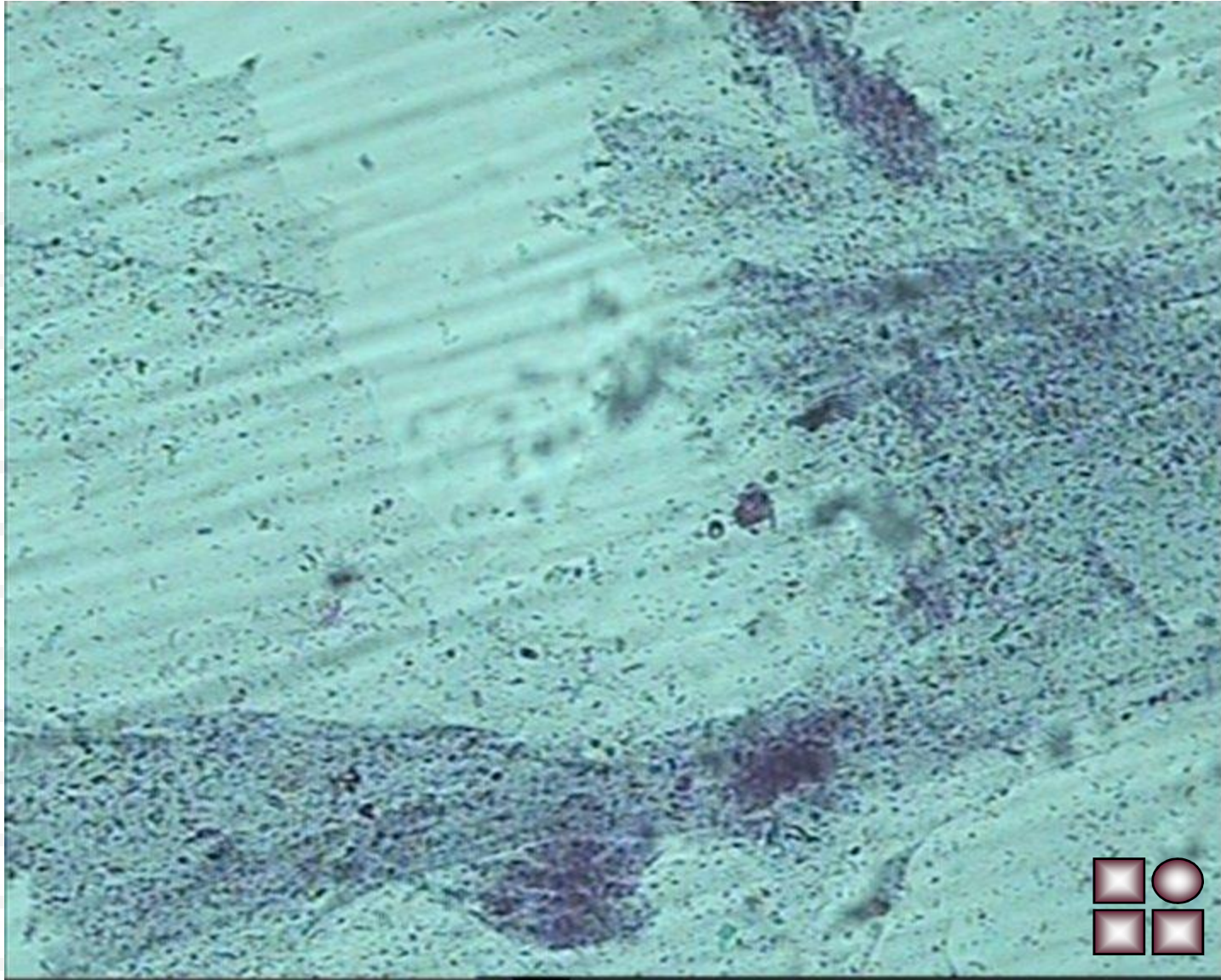
Iodamoeba buetschlii cysts


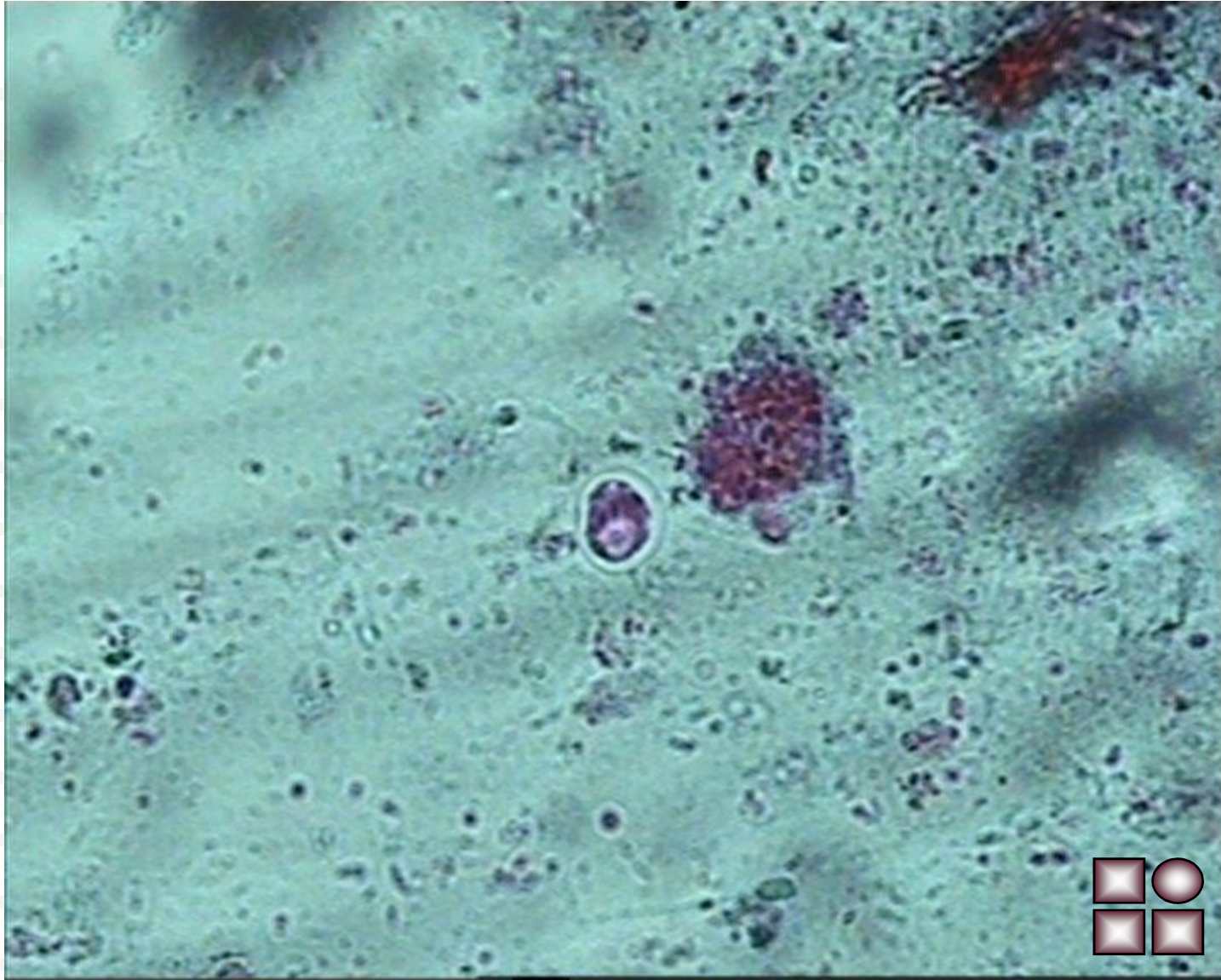



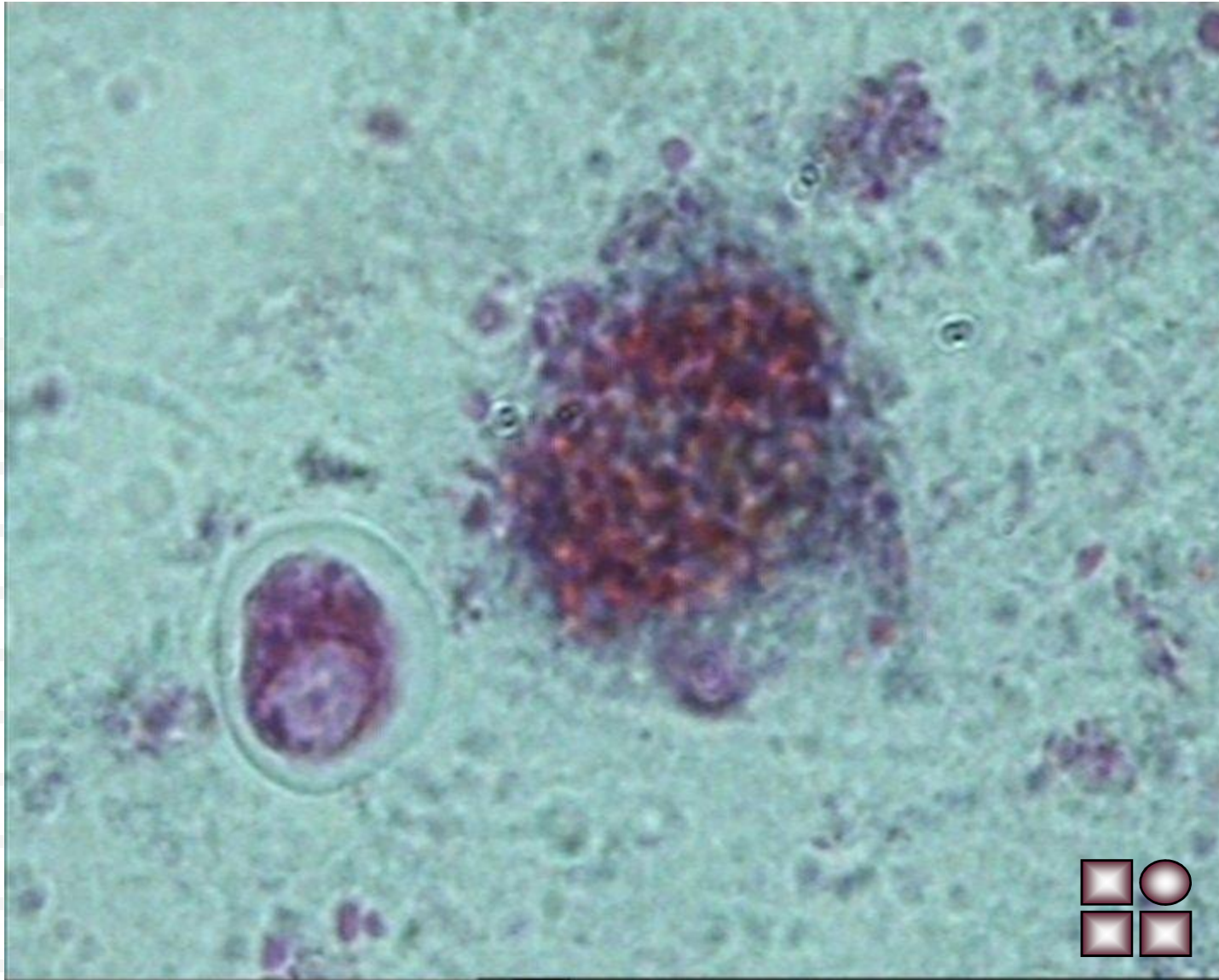




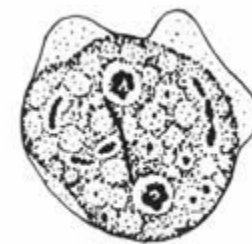

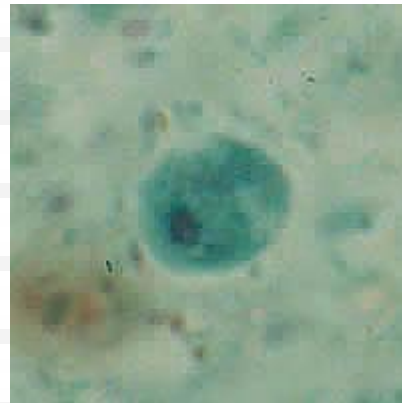
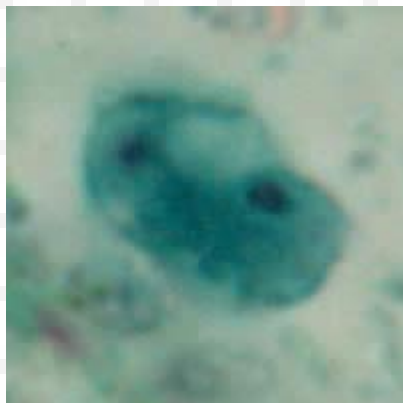
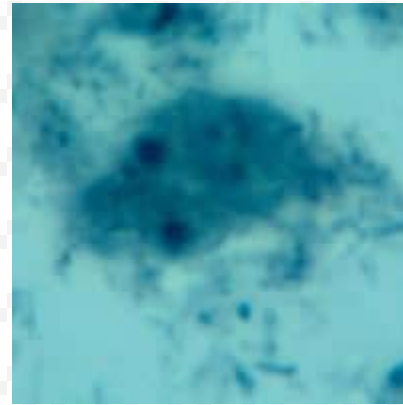
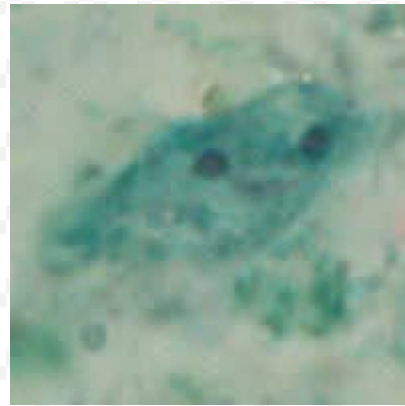






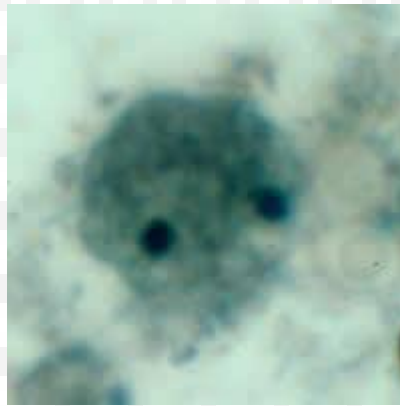
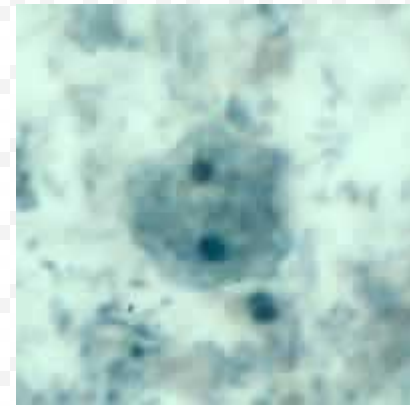
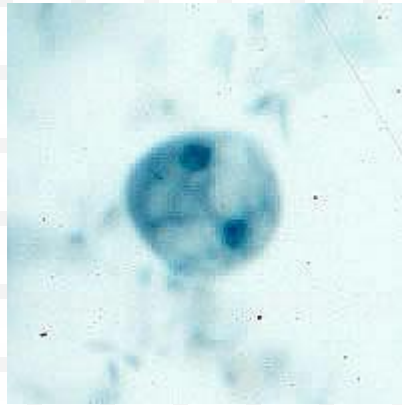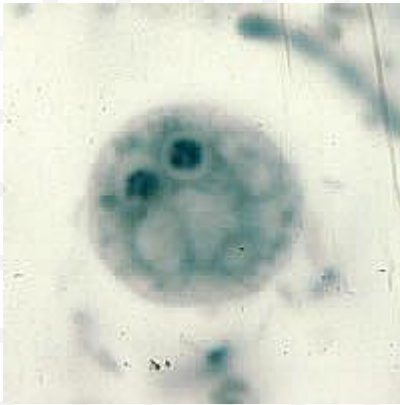


Dictyostelium discoideum has no cyst stage,
While most trophozoites are typically binucleate, some have only one
nucleus





Dientamoeba fragilis binucleated trophozoites

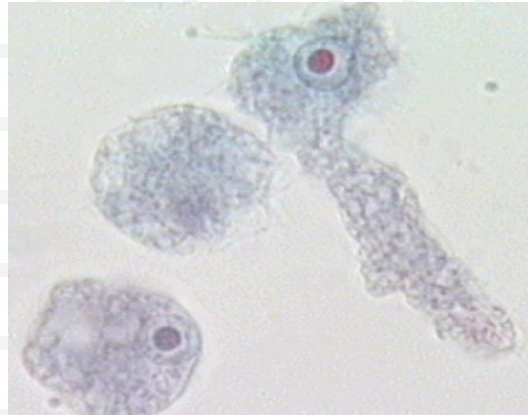
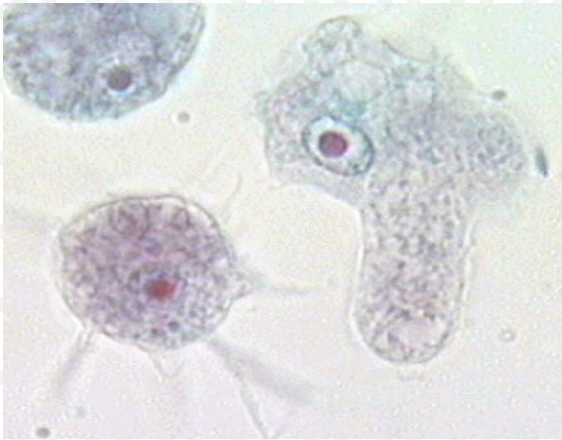
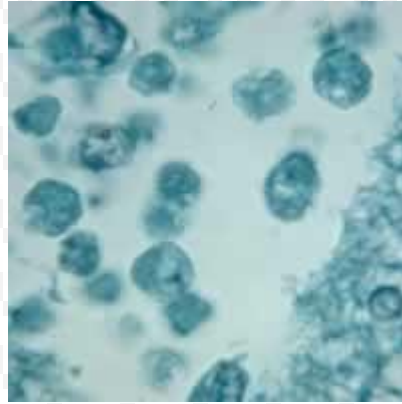
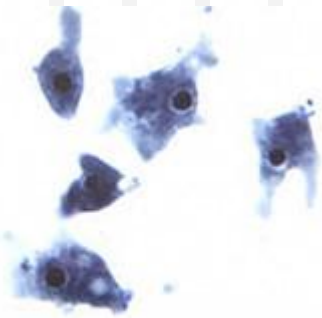


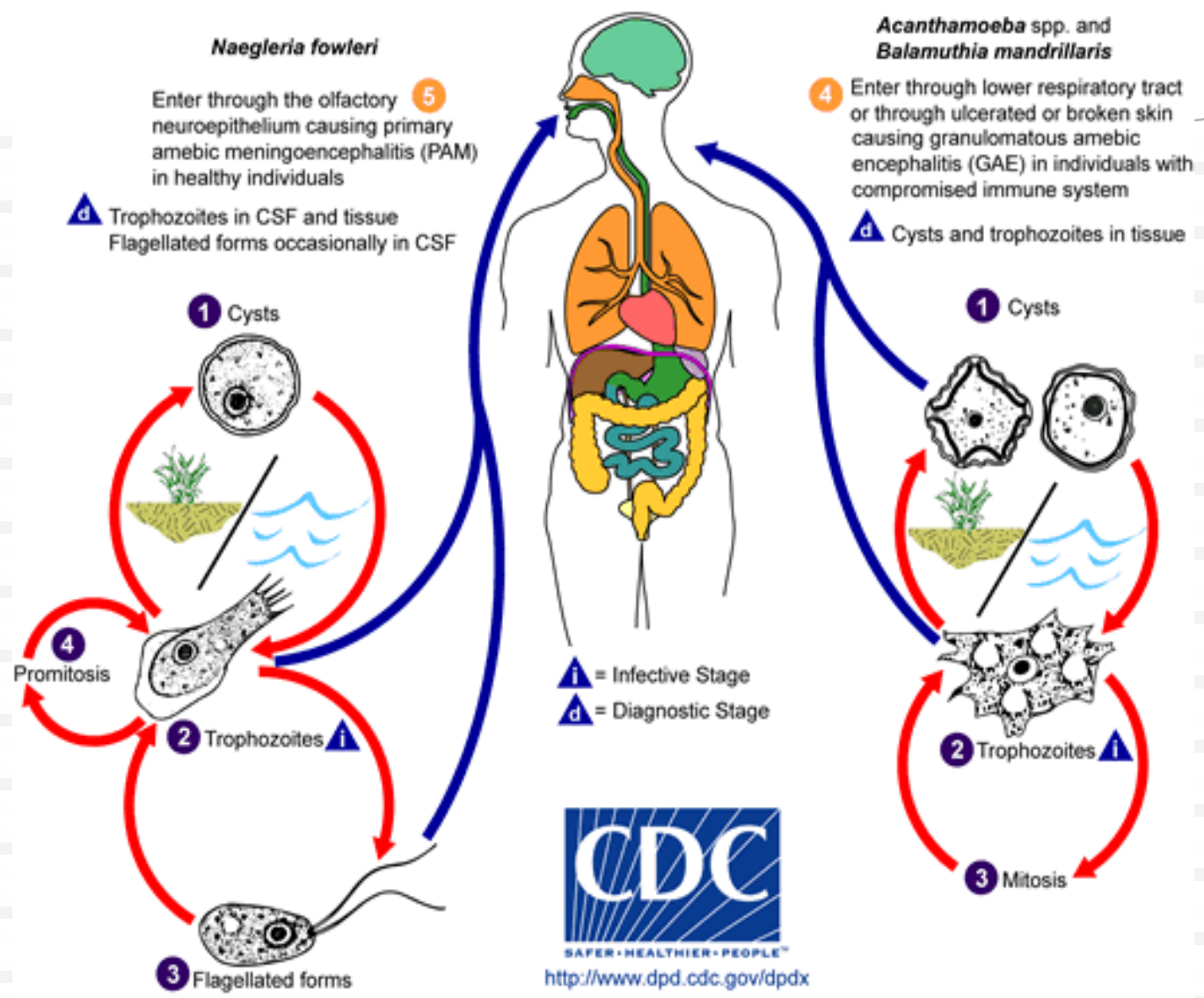


آمیبهای بازندگی آزاد

نگریا
آکانتوموبا

Naegleria fowleri trophozoites

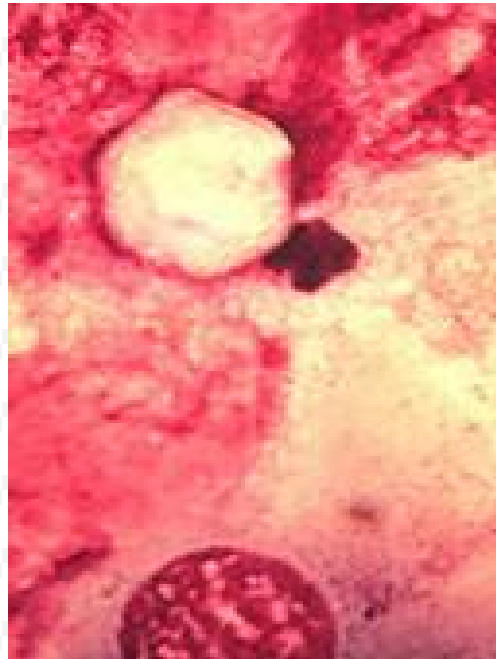



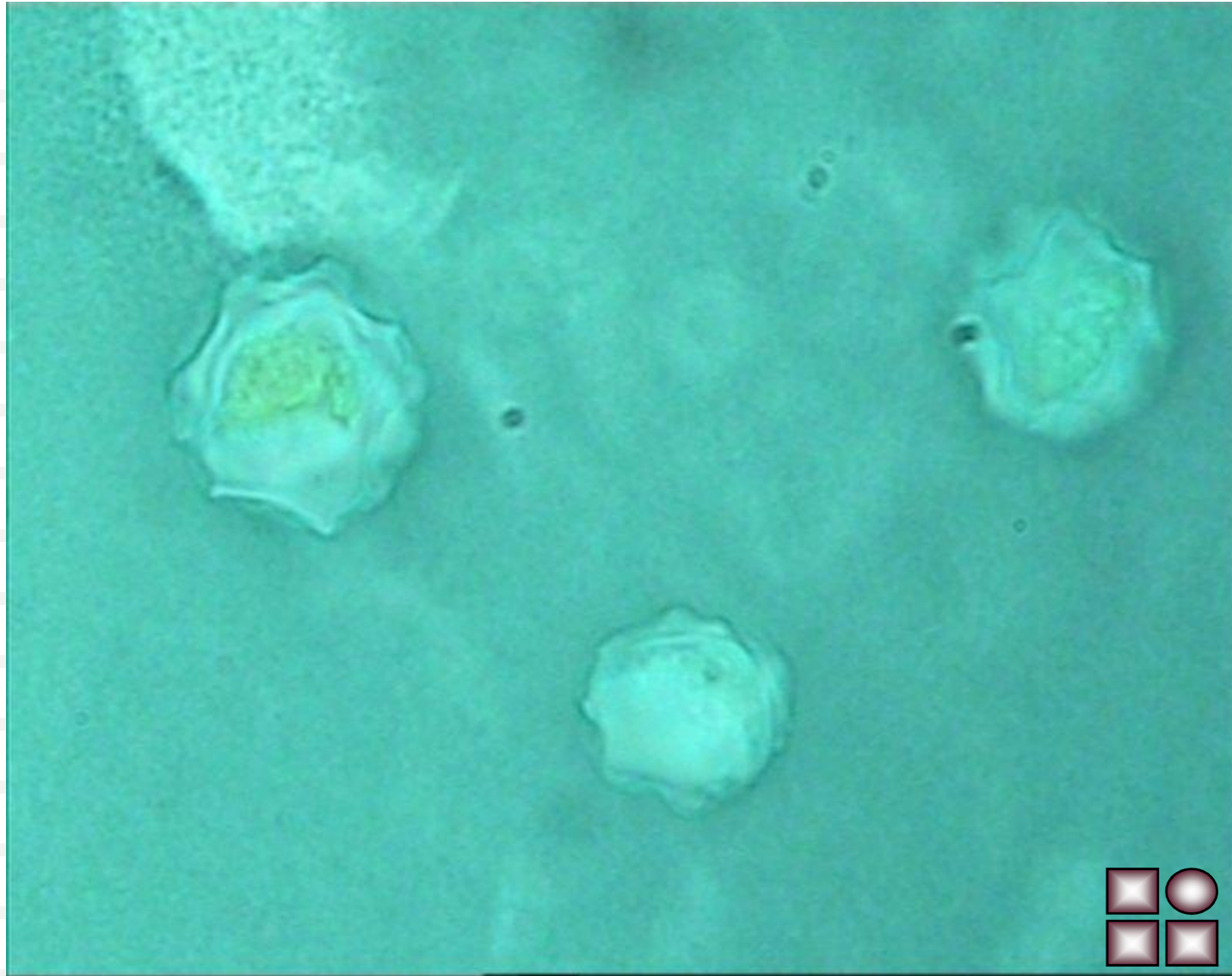



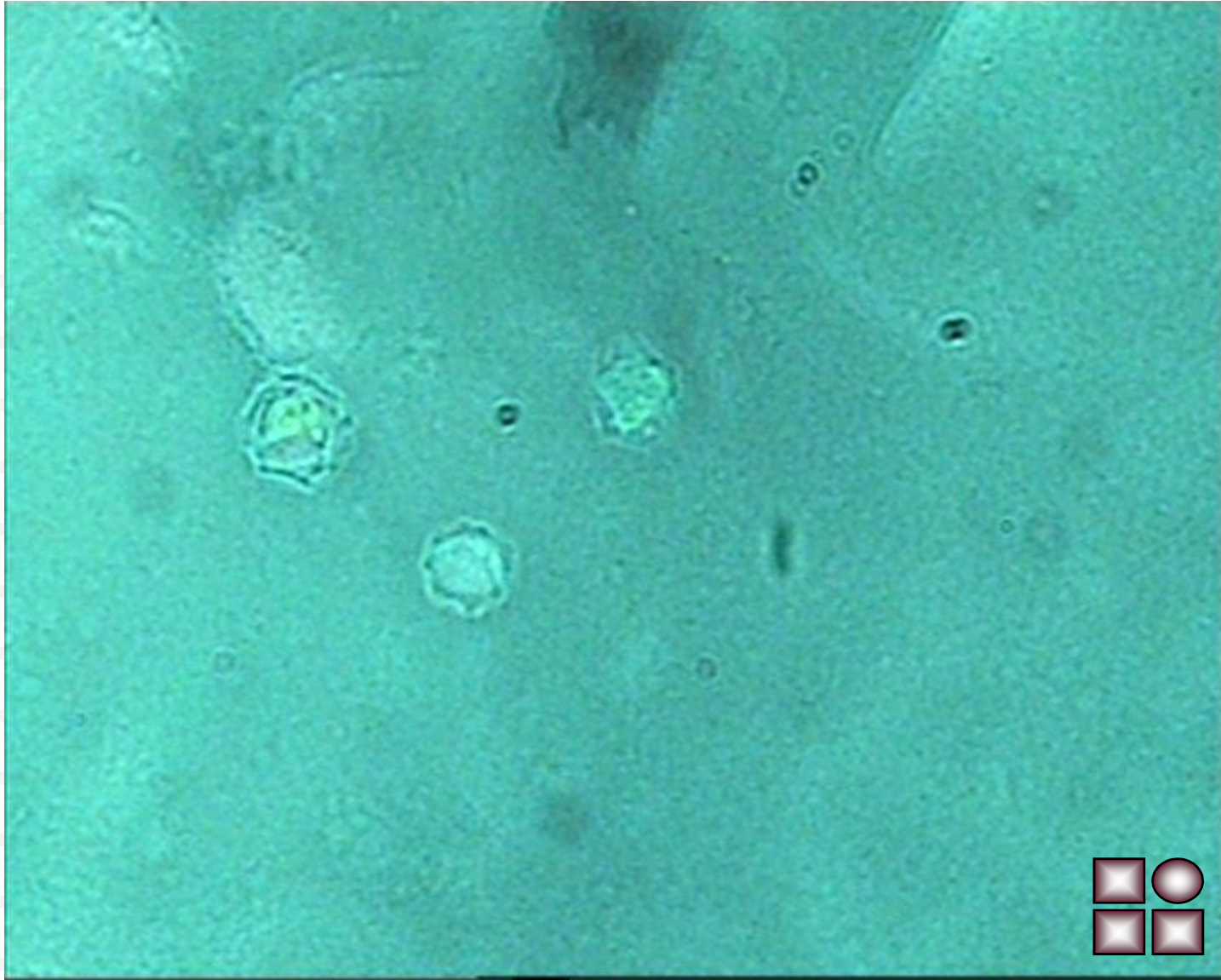




***Acanthamoeba sp.* keratitis.**

B : Cyst with the characteristic stellate shape, in corneal scraping.







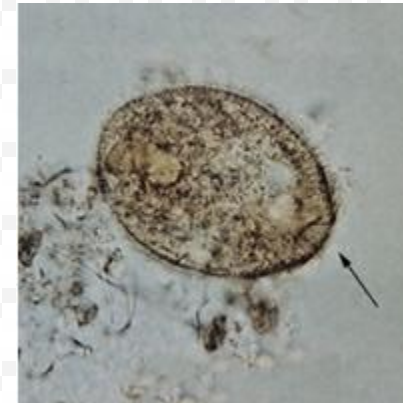
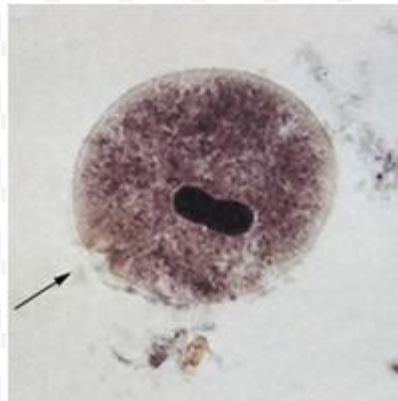
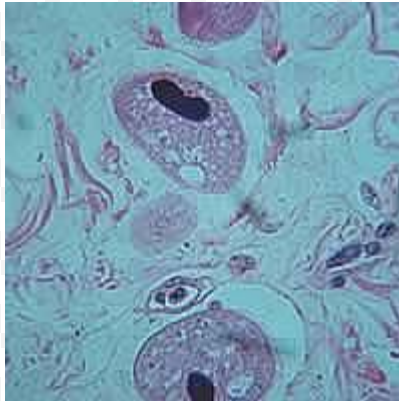




مژکداران

بالانتیوم کلی

Balantidium coli



***Balantidium coli* trophozoites in tissue, hematoxylin and eosin stain.**

***Balantidium coli* trophozoites.**


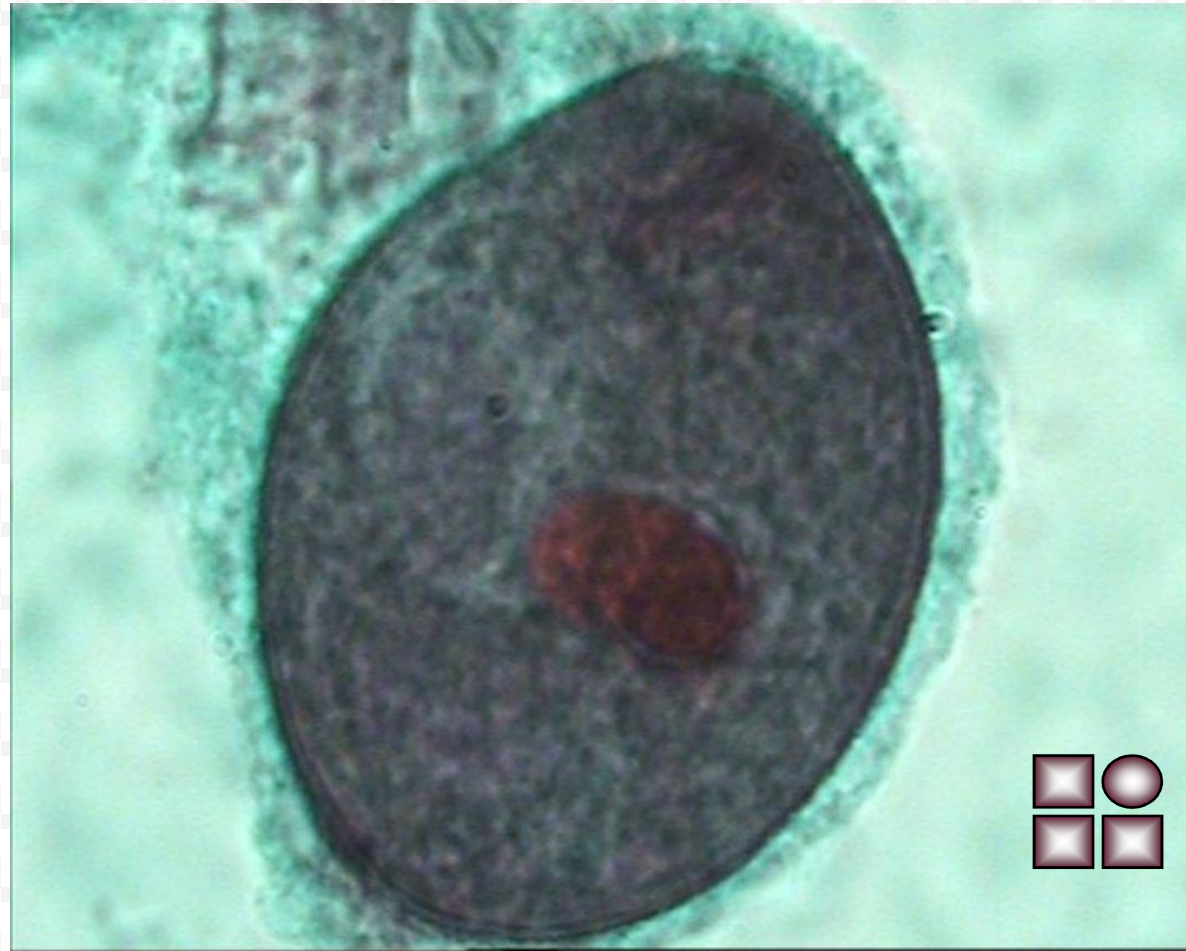
the presence of cilia on the cell surface

macronucleus which is often visible

And a smaller

less conspicuous micronucleus

Balantidium coli trophozoites

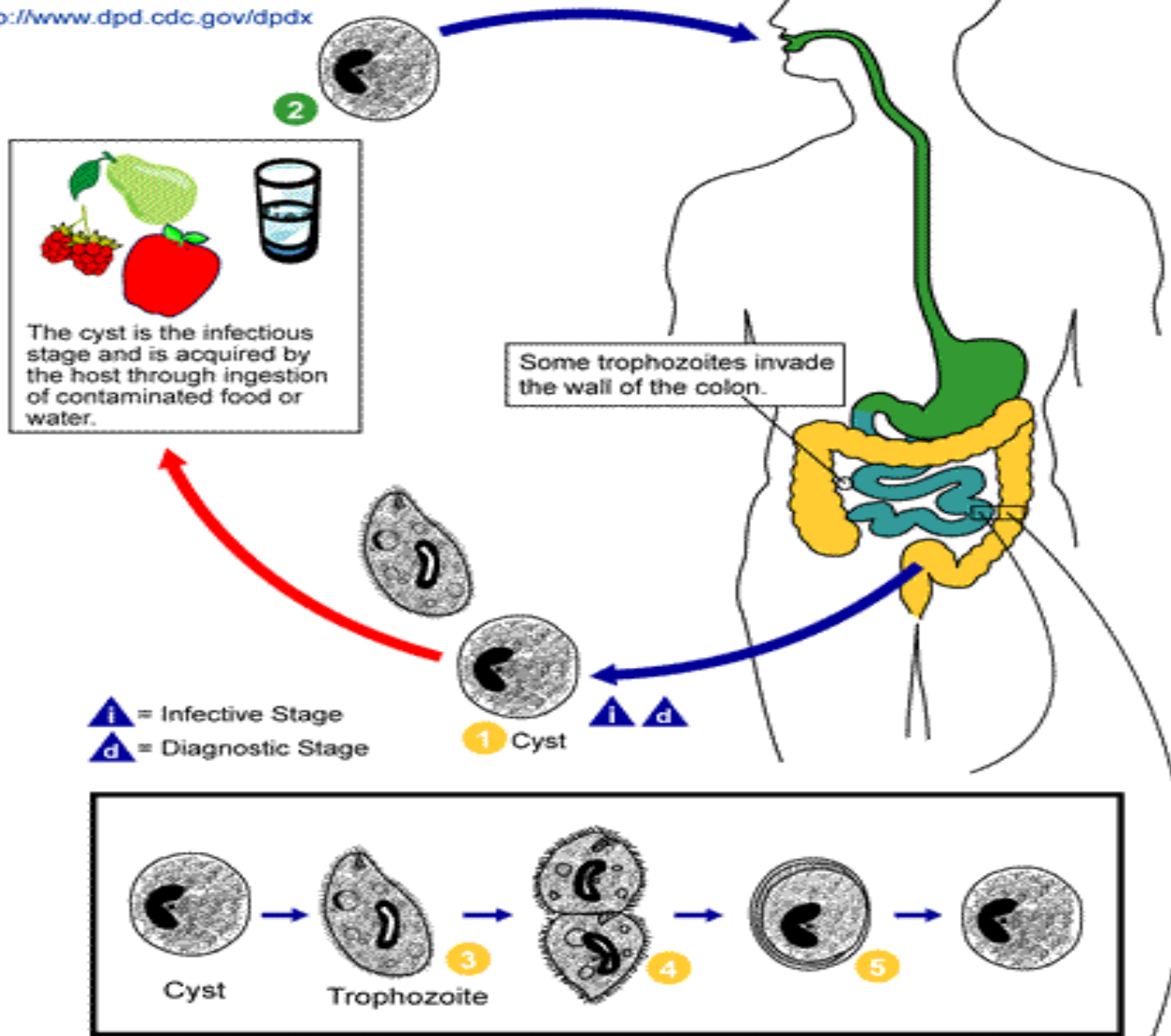




وزارت بهداشت و آموزش پزشکی



<http://www.dpd.cdc.gov/dpdx>

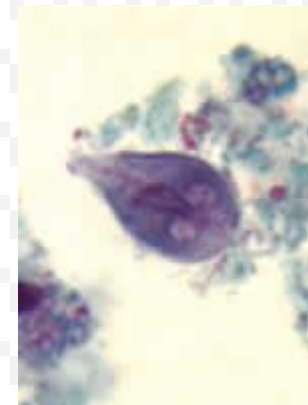
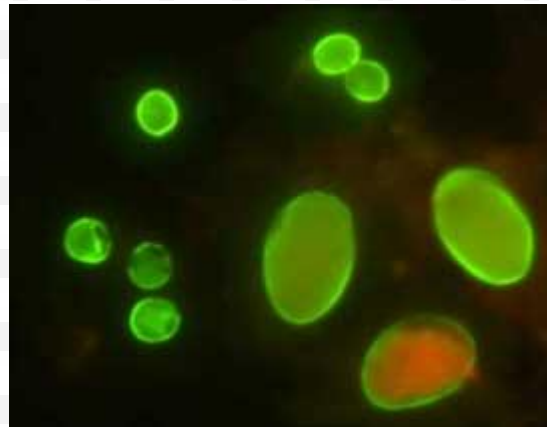
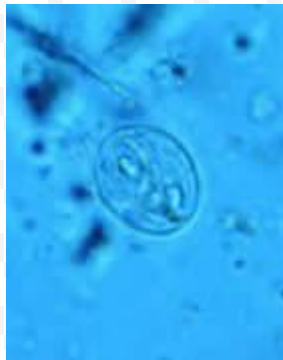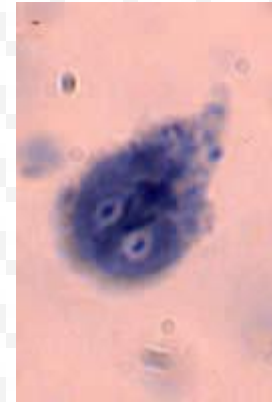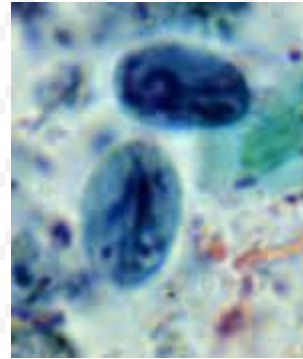


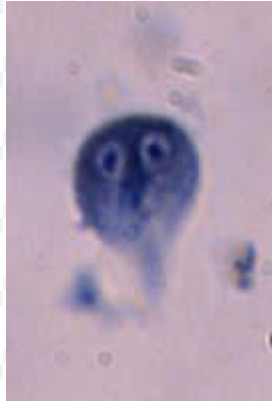

تاز کداران

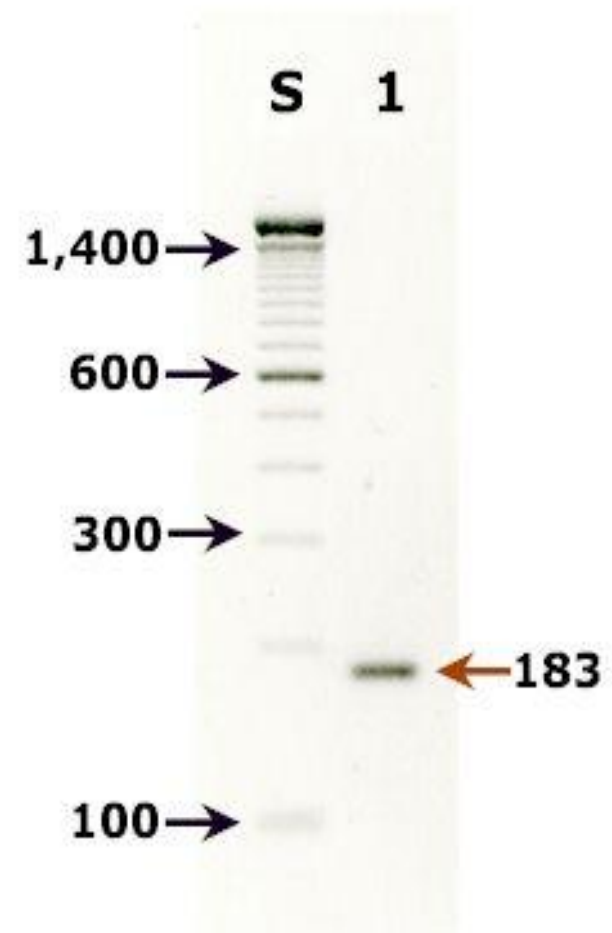
ژیا ردیا لامبلیا
تری کوموناس واژینالیس


Cysts & Trophozoite of *Giardia intestinalis*





- **A** :Agarose gel (2%) analysis of a PCR diagnostic test for detection of *Giardia* DNA. PCR was performed using primers JW₁/JW₂ .)
- **Lane S** :Molecular base pair standard (100-bp ladder). Black arrows show the size of standard bands .
- **Lane 1** :*Giardia intestinalis* positive fecal specimen. The red arrow shows the diagnostic band for *G. intestinalis*) size: 183 bp





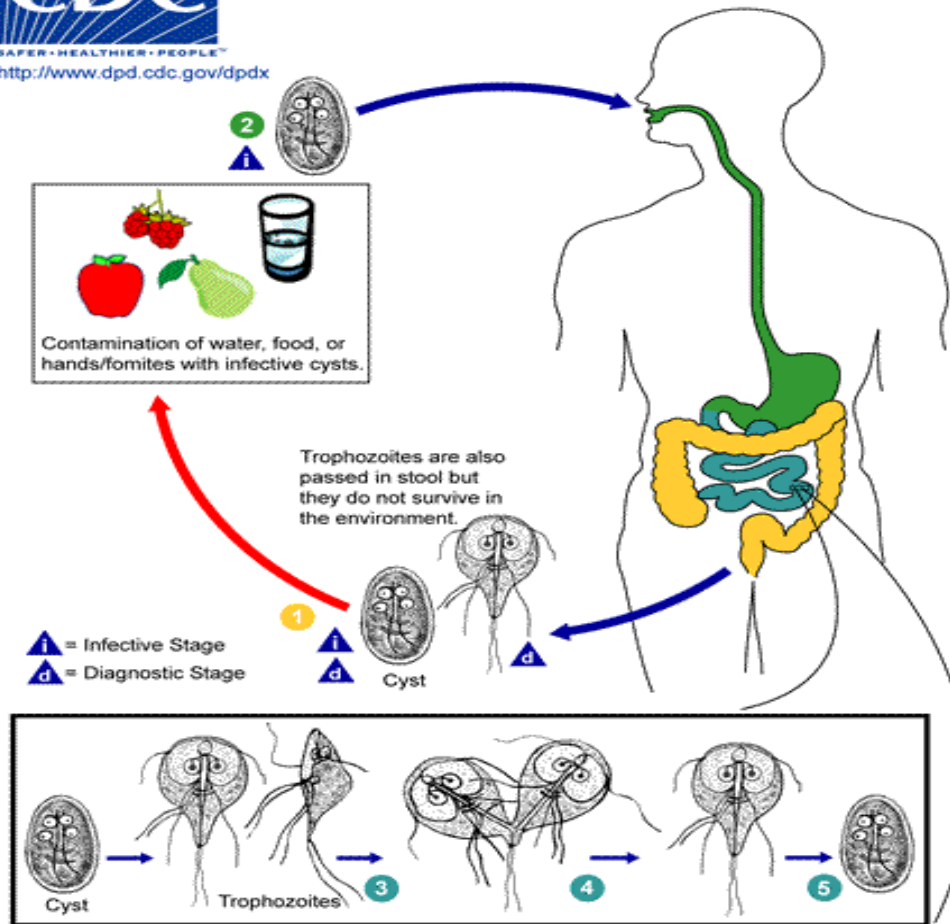
آزمایشگاه میکروبیولوژی

Life cycle of *Giardia intestinalis*

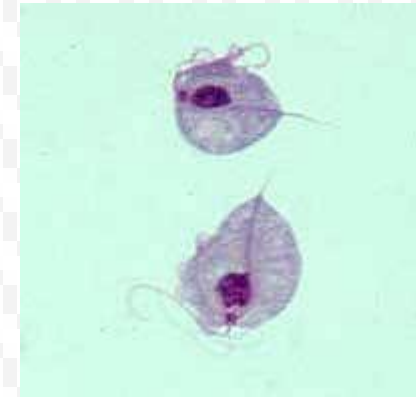
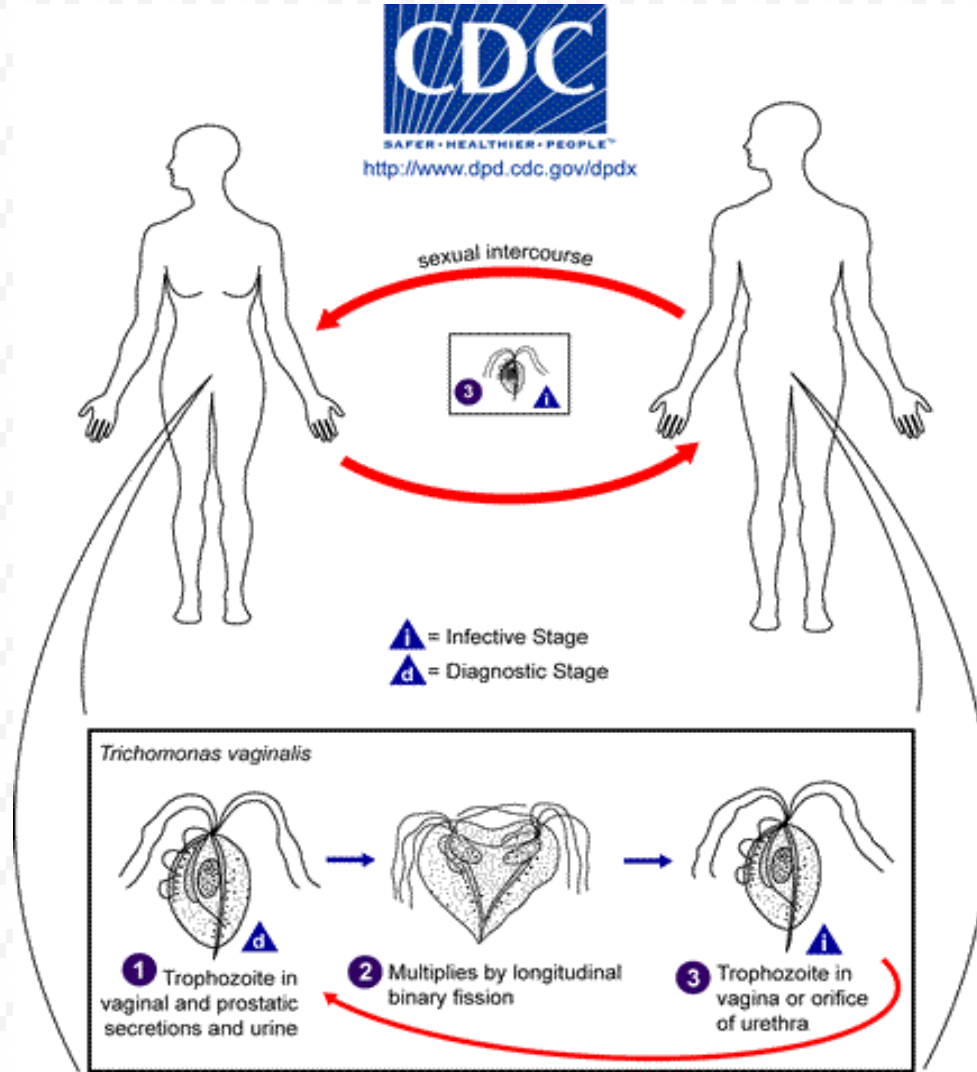


SAFER • HEALTHIER • PEOPLE™

<http://www.dpd.cdc.gov/dpdx>



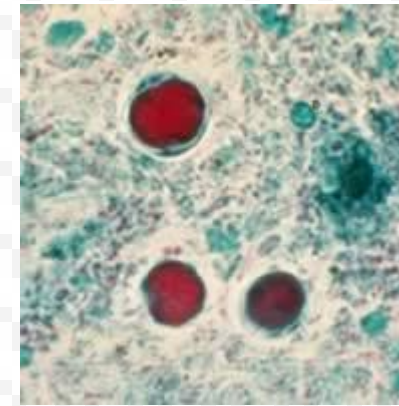
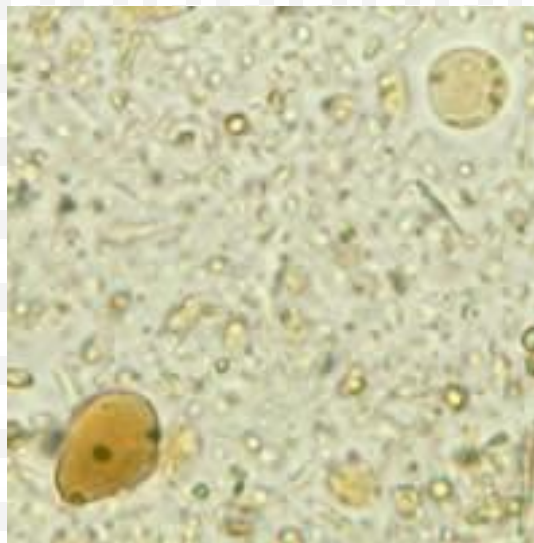

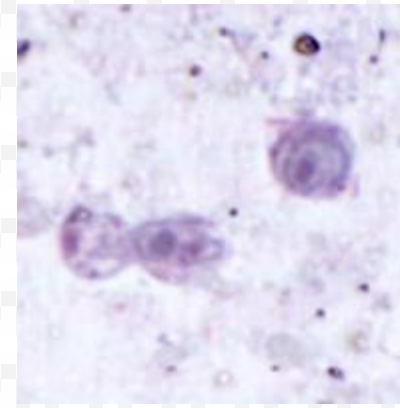
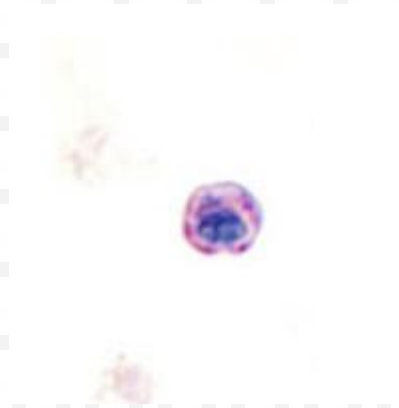
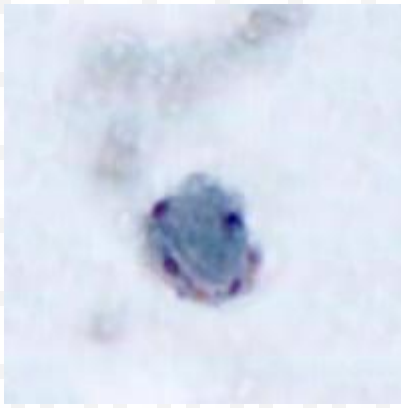
Life cycle & trophozoites of *Trichomonas vaginalis*






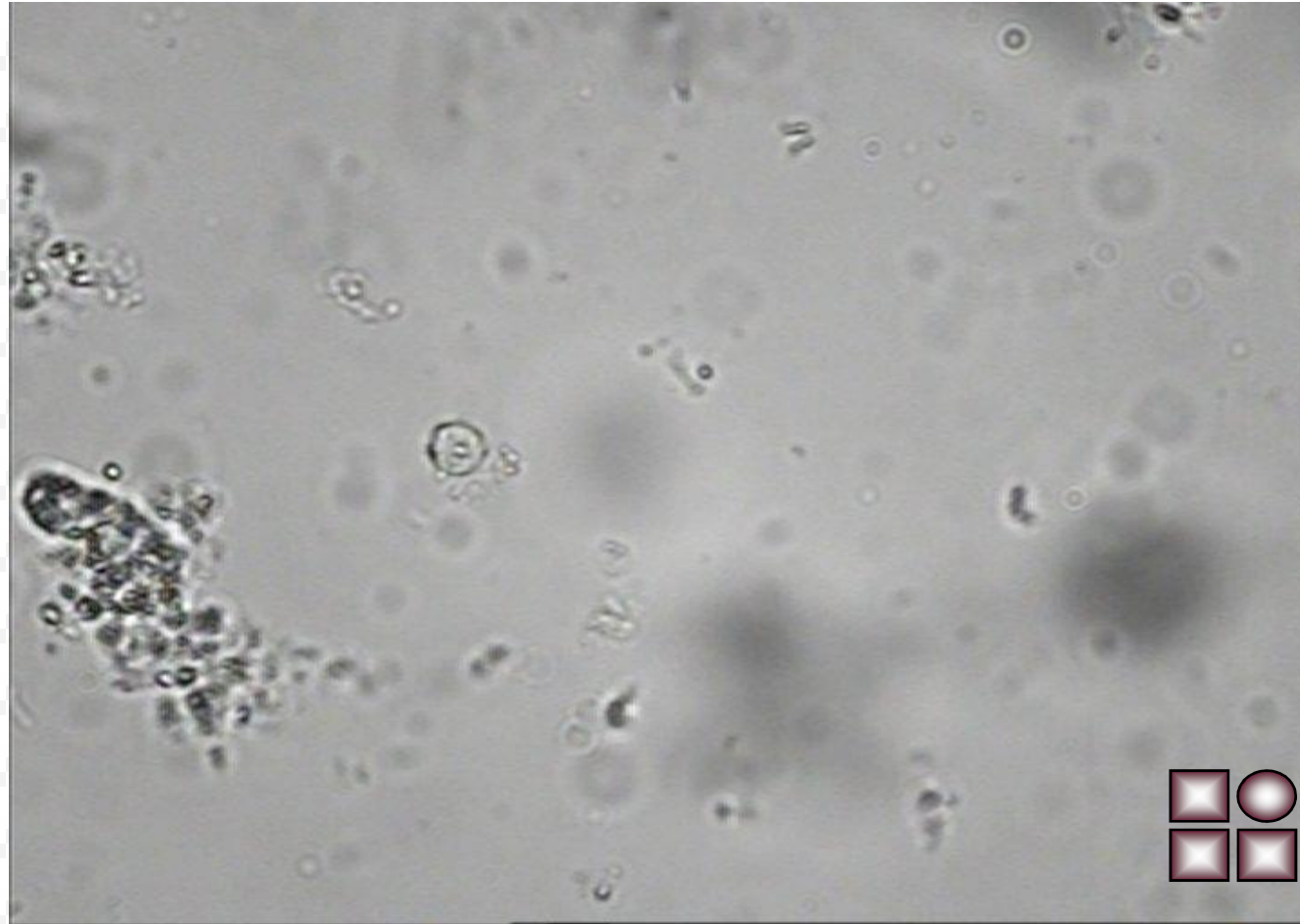
• بلاستوسیستیس هومینیس

Blastocystis hominis

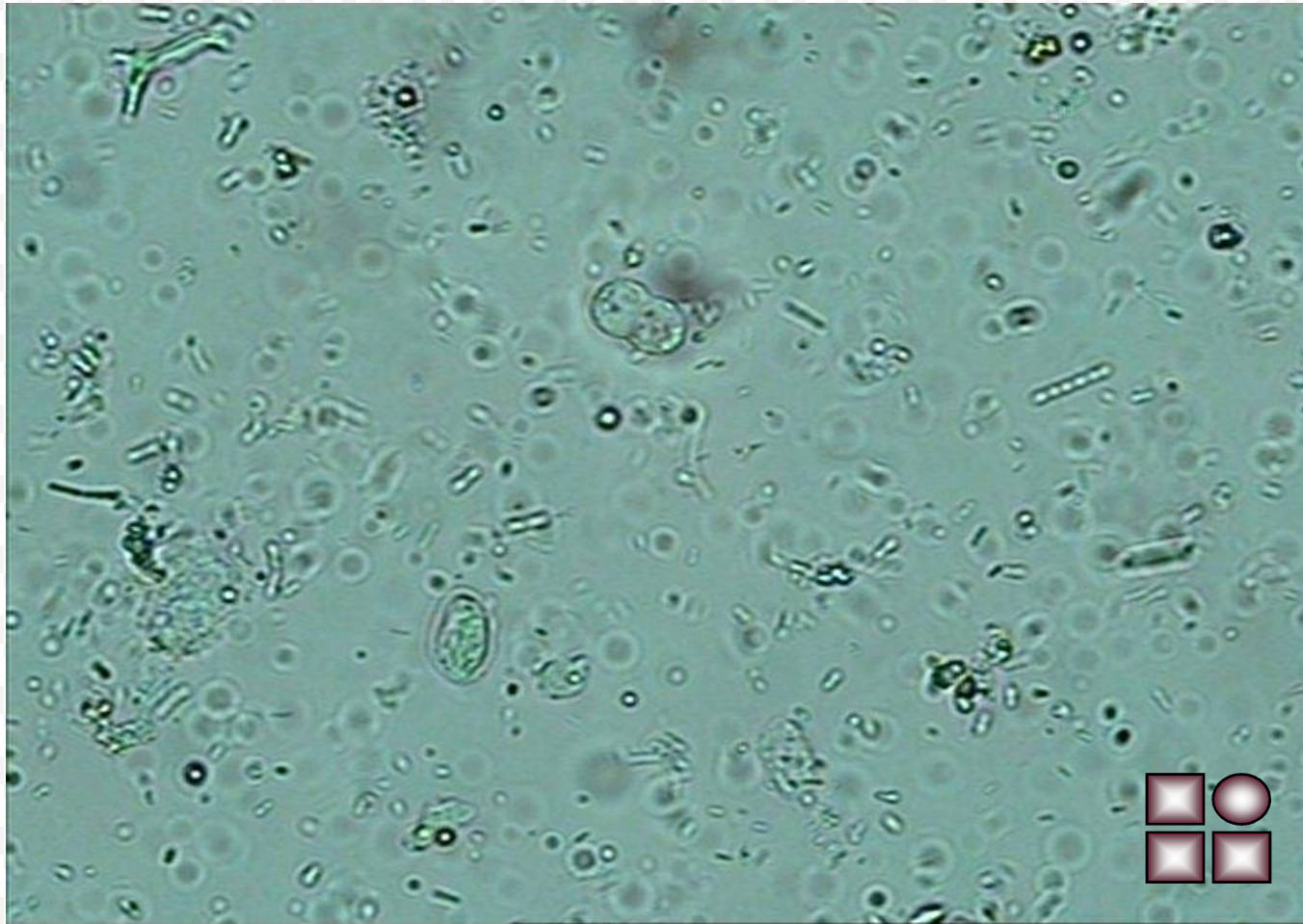




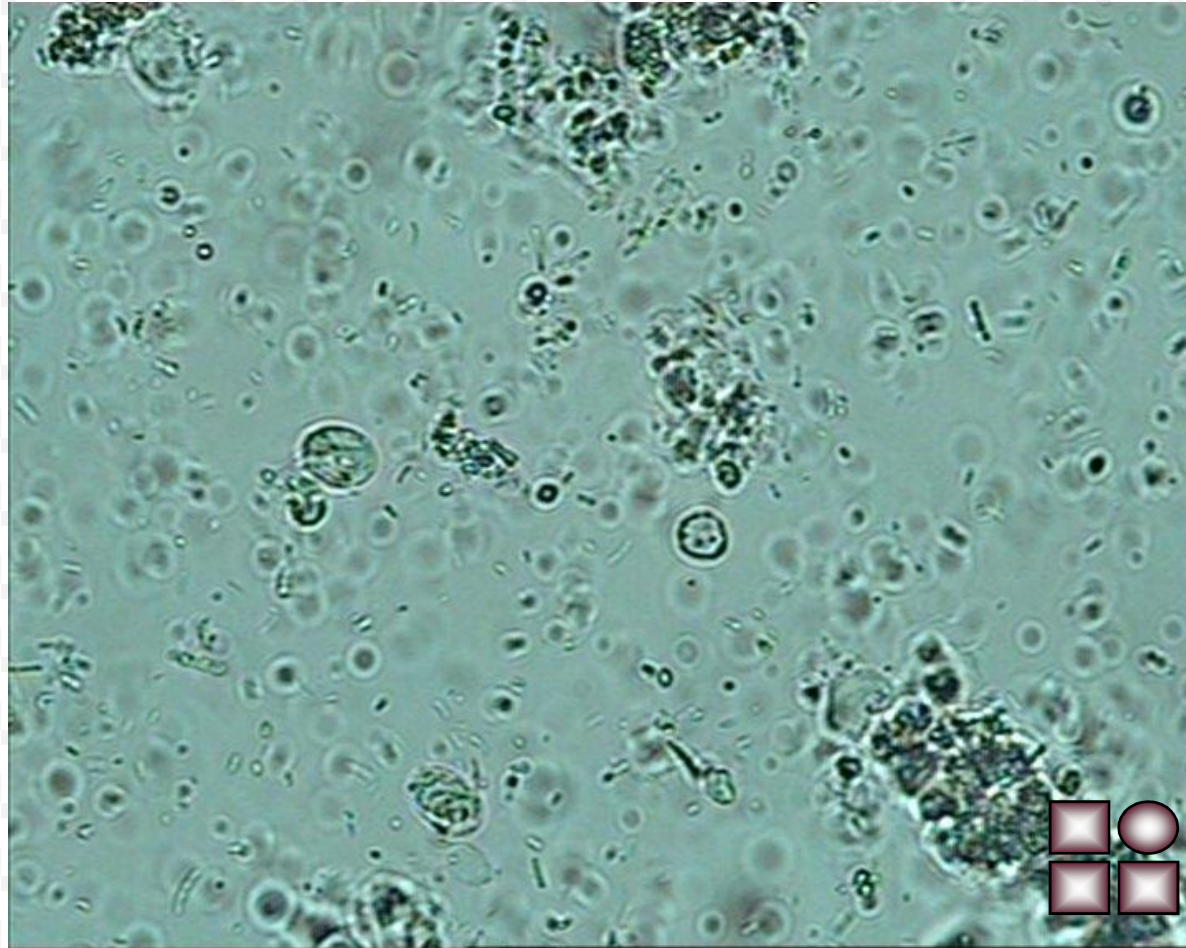Diastocystis hominis



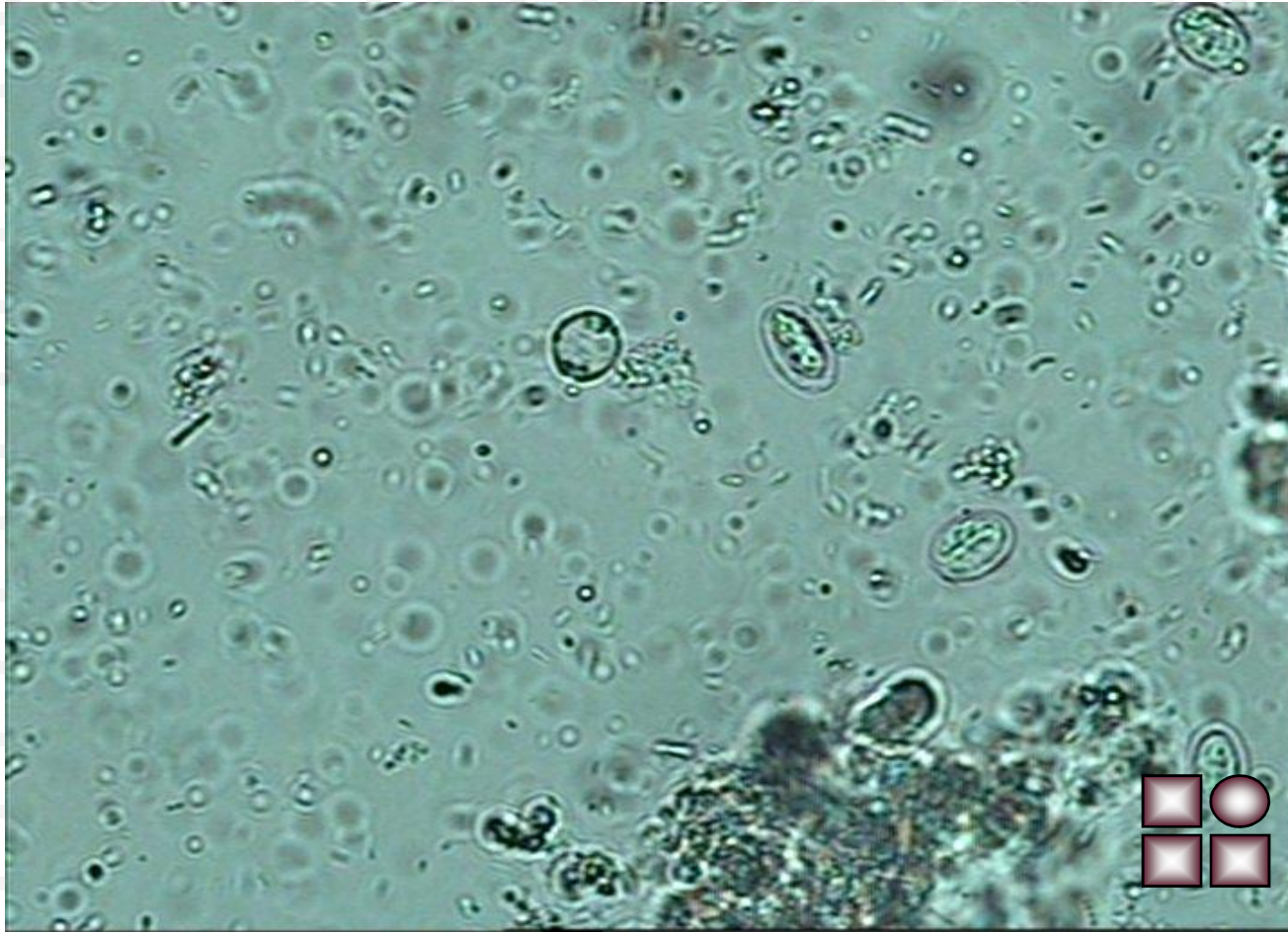
Cysts of *Giardia* & *Blastocystis hominis*



Blastocystis hominis & cysts of giardia



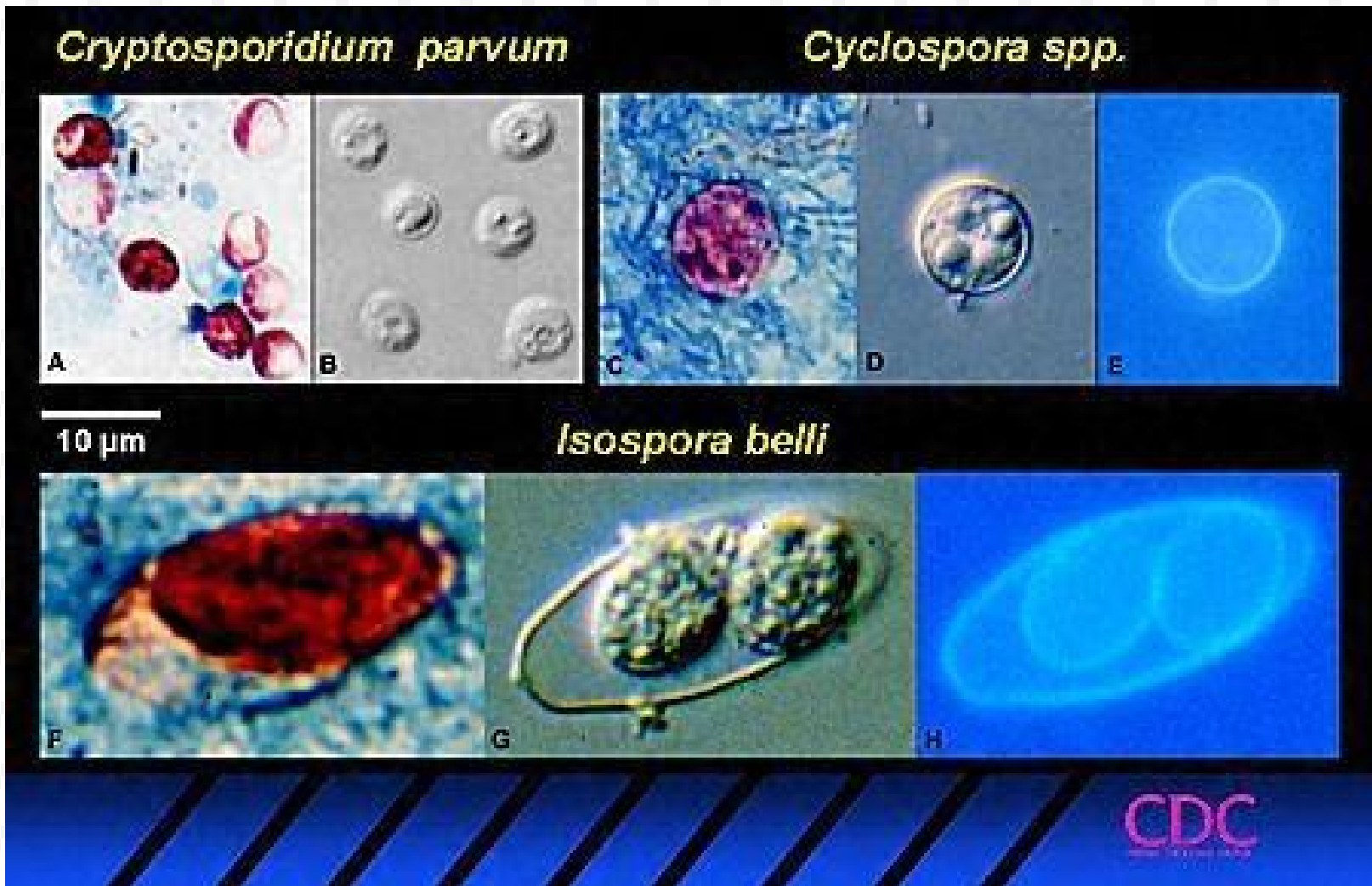Cysts of Giardia & Blastocystis Hominis





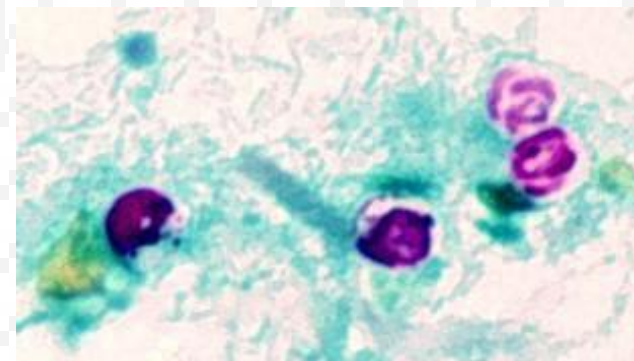
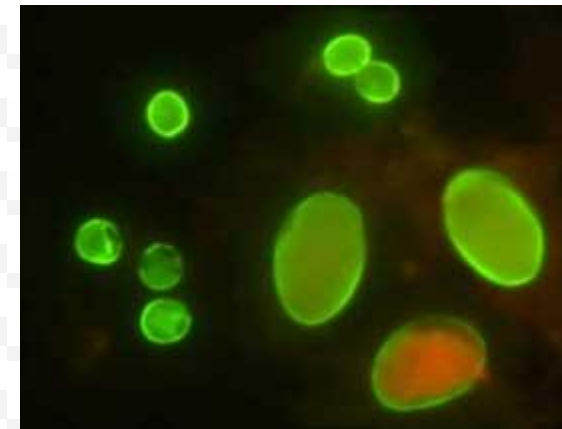
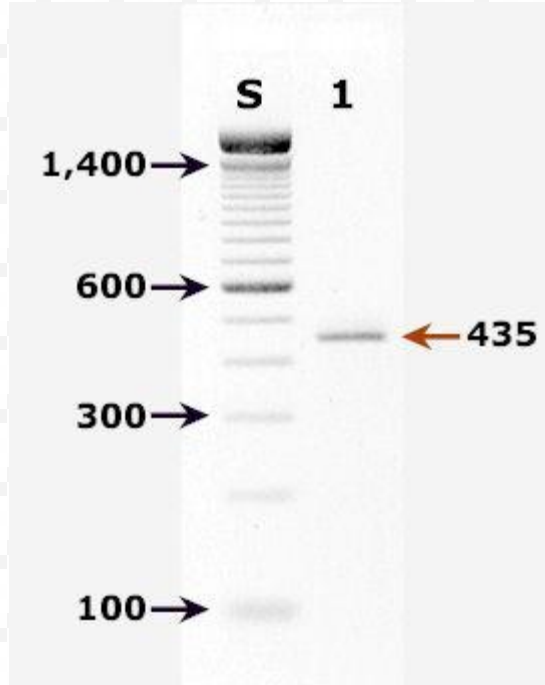
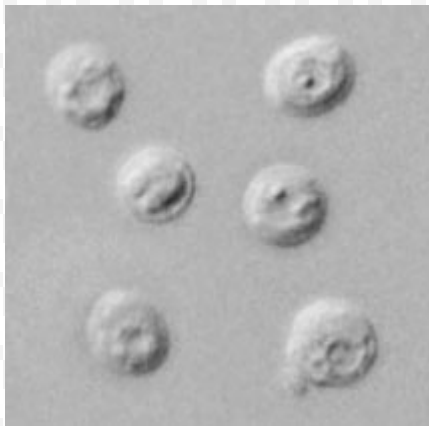
کوکسیدیا


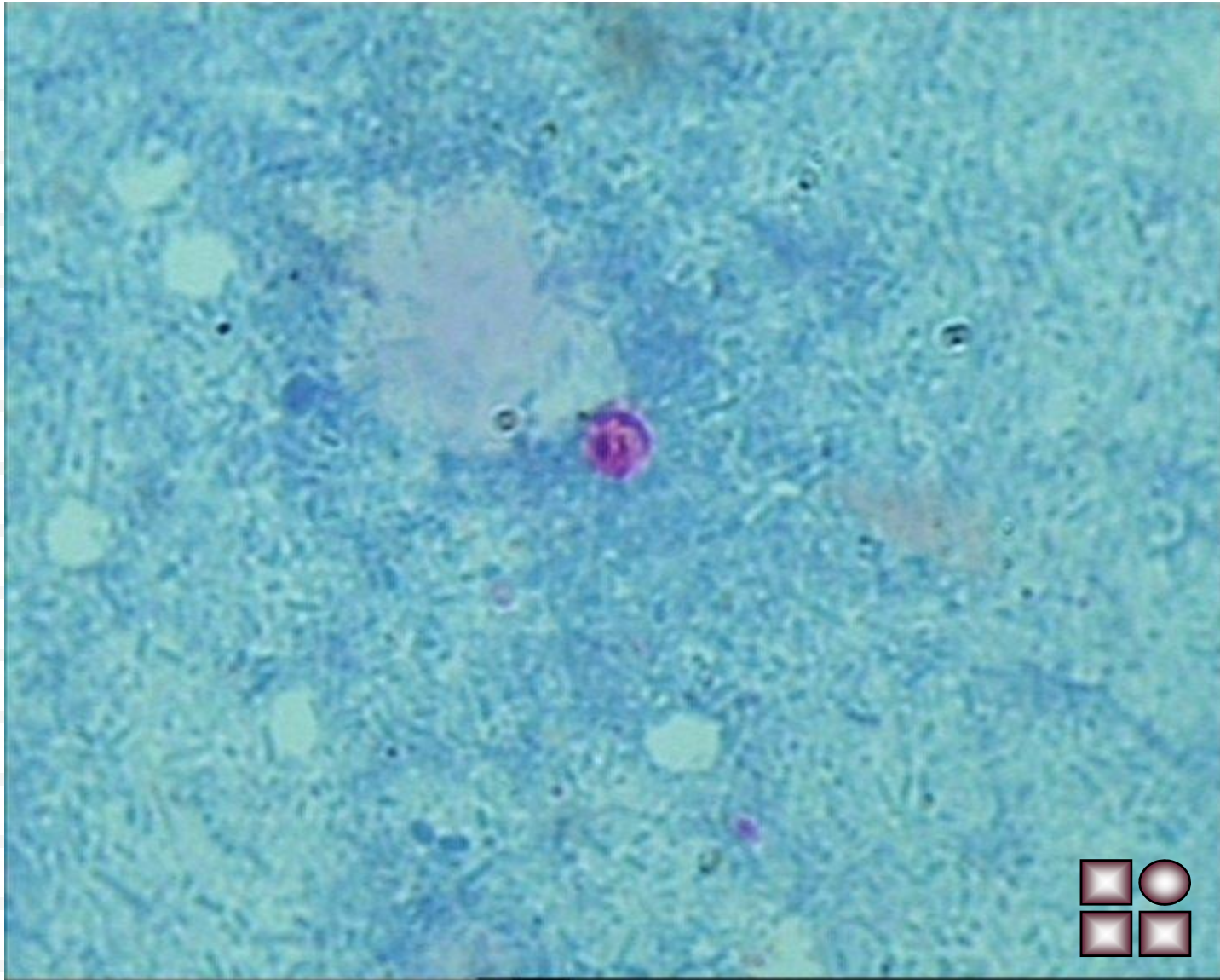
کریپتوسپوریڈیوم پارووم
ایزوسپورا بلی
سایکلوسپورا کایتنسیس
سارکوسیسٹیس


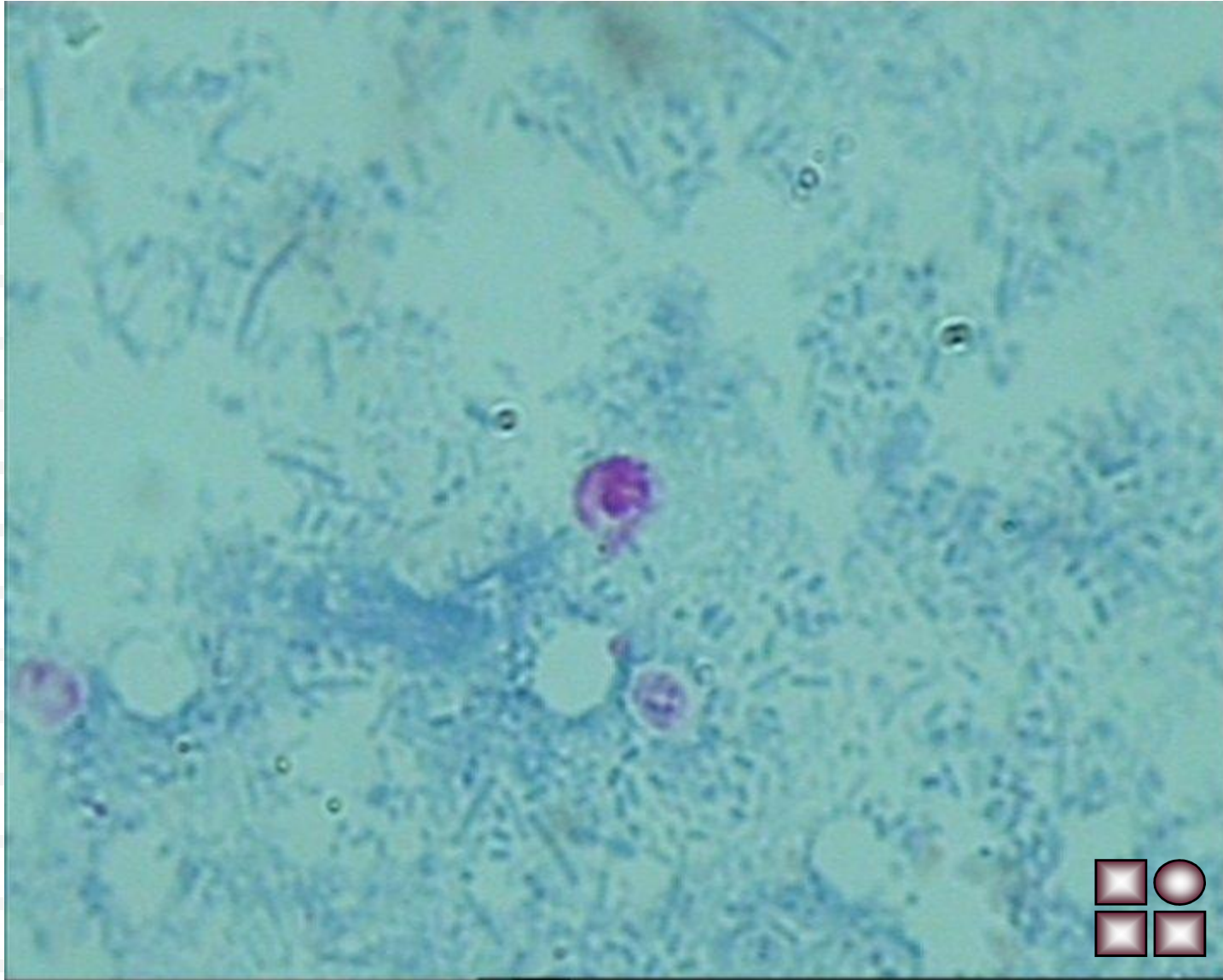


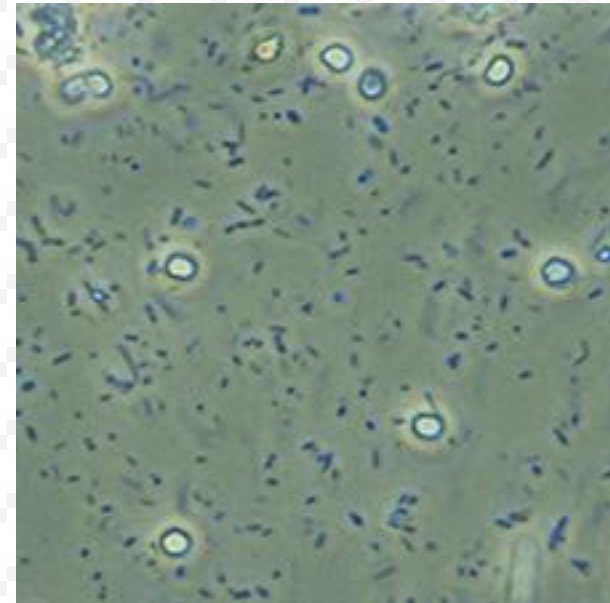
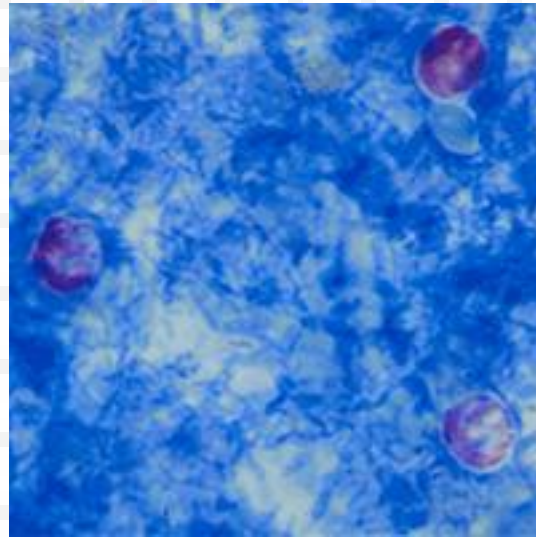


Oocysts of *Cryptosporidium parvum*



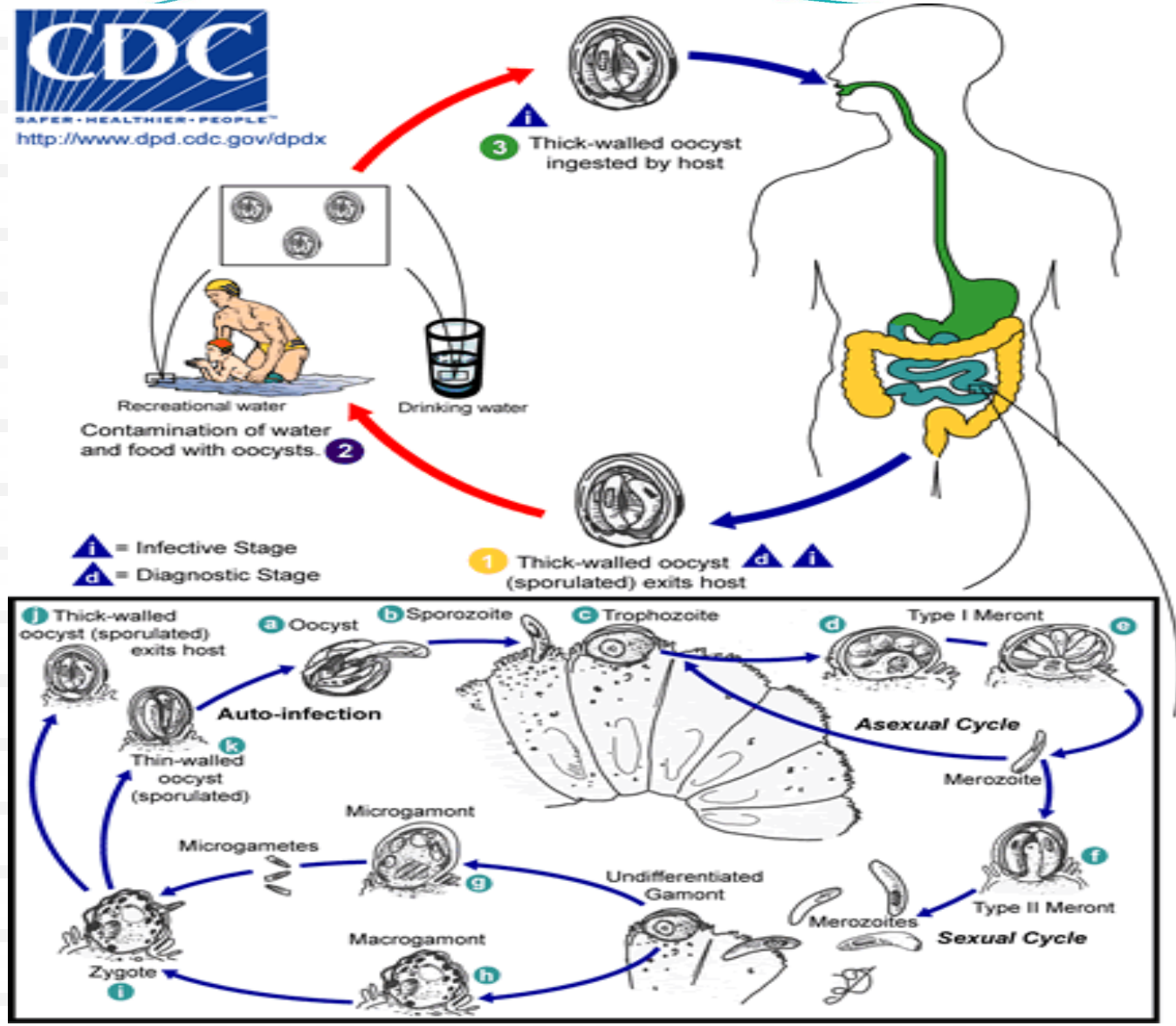




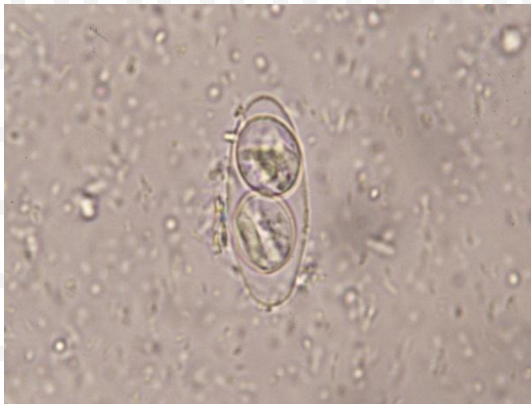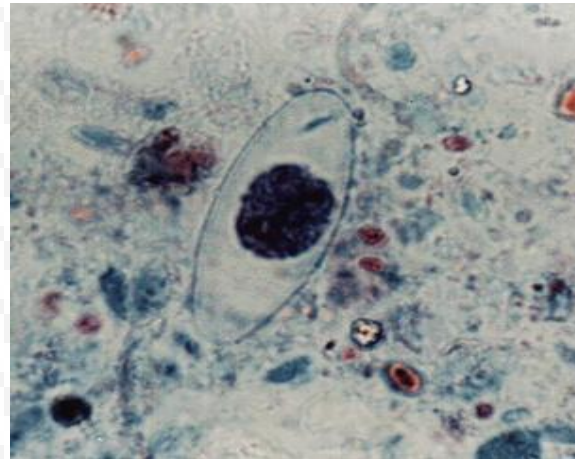
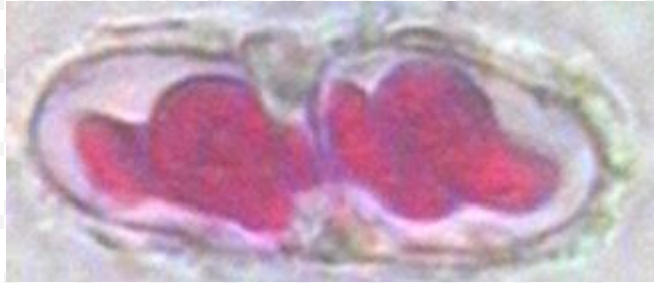




Life cycle of *C. parvum*



Isospora belli



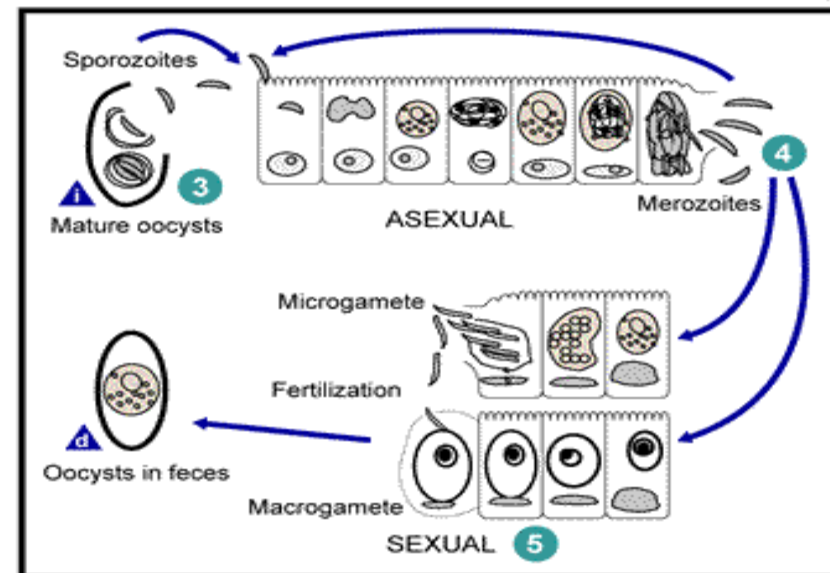
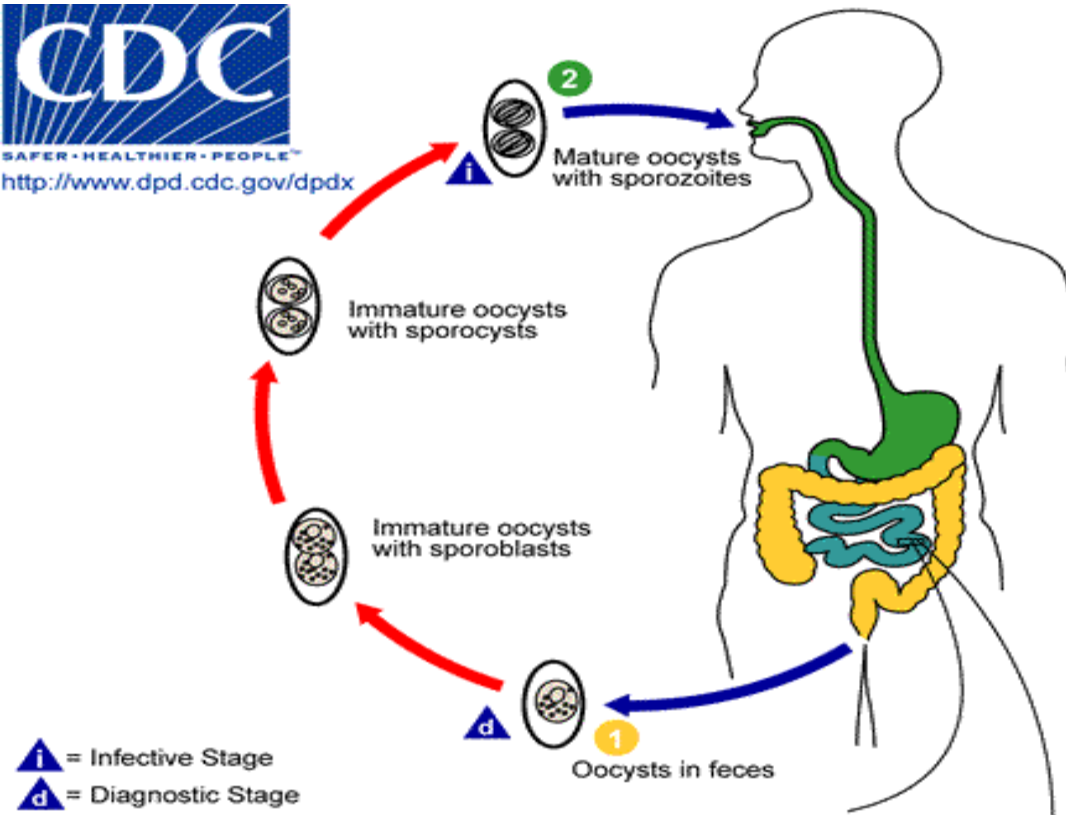


وزارت بهداشت، درمان و آموزش پزشکی

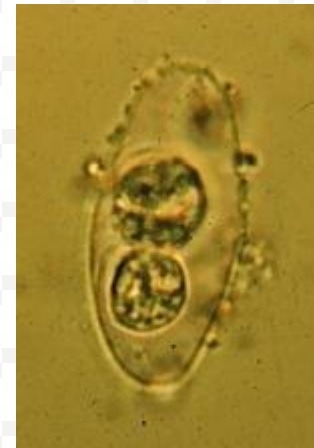
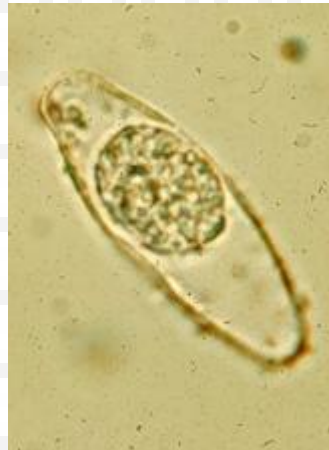
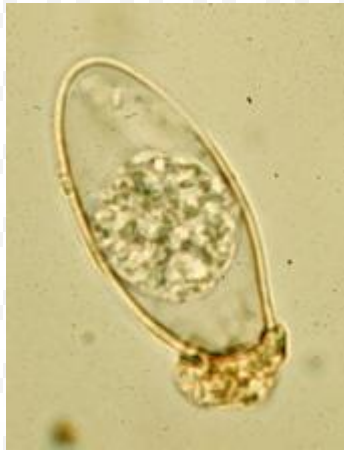<http://www.dpd.cdc.gov/dpdx>

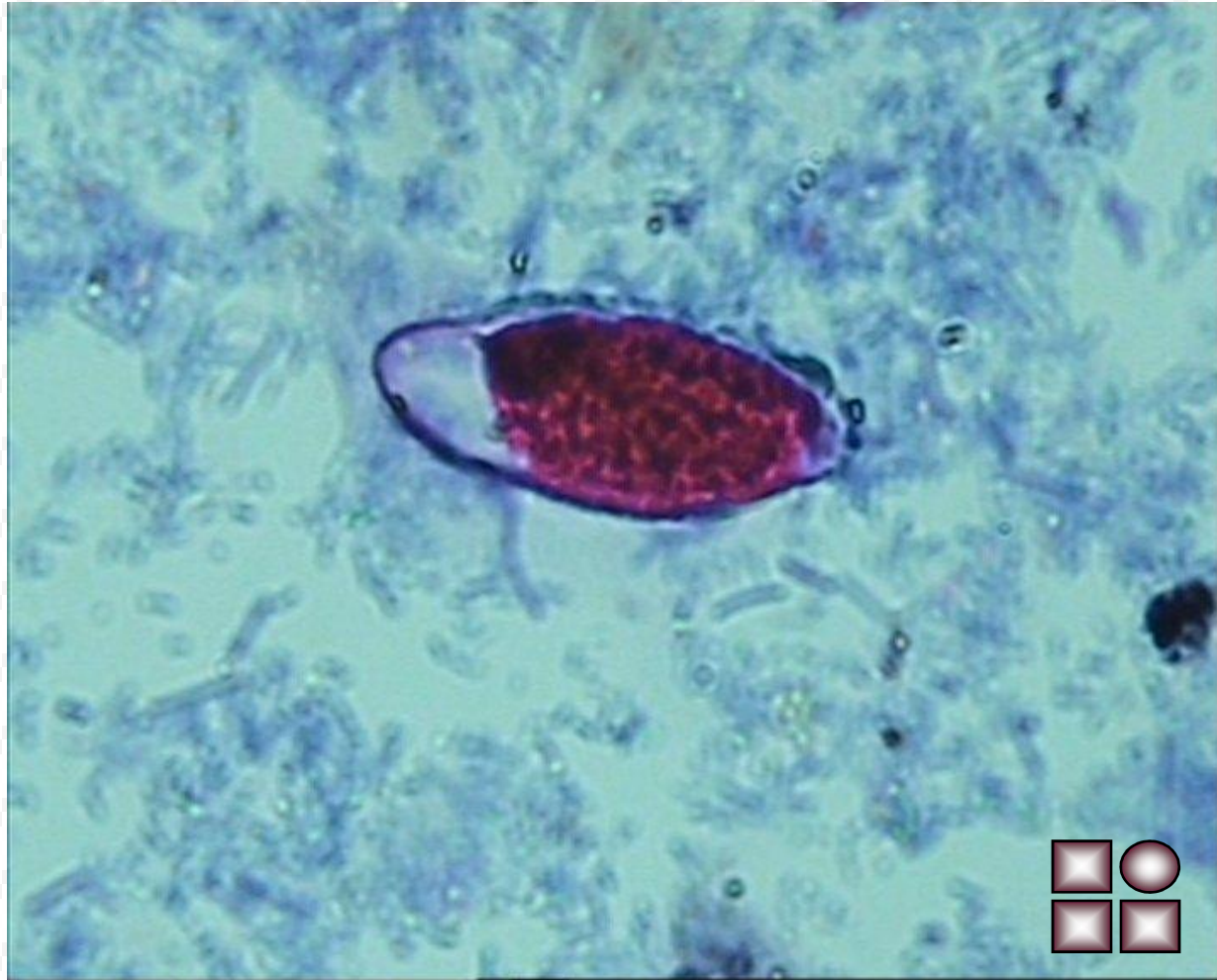
Life cycle of *Isospora belli*


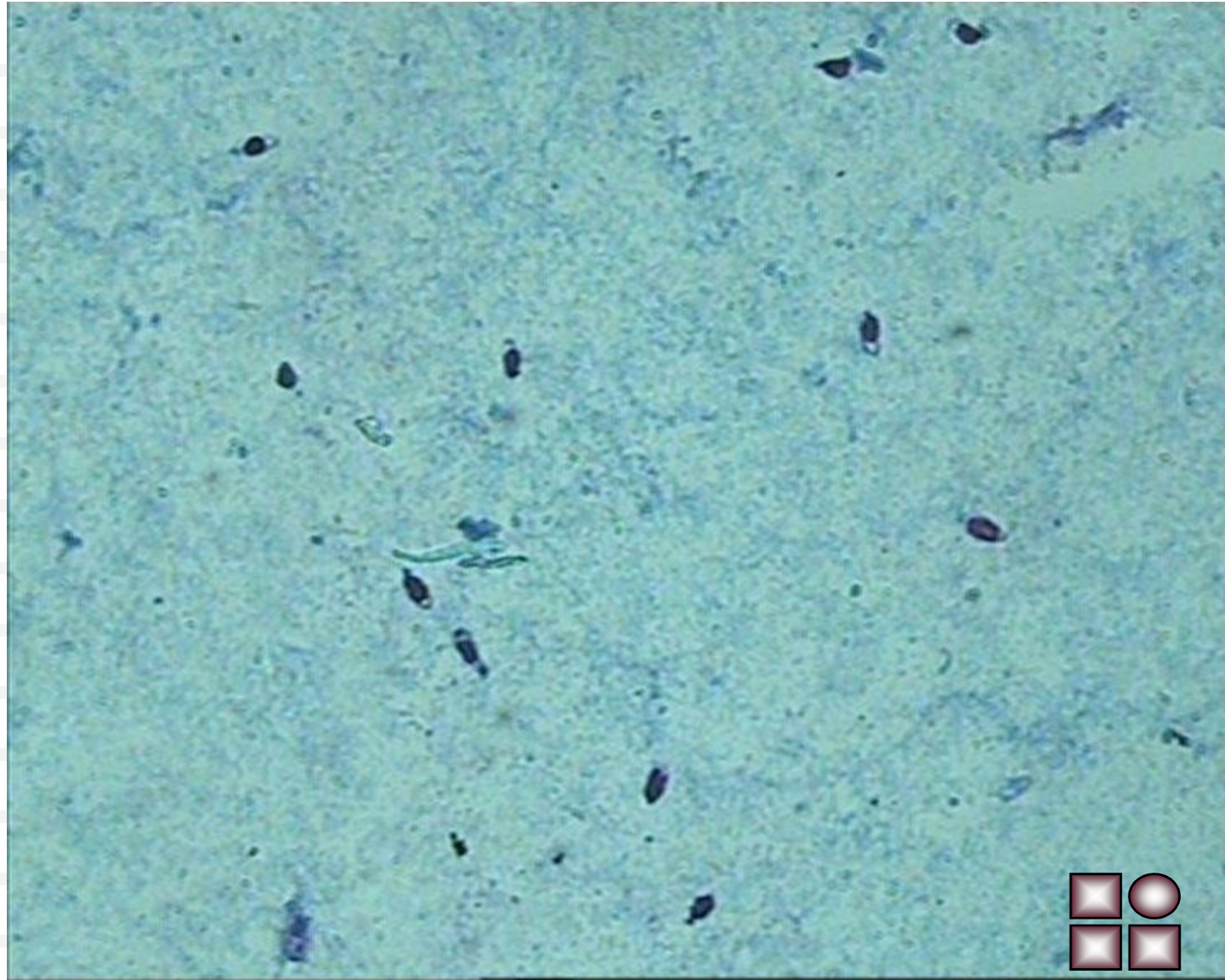



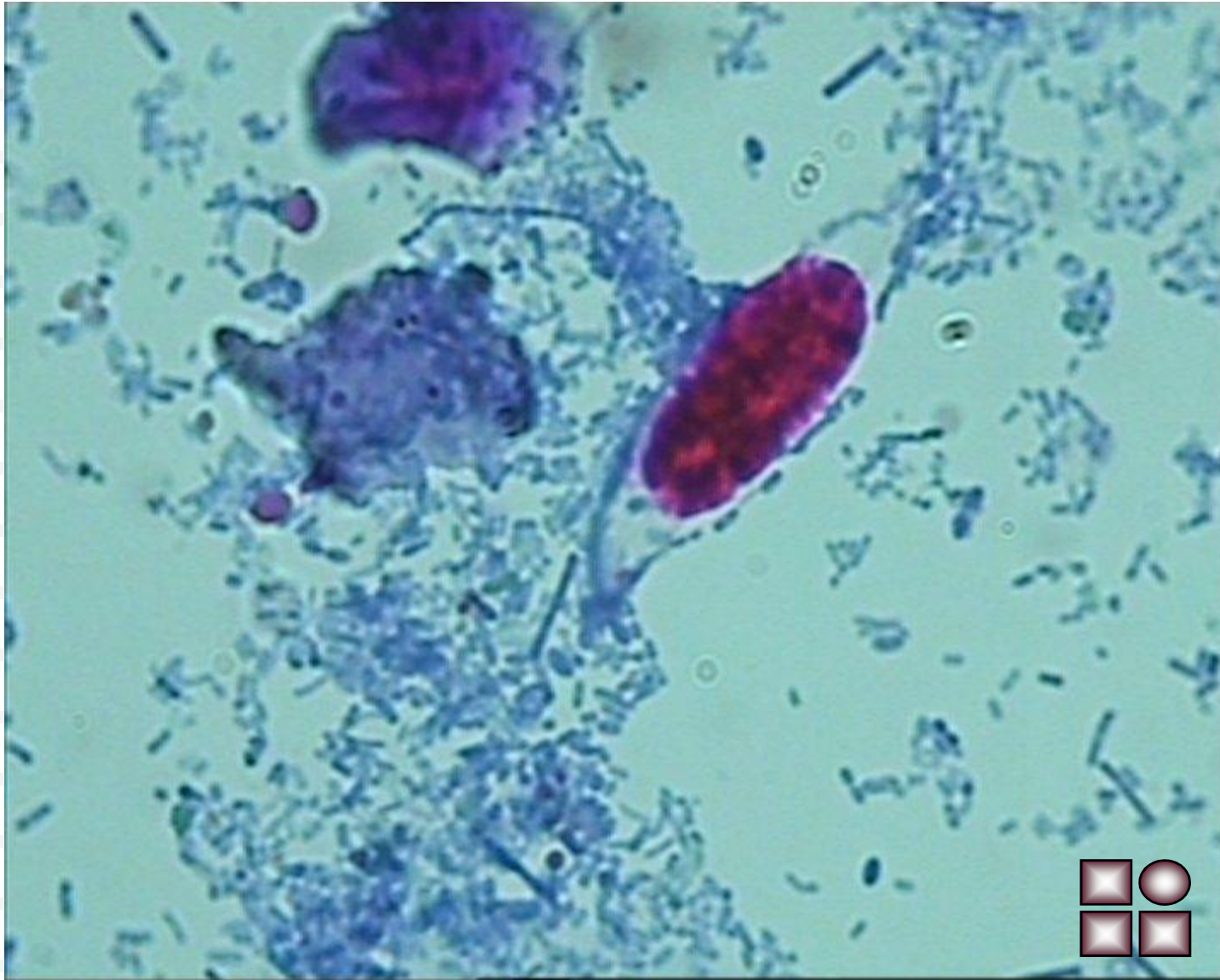
Oocysts of *Isospora belli*

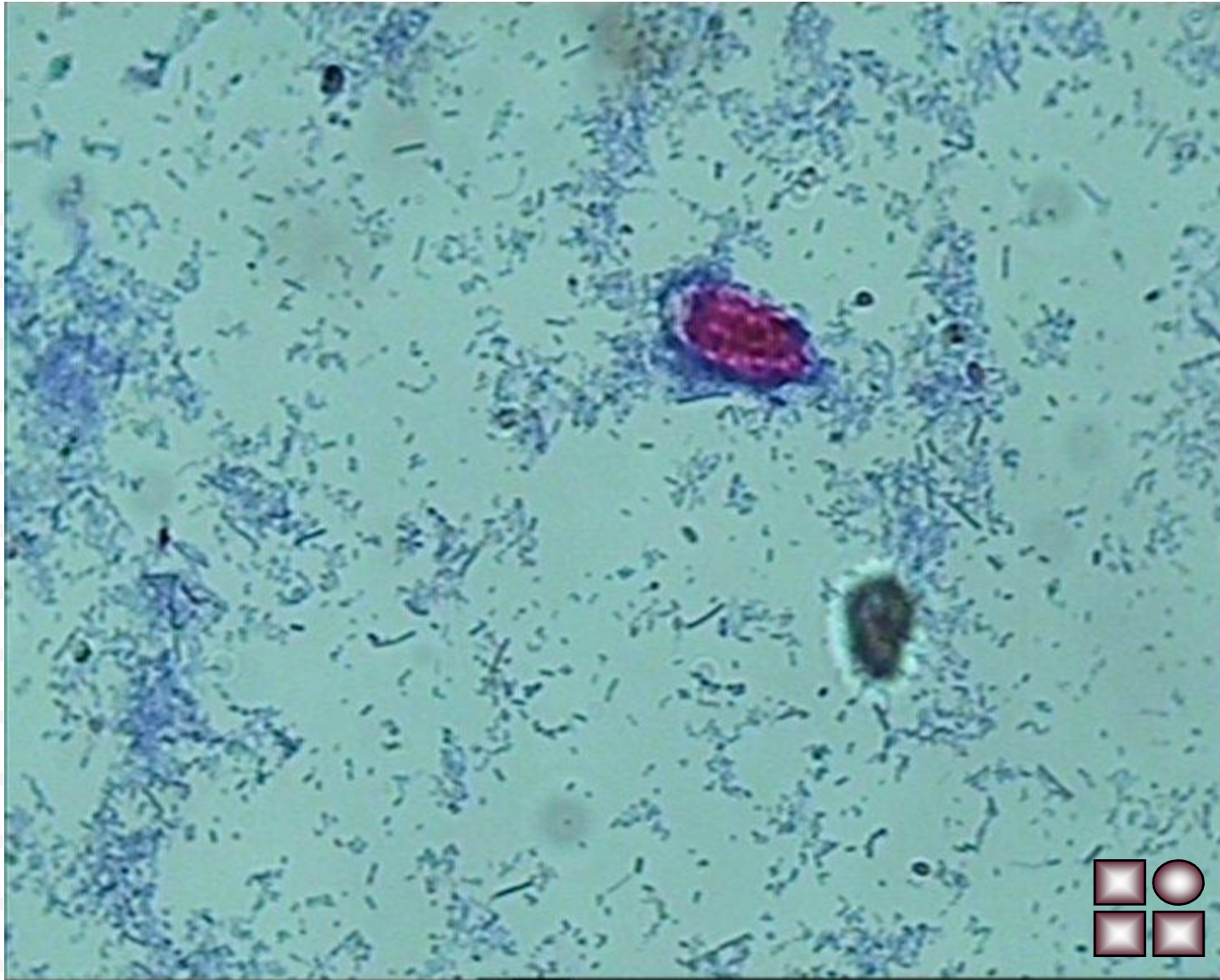


Oocysts of *Isospora belli*

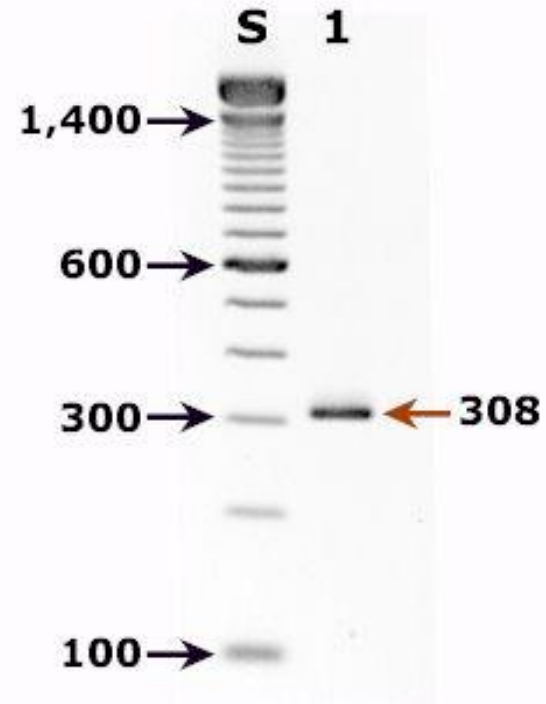
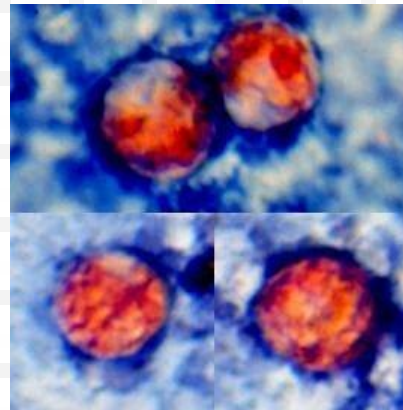
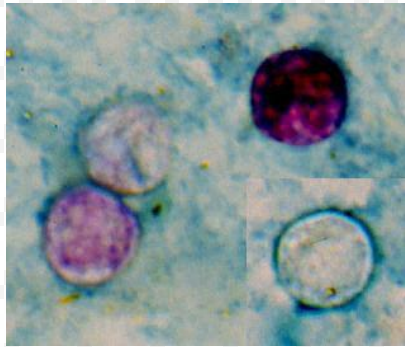



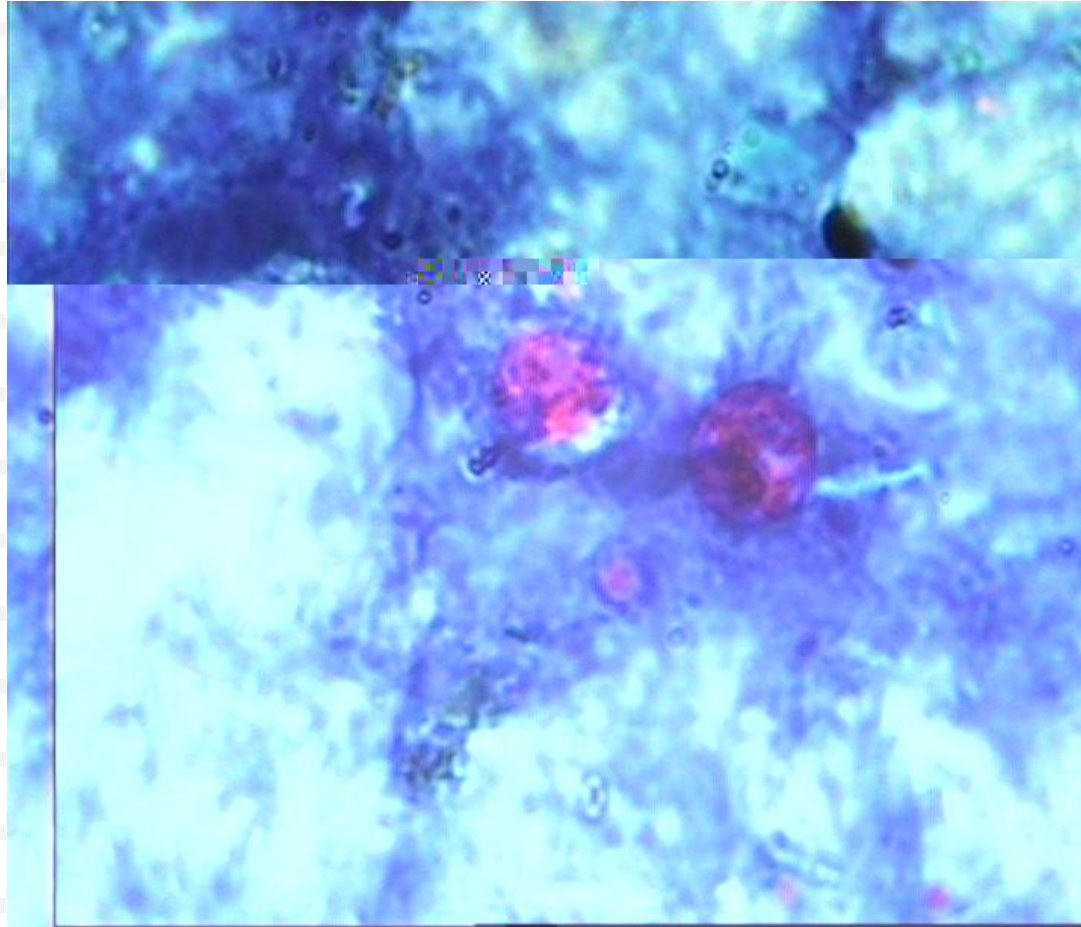

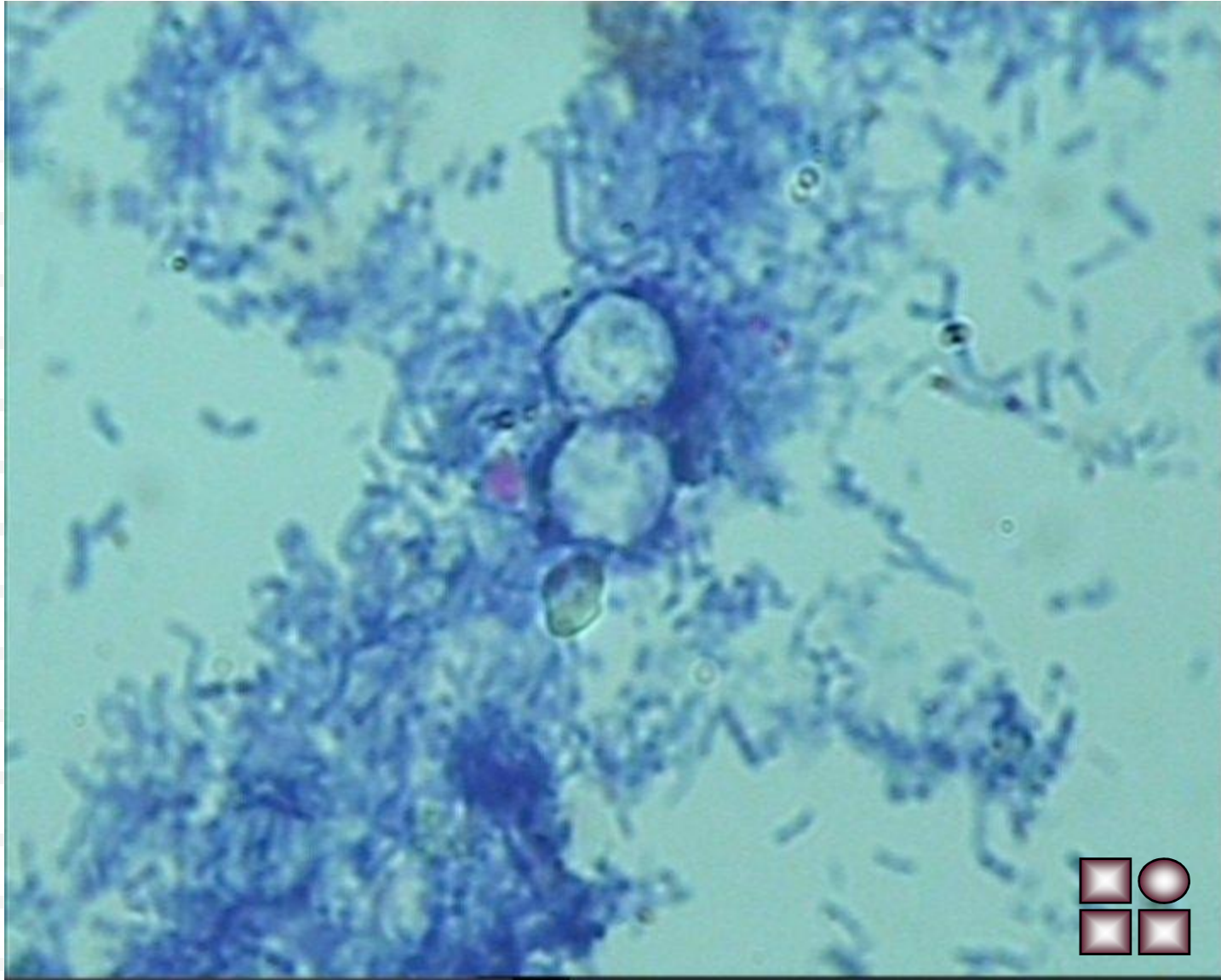



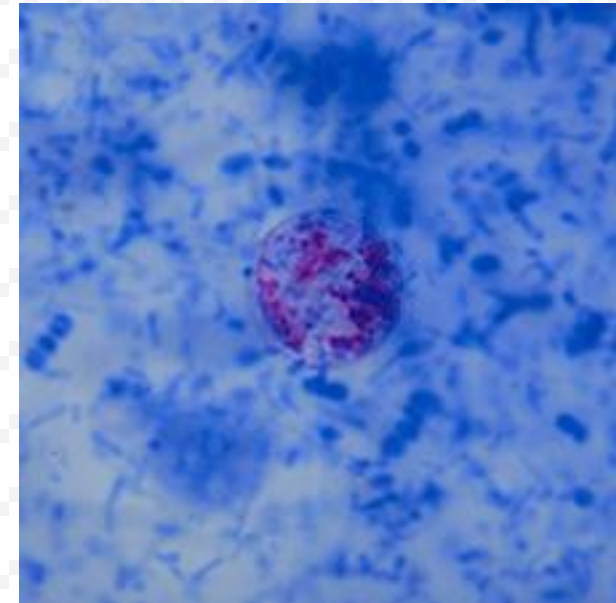
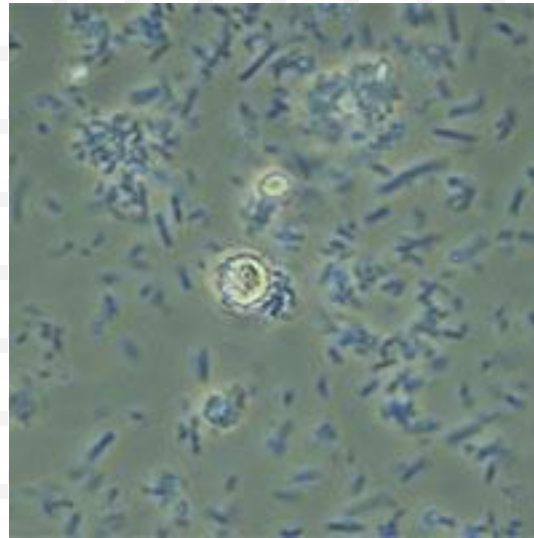
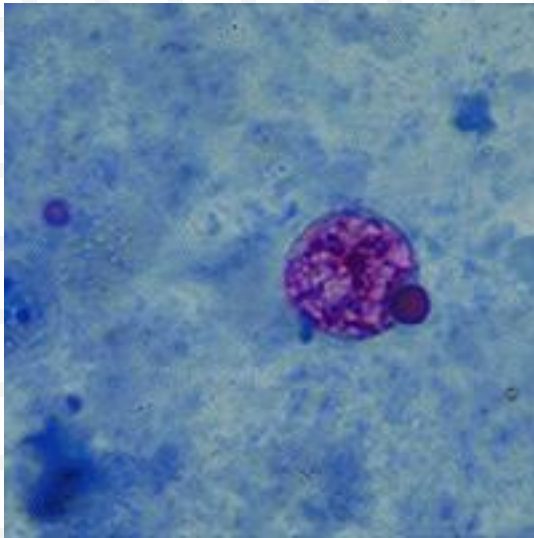


oocyst Of *Cyclospora*



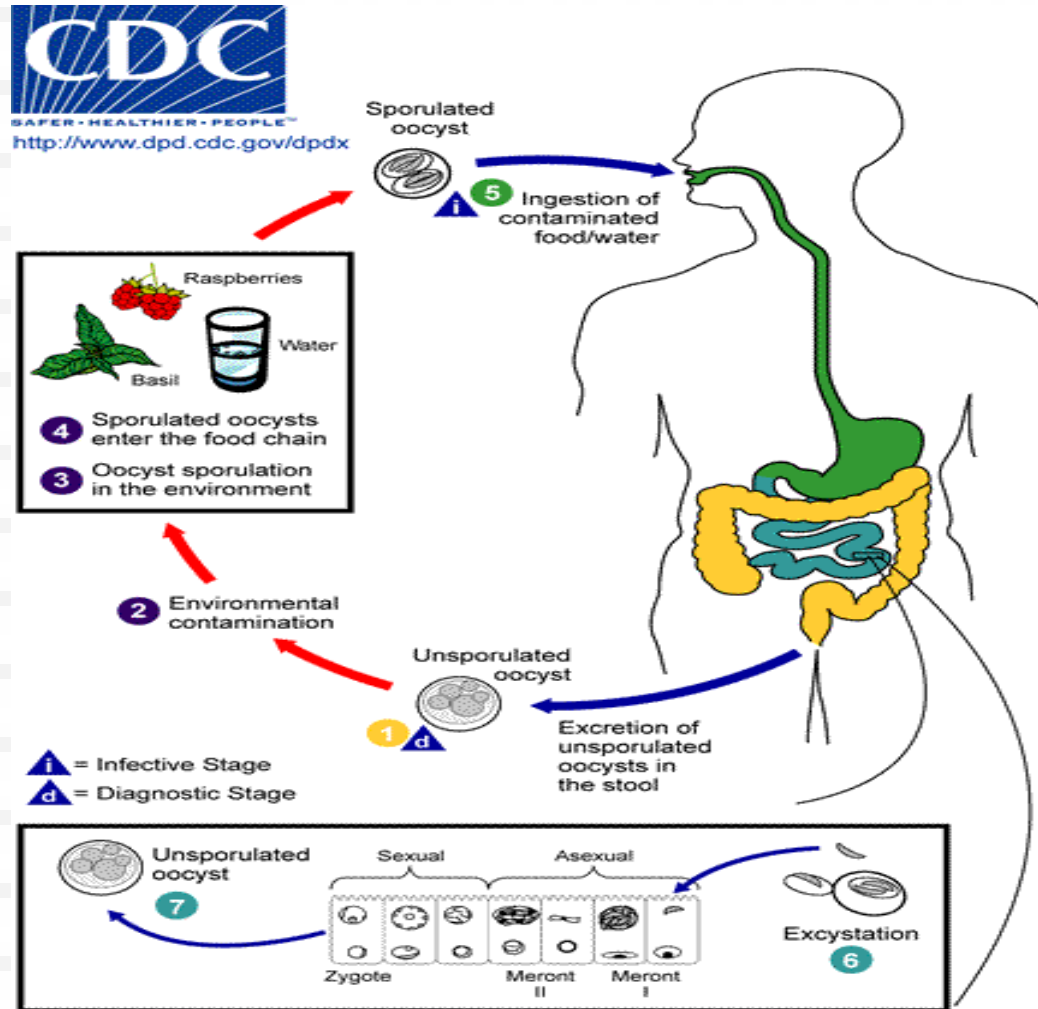








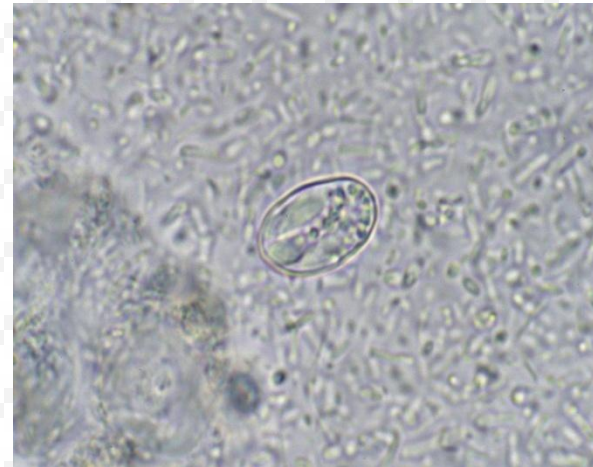
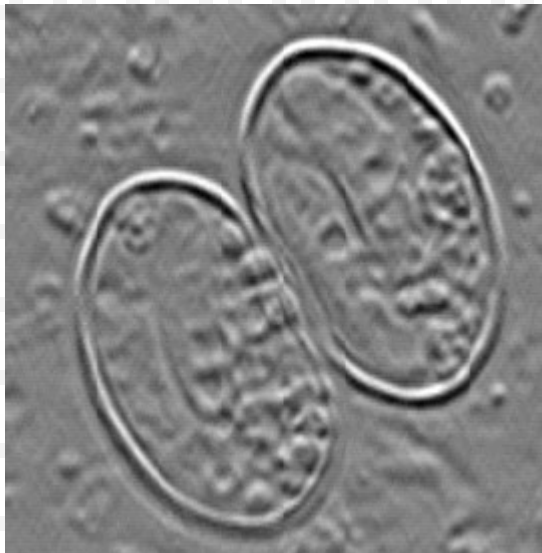Life cycle of *Cyclospora cayentanensis*



Sporulation of *Cyclospora* oocysts

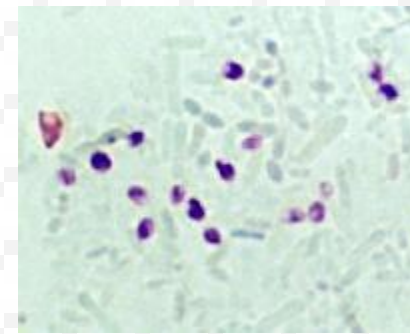
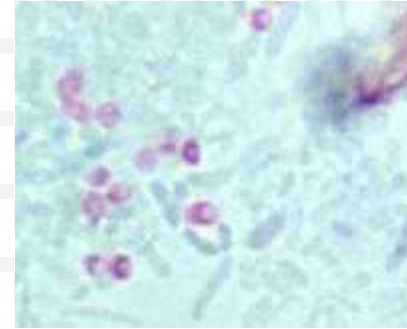
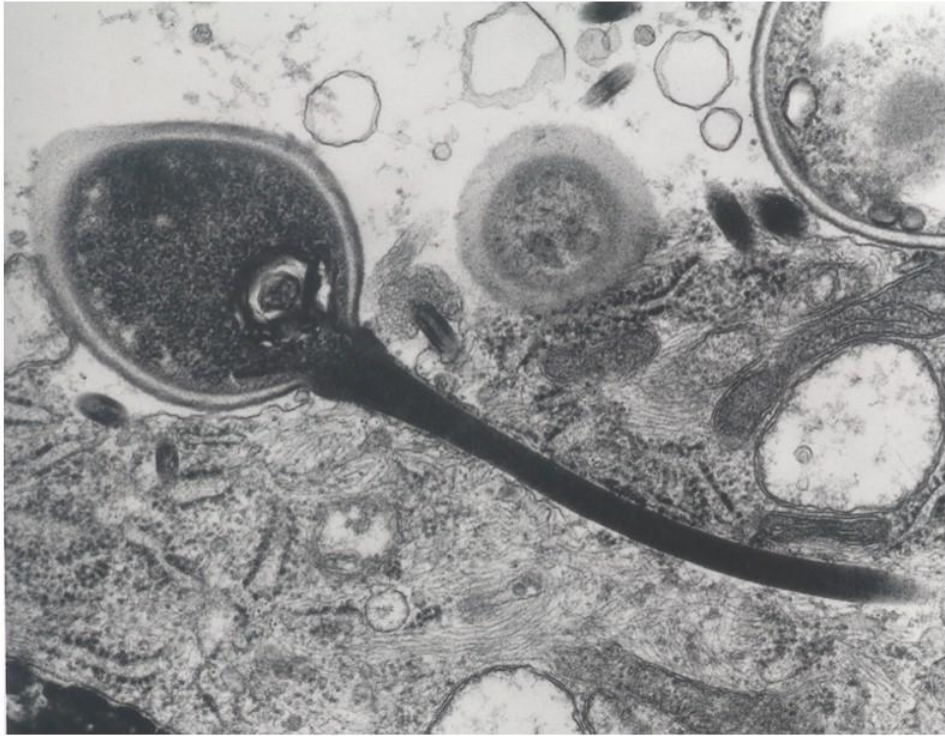


Carcocystis



میکروسپوریدیا

microsporidian spores



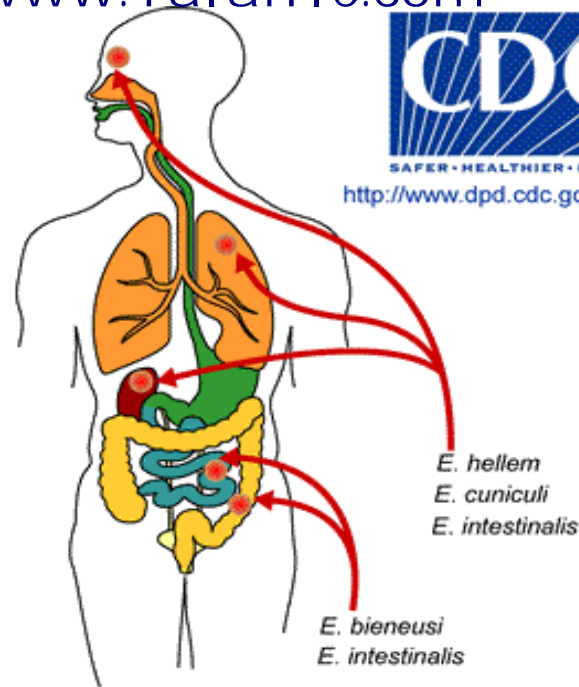


وزارت بهداشت
جمهوری اسلامی ایران

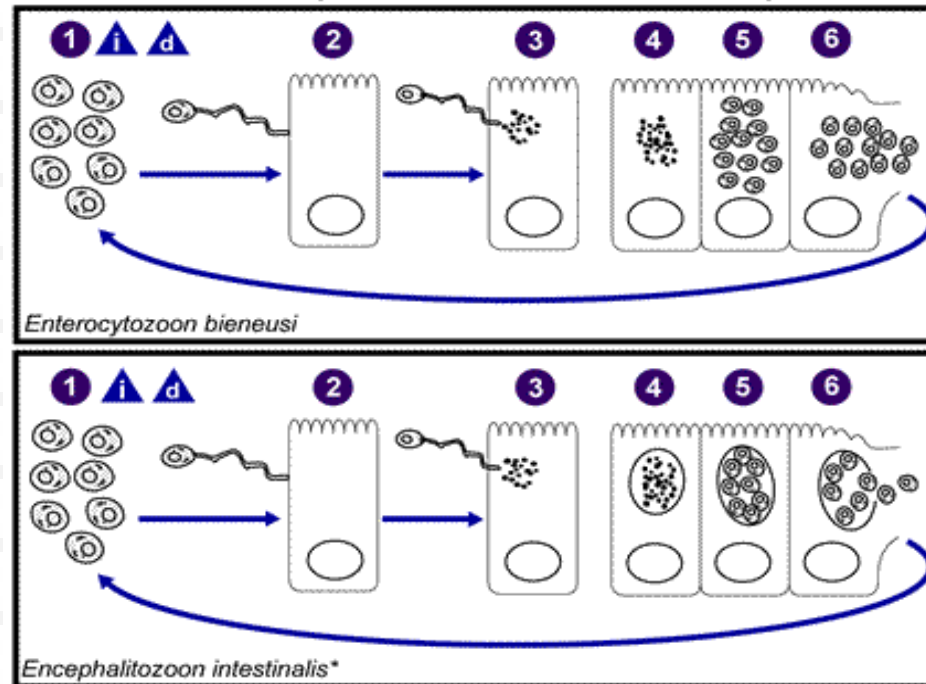
i = Infective Stage
d = Diagnostic Stage



<http://www.dpd.cdc.gov/dpdx>



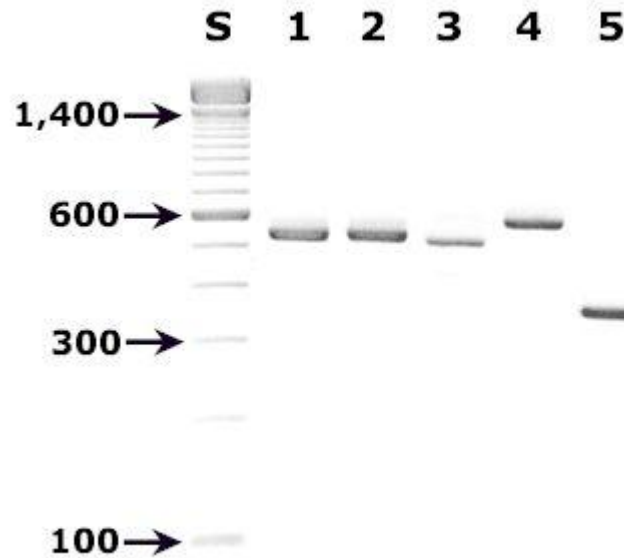
Intracellular development of *E. bienersi* and *E. intestinalis* spores.



*Development inside parasitophorous vacuole also occurs in *E. hellem* and *E. cuniculi*.



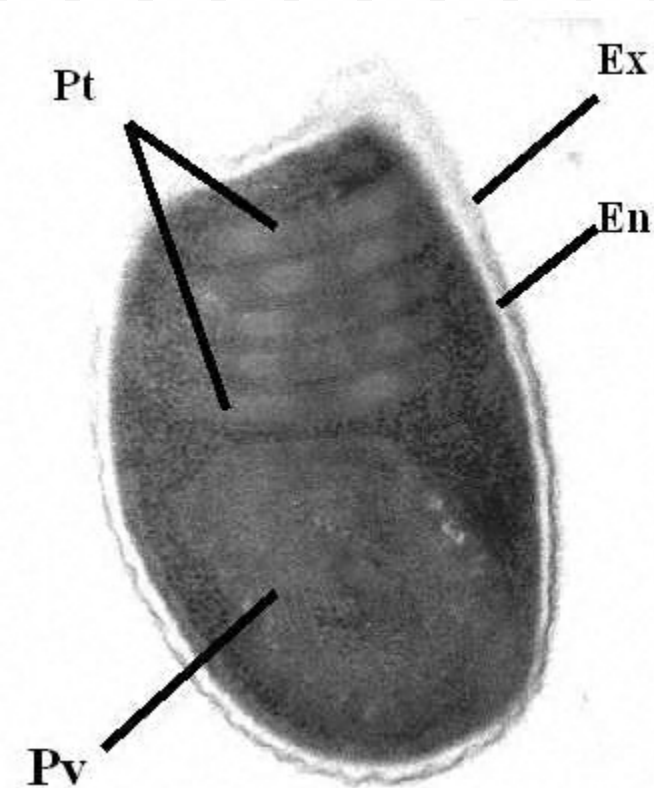
Agarose gel (2%) showing the diagnostic bands for species-specific PCR diagnostic primers designed for microsporidia that infect humans .





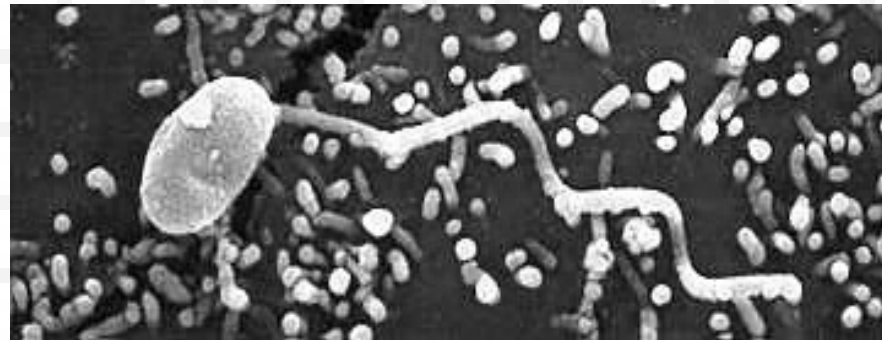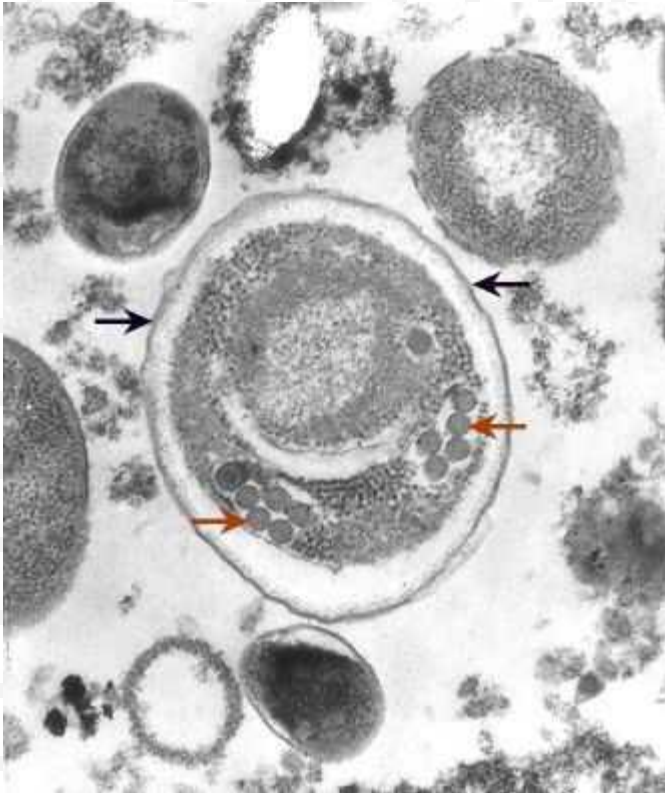Transmission electron micrograph showing ultrastructural features of a mature microsporidian spores

- .
- **Legend :**
 - Pt** :Portion of coiled polar tubule
 - Ex** :Electron dense exospore
 - En** :Electron lucent endospore
 - Pv** :Posterior vacuole
-





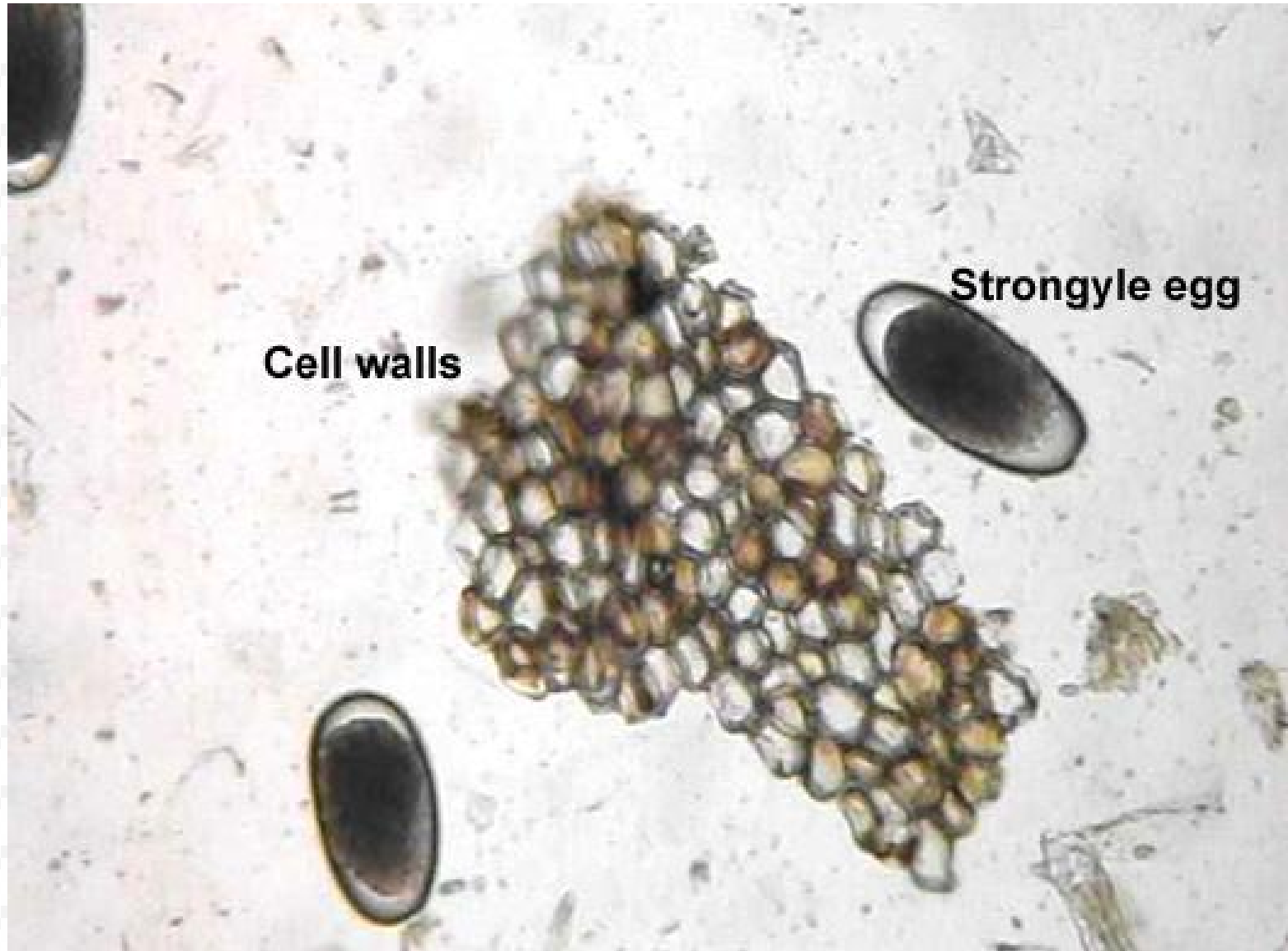
Scanning electron micrograph of a microsporidian spore with an extruded polar tubule inserted into a eukaryotic cell. The spore injects the infective sporoplasms through its polar tubule.

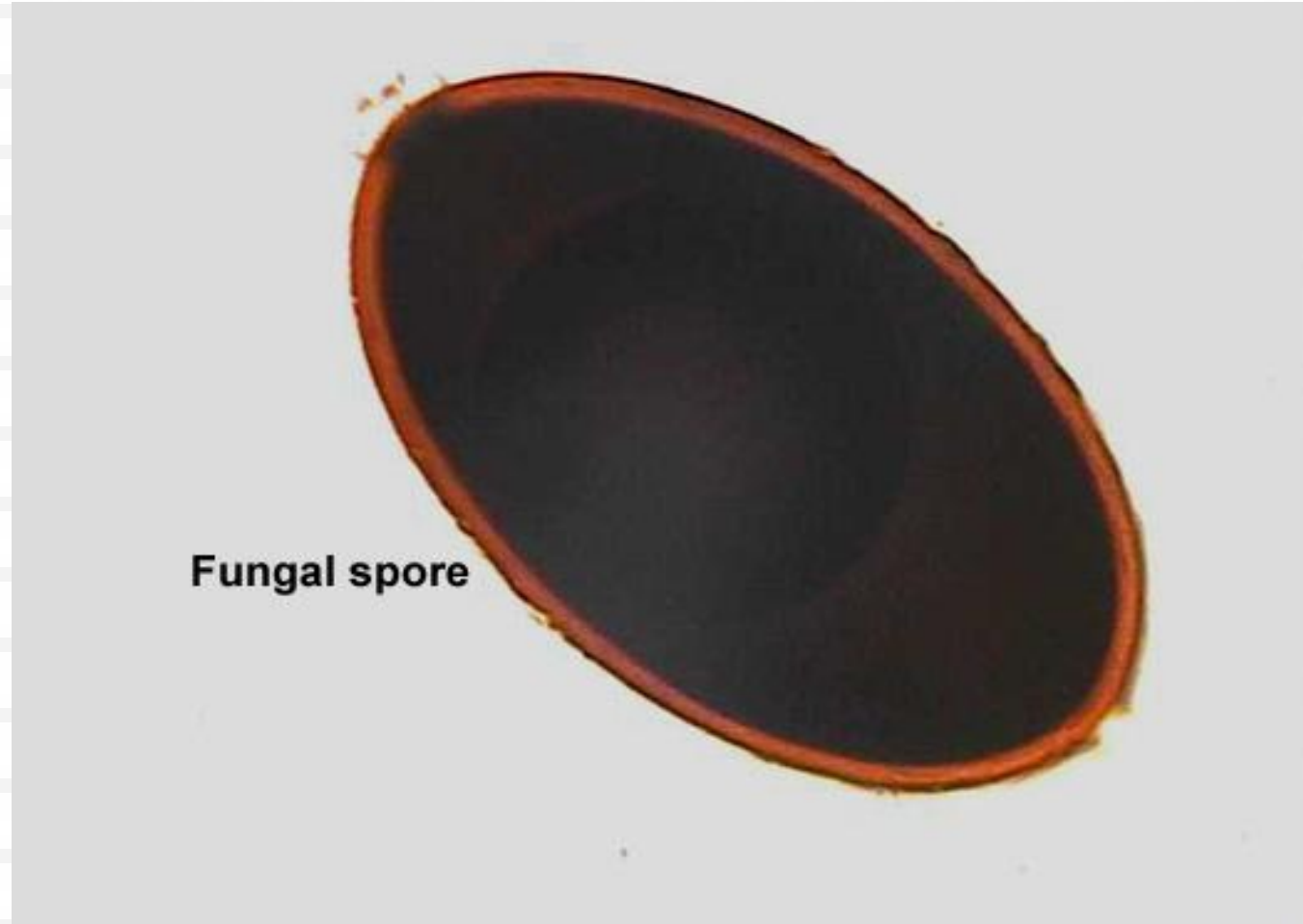


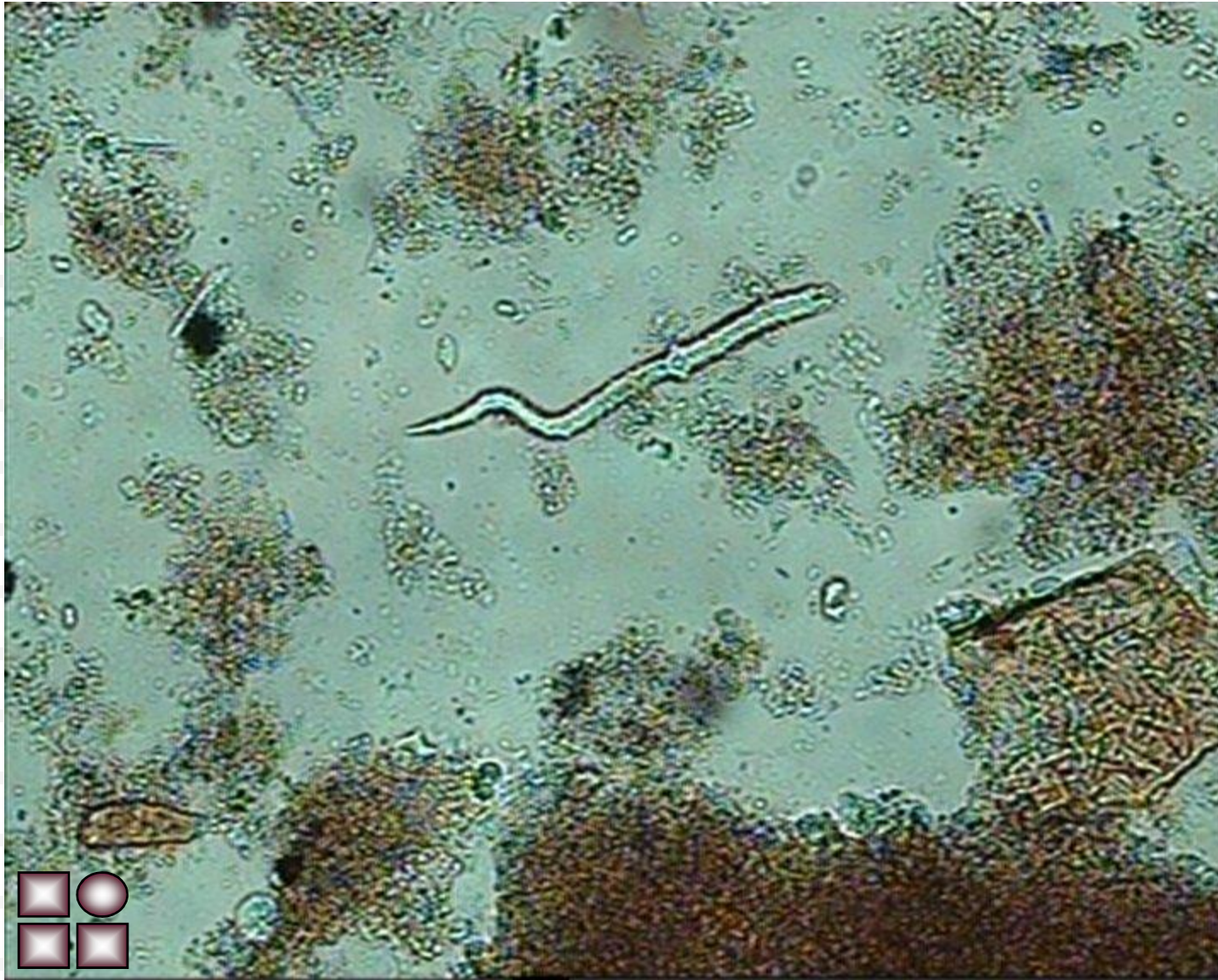


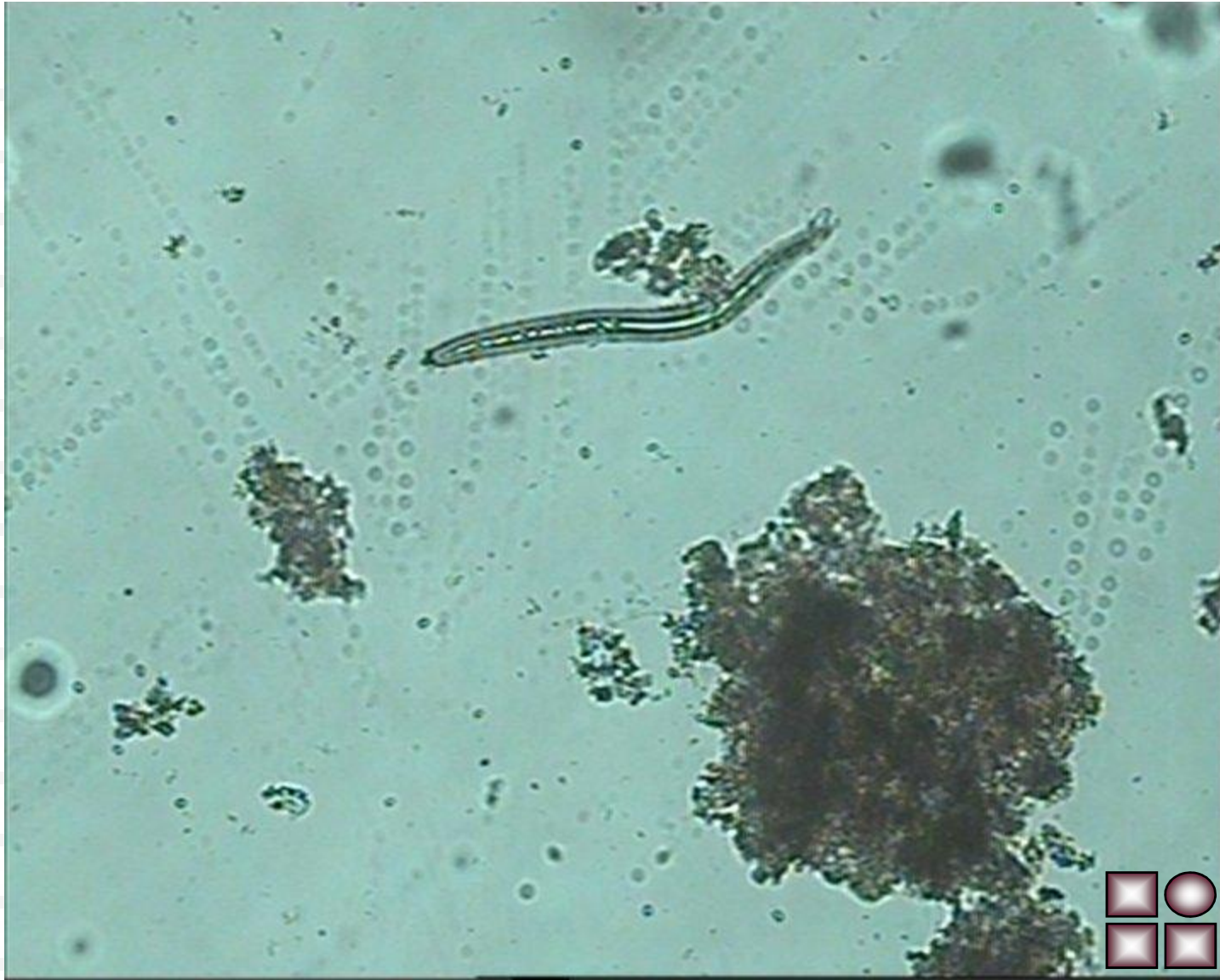Artifacts

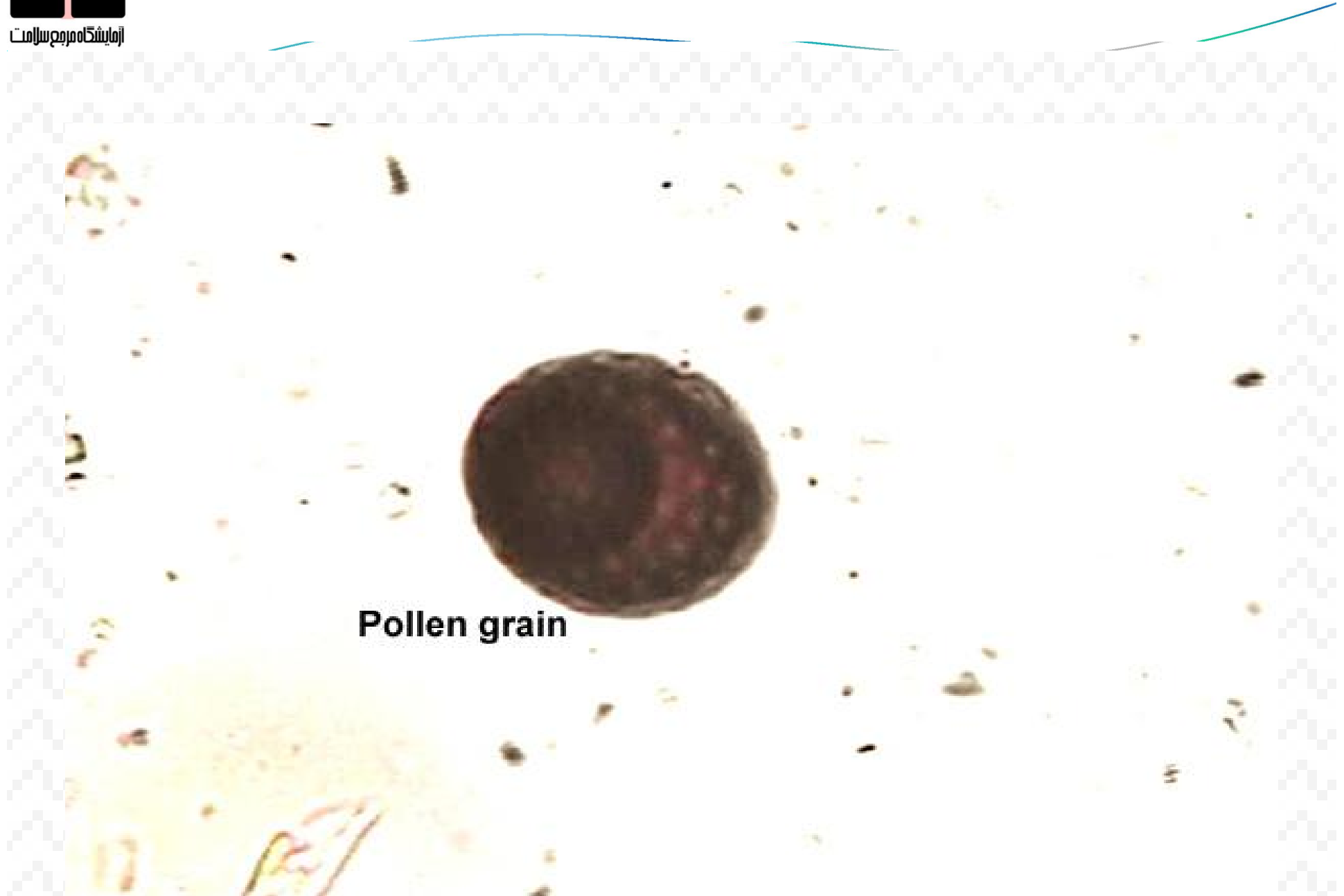عناصر مشابه انگلها



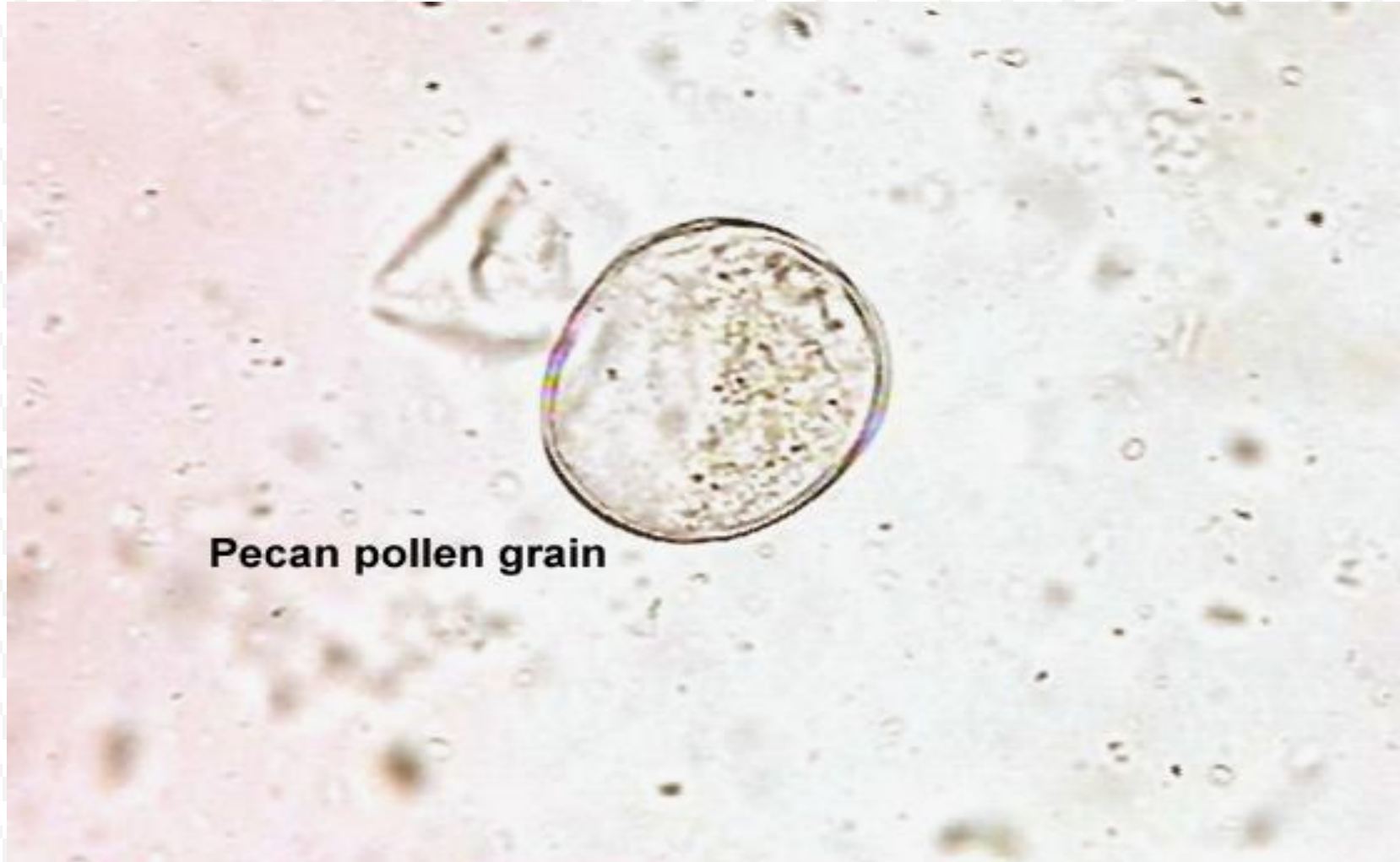


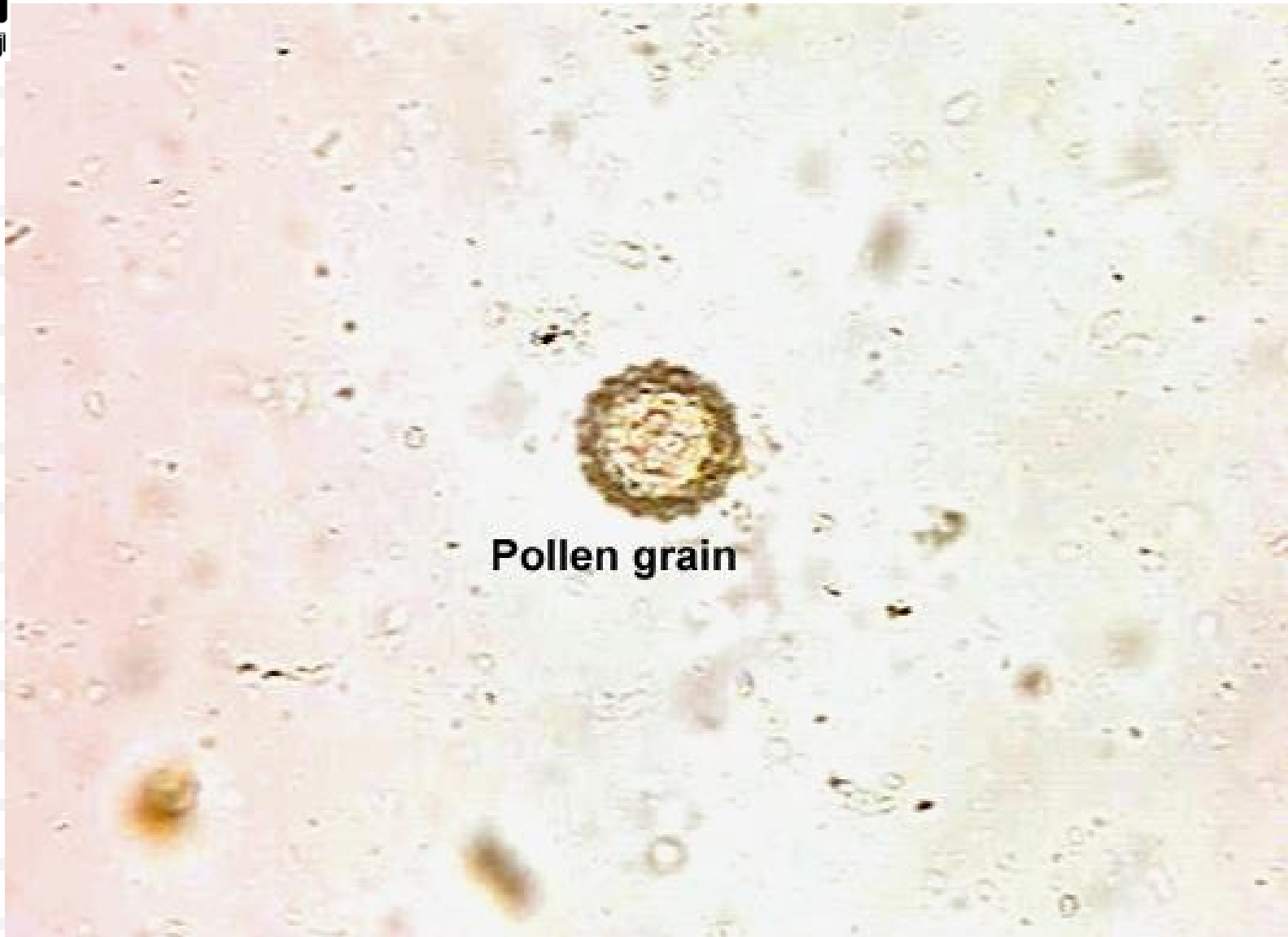
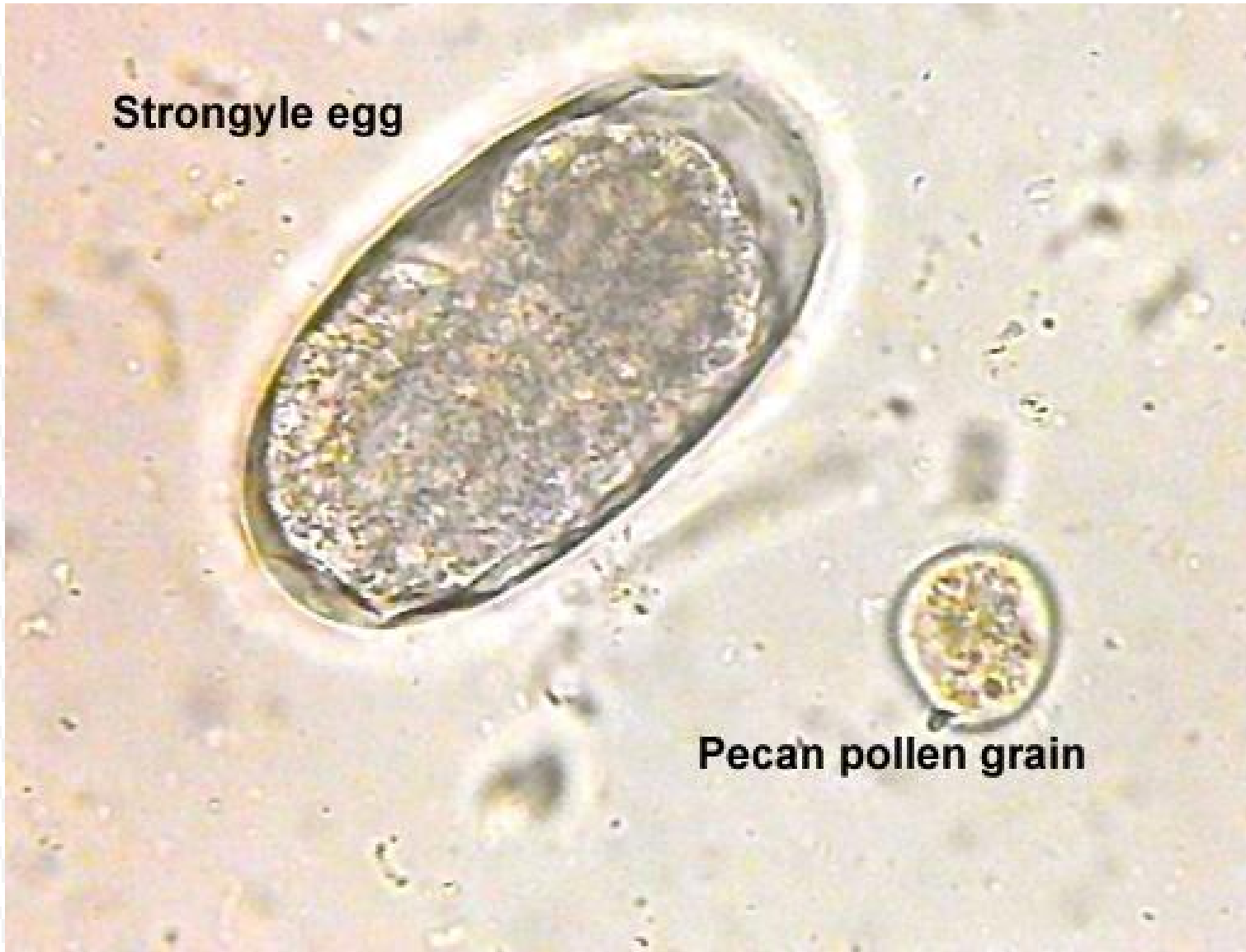




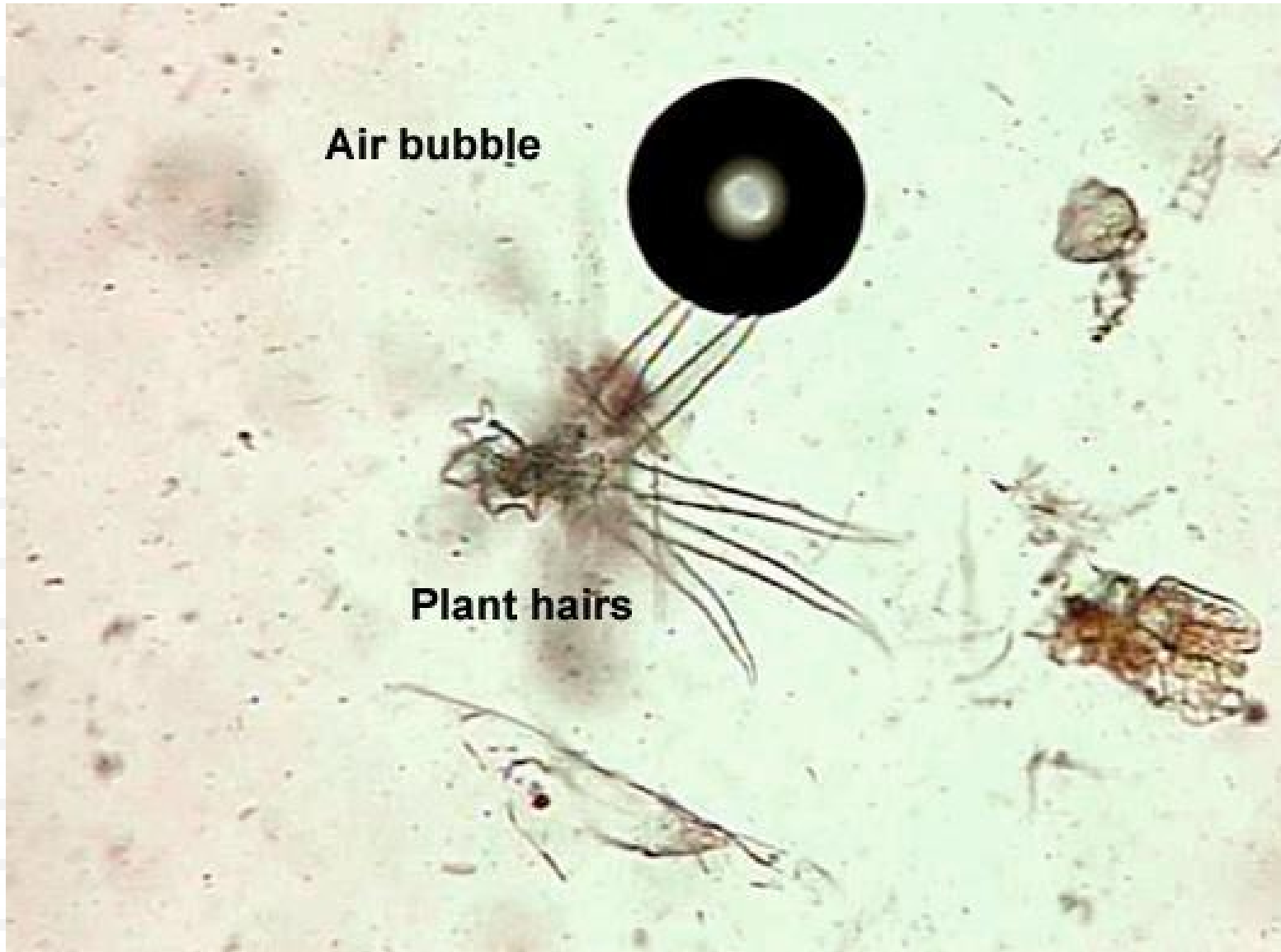
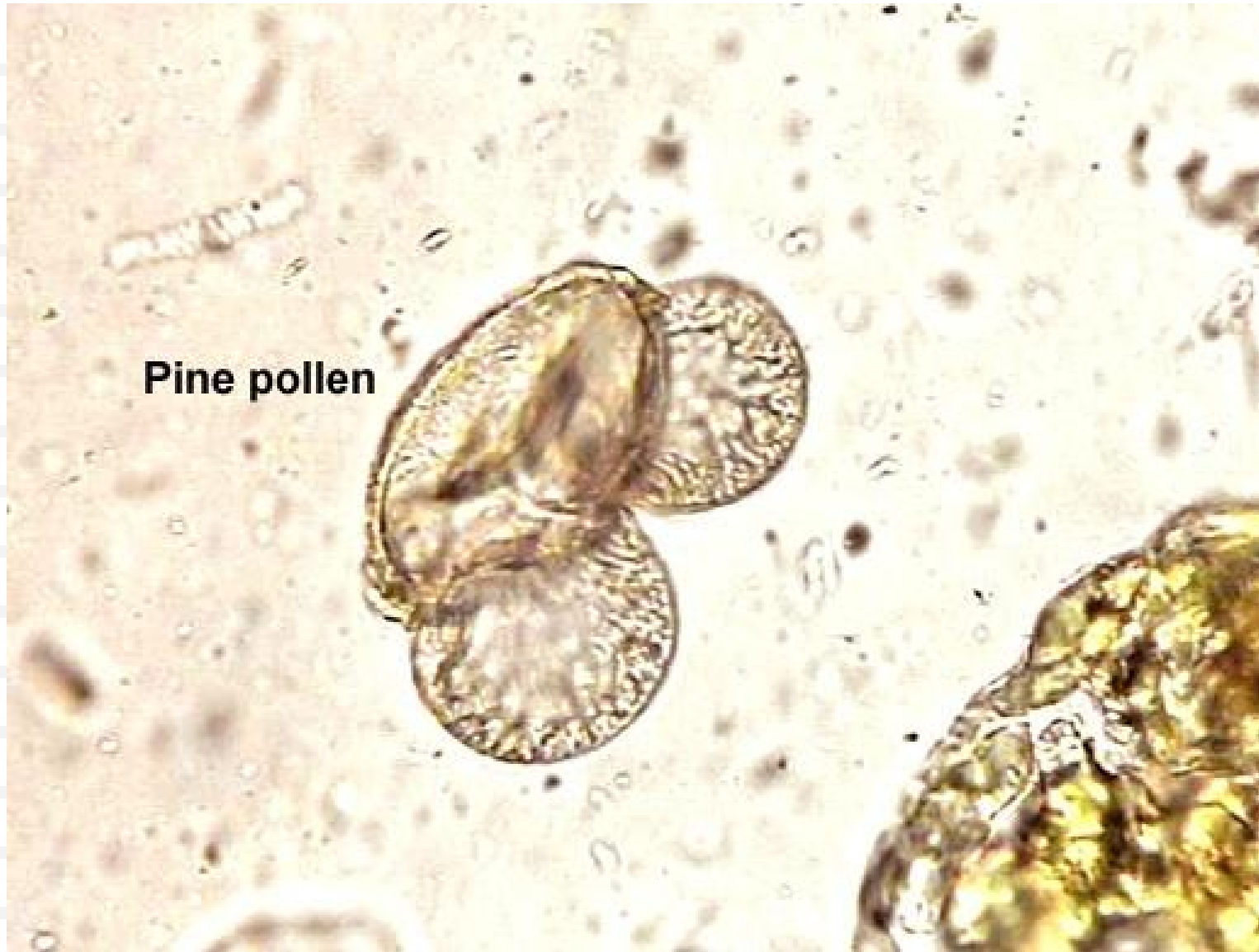Pollen grain

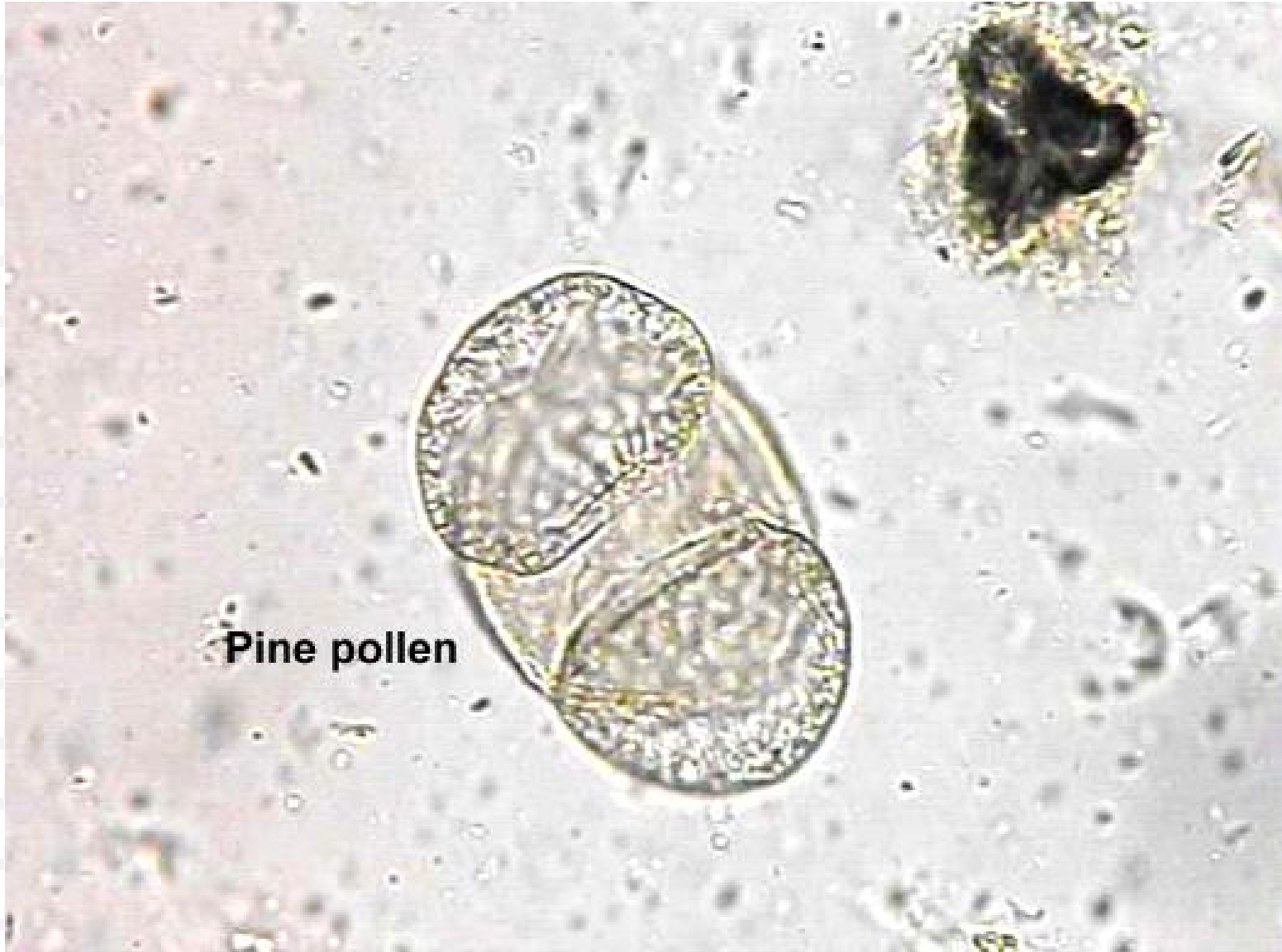




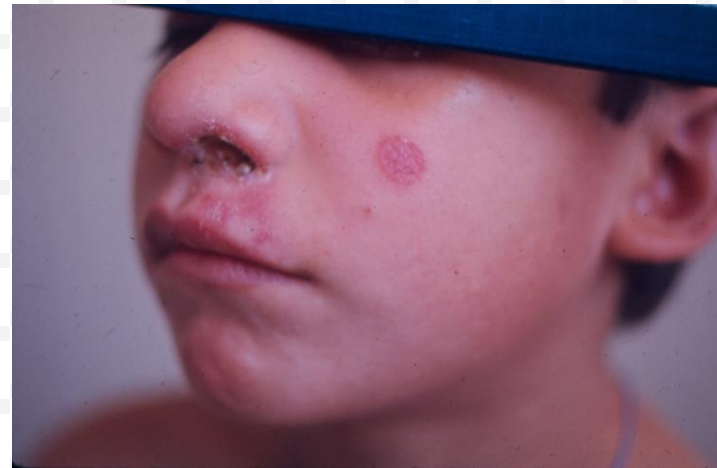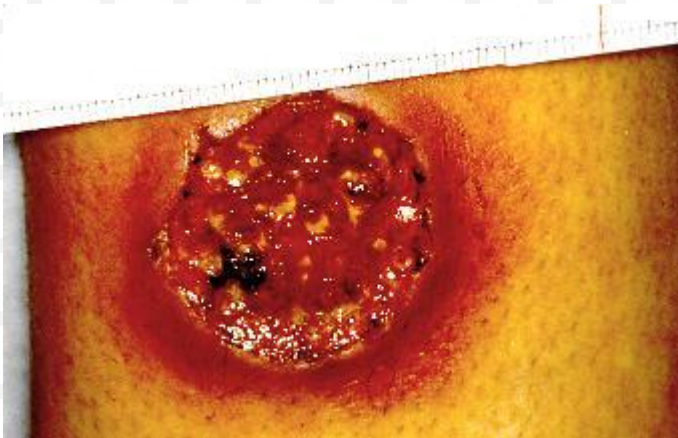
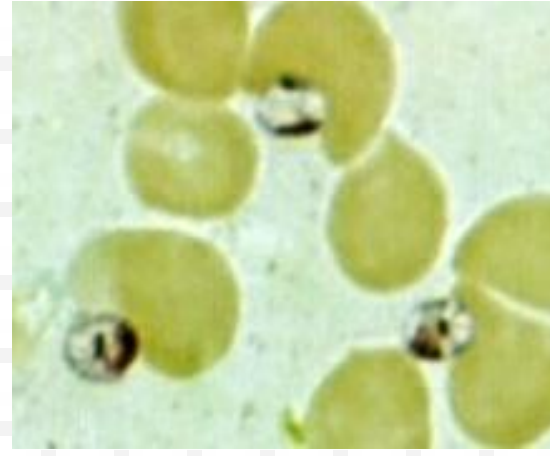
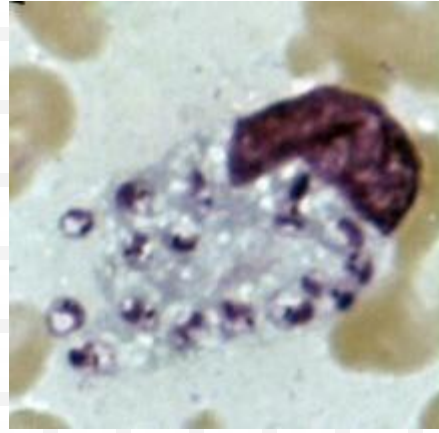
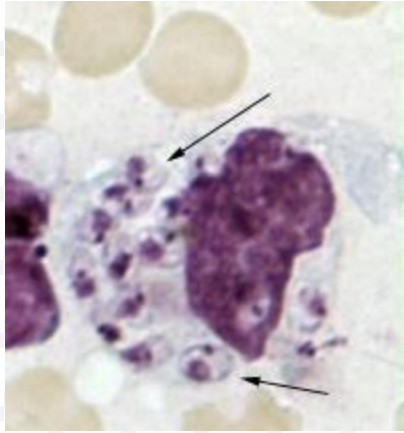






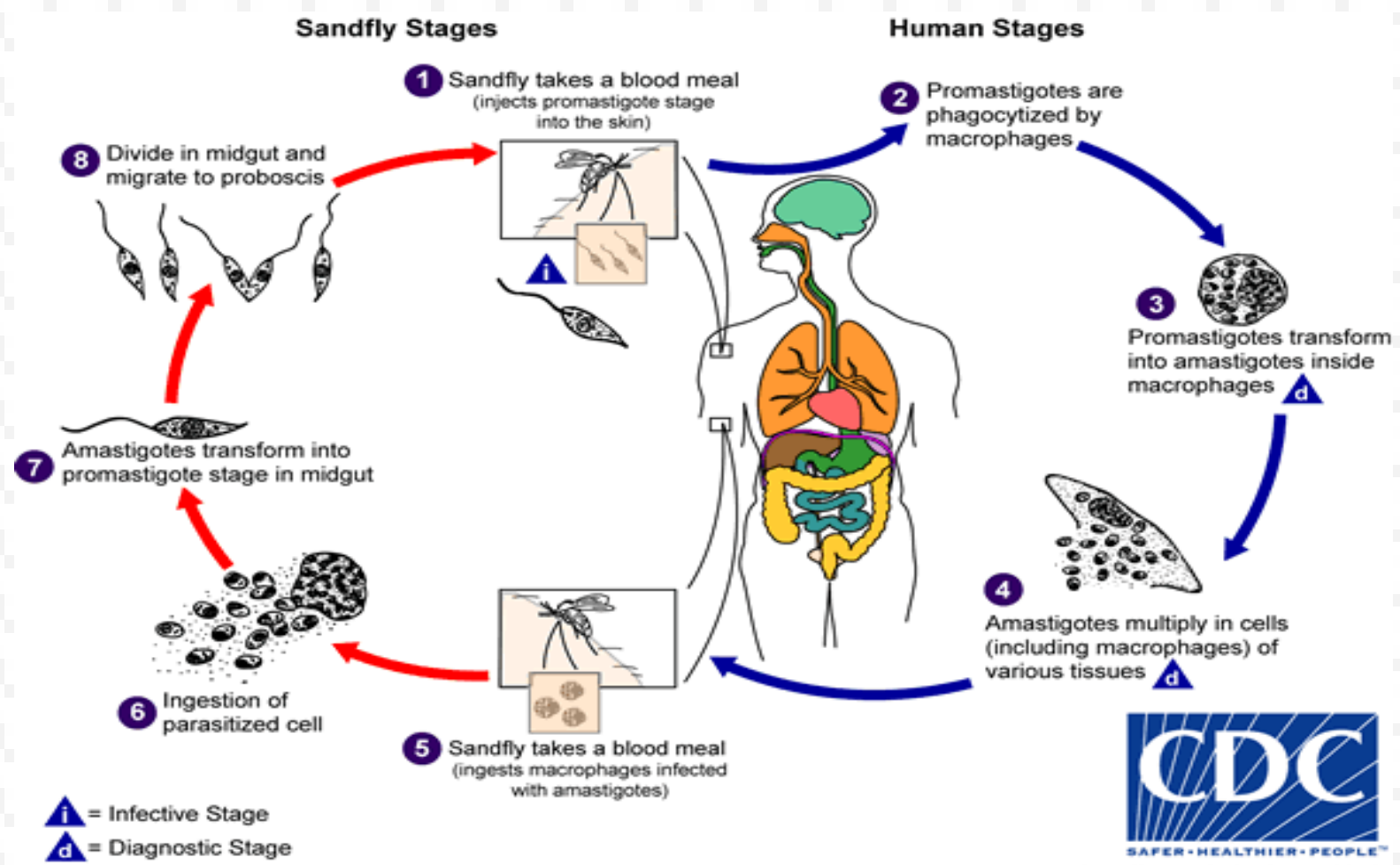


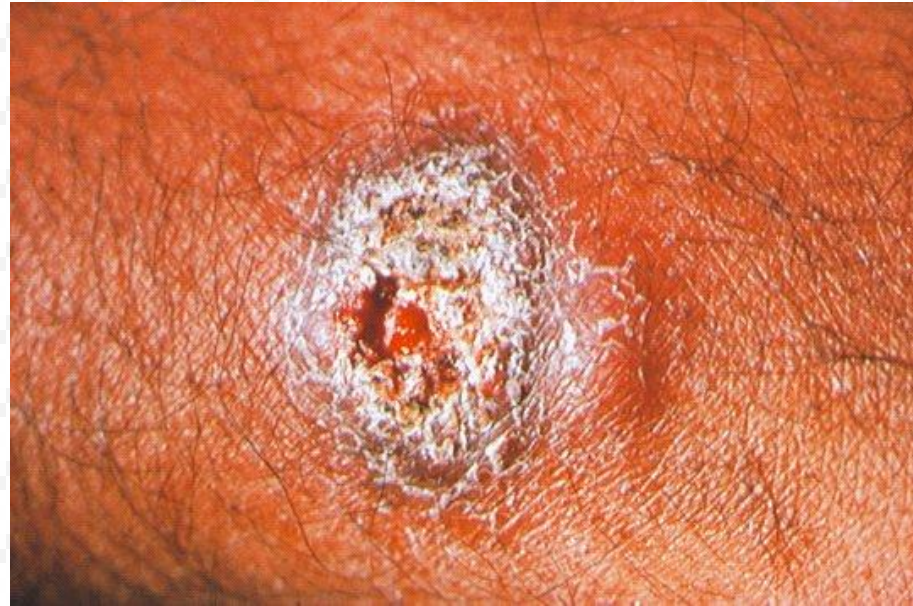Leishman Body

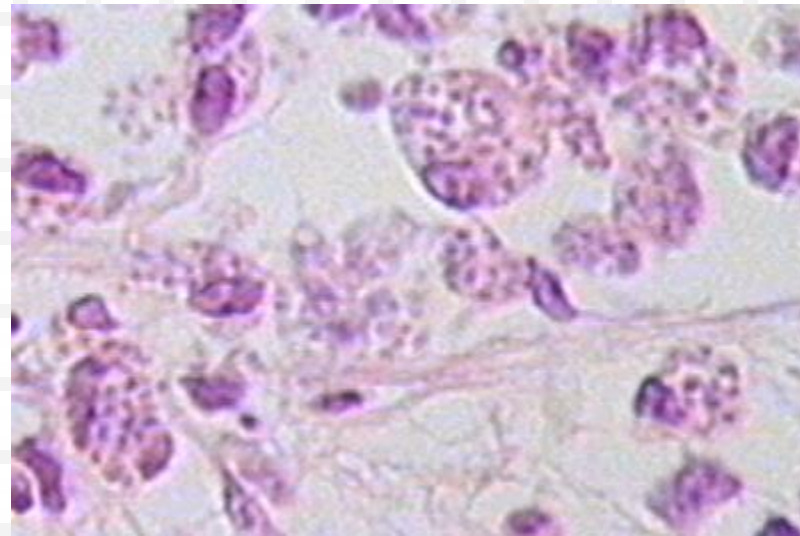
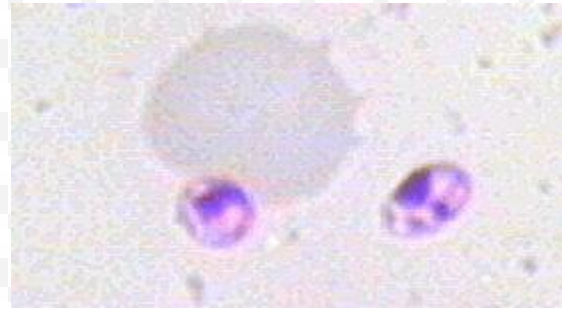
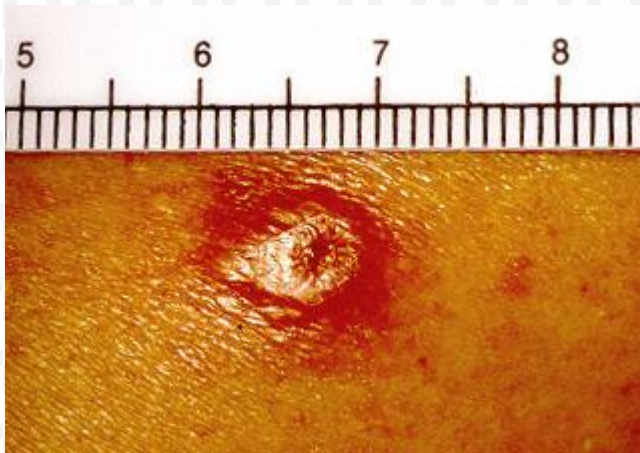


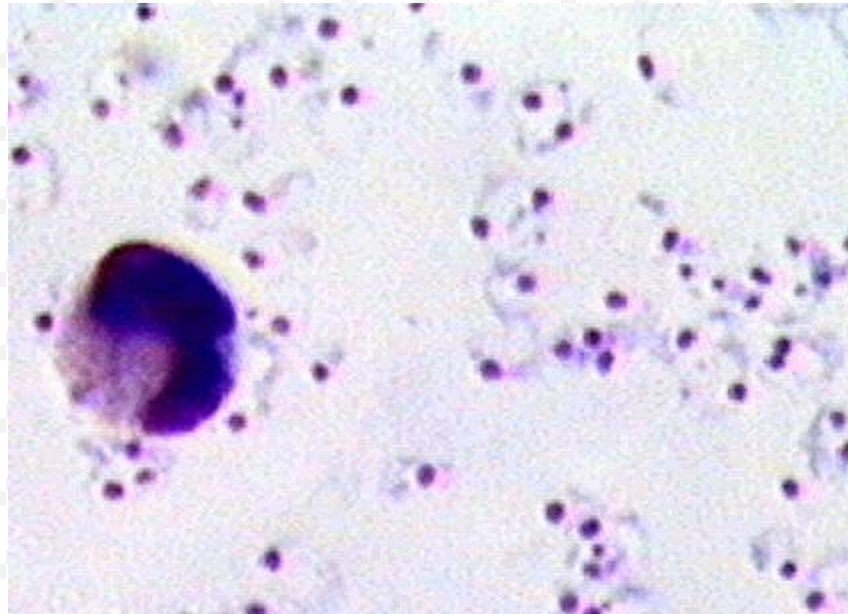


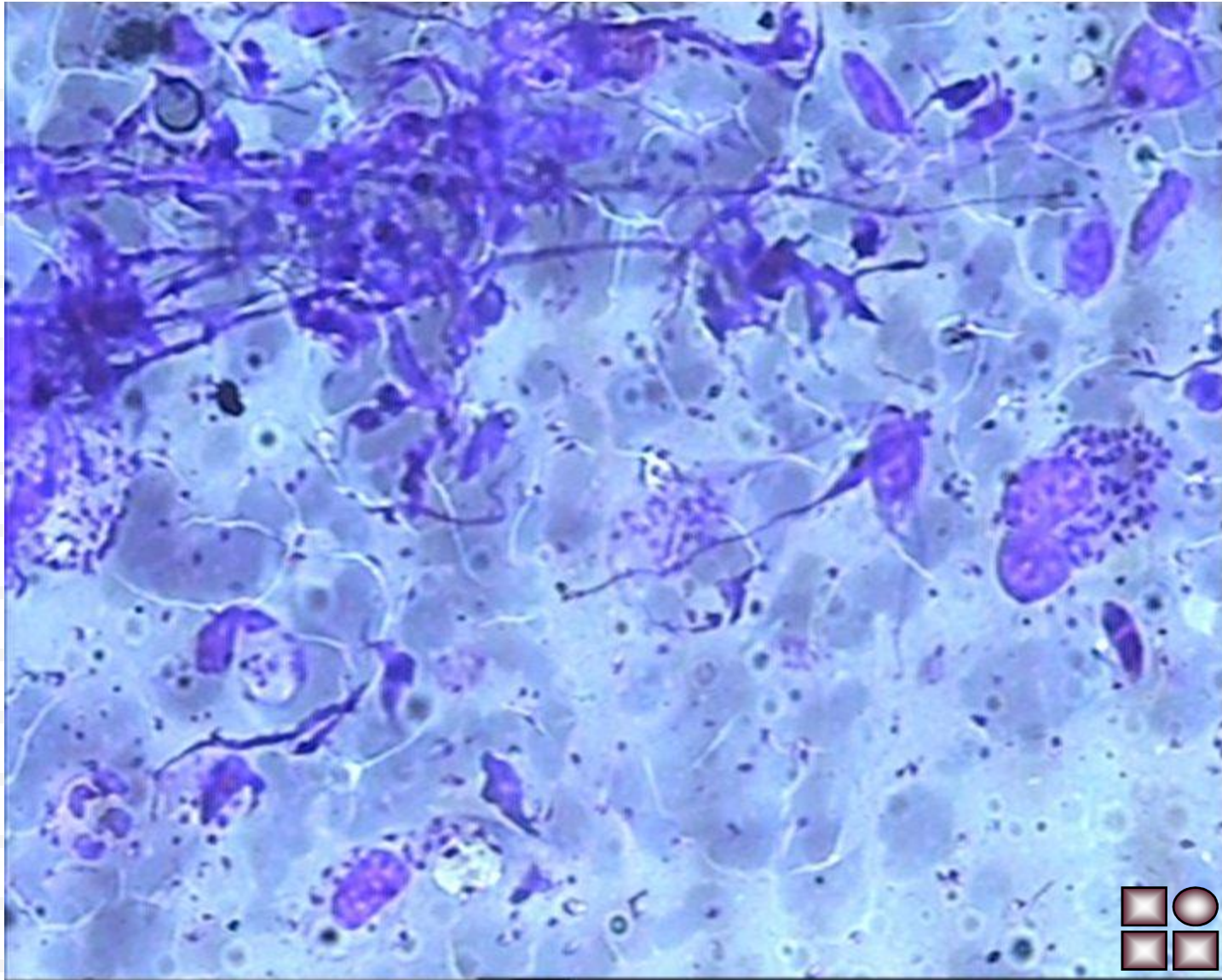

Life cycle of spp *Leishmania*

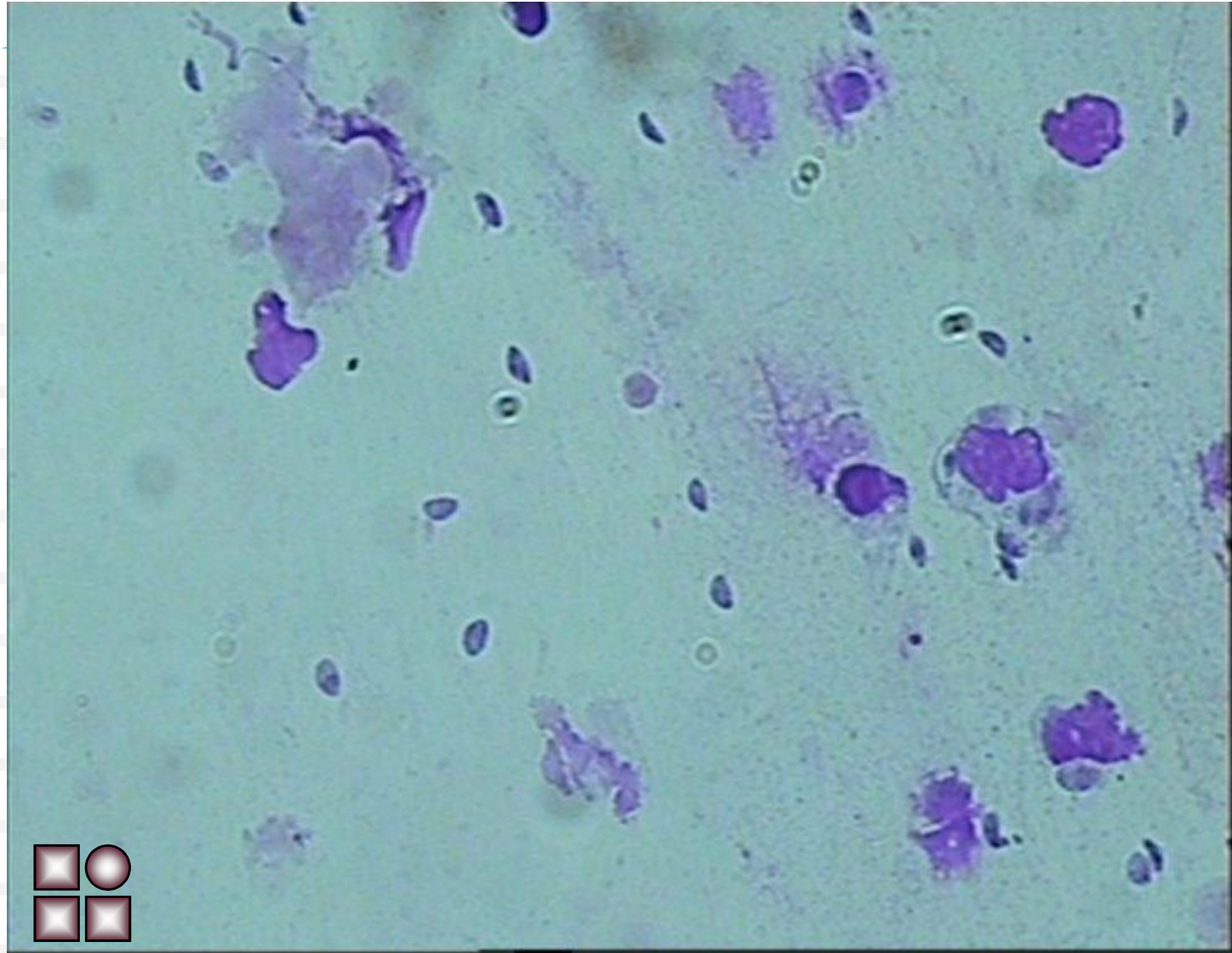





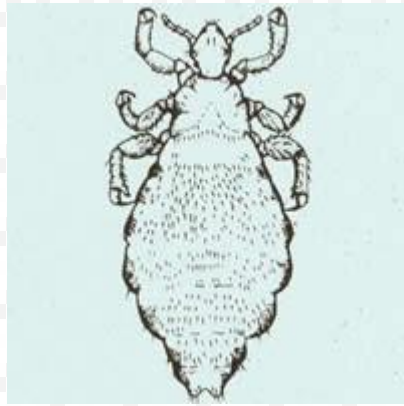
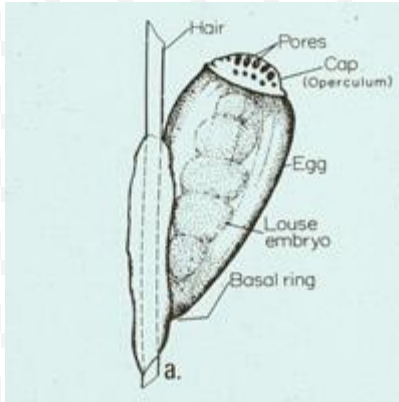


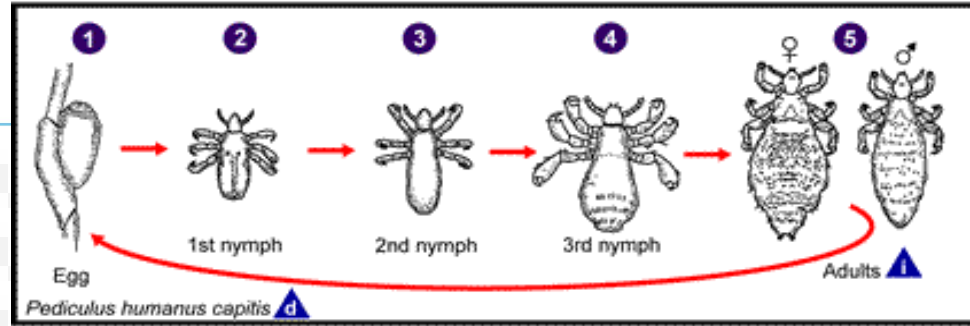




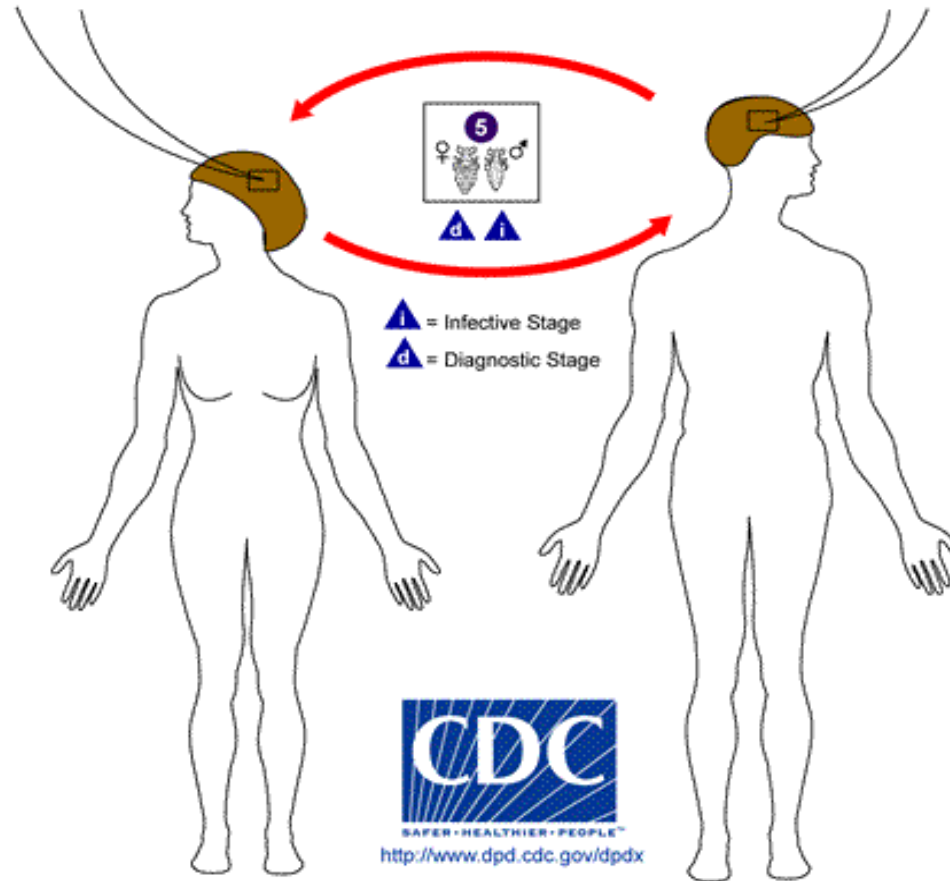


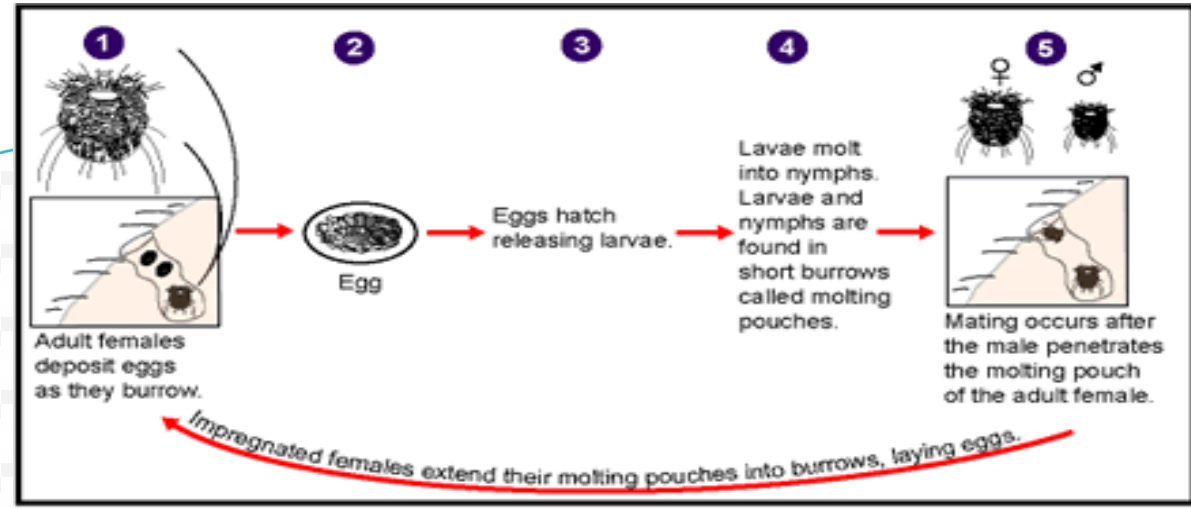
شپشک عانه - شپشک سر و بدن



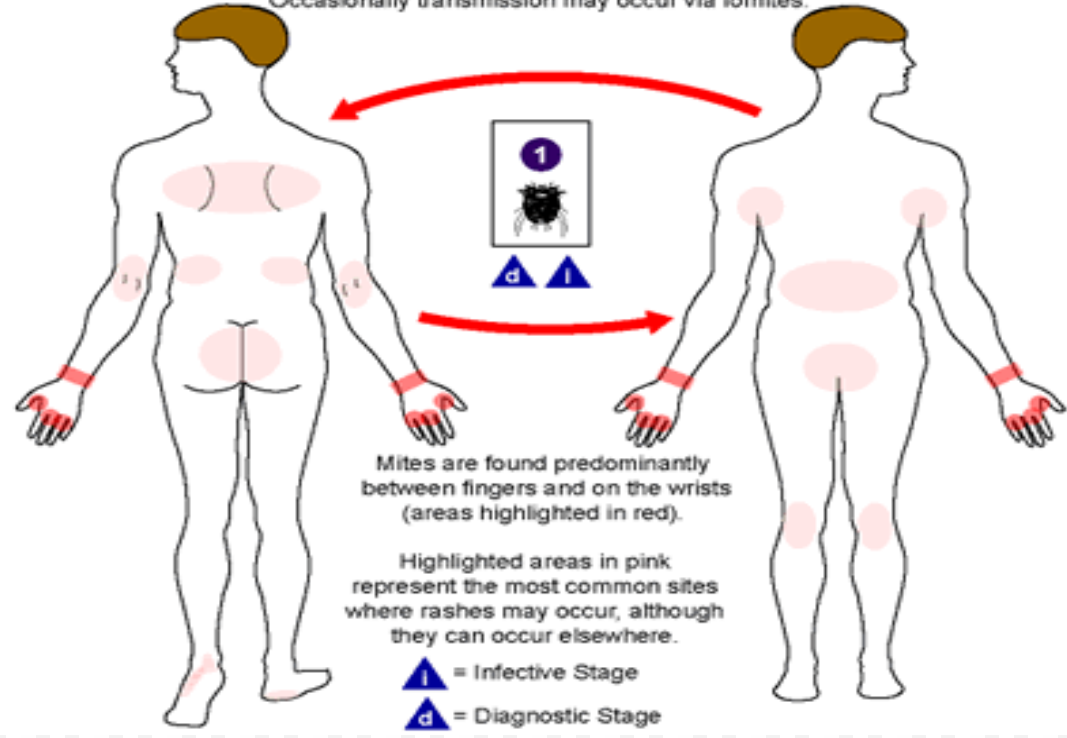


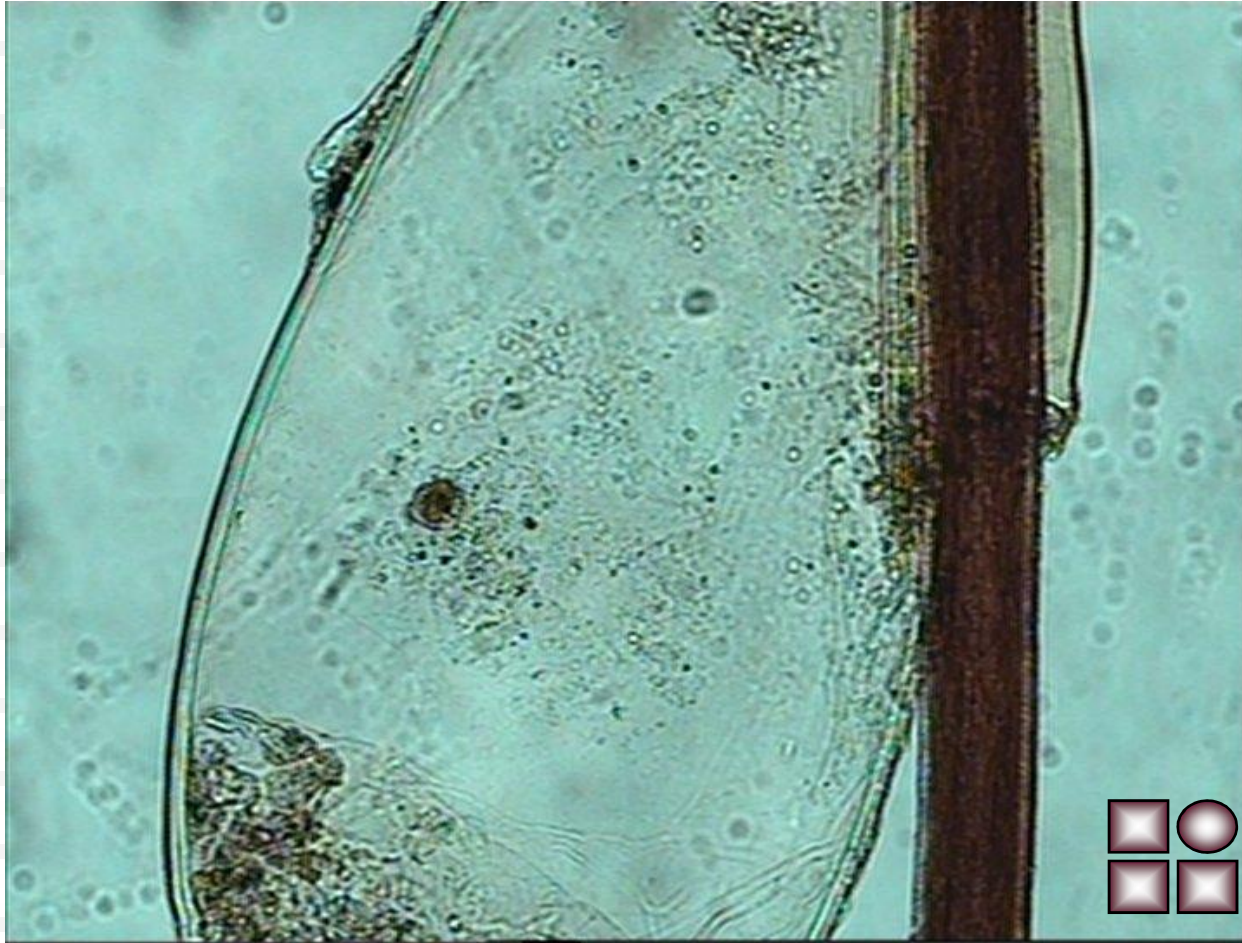
Life cycle of Head Lice

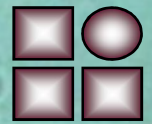
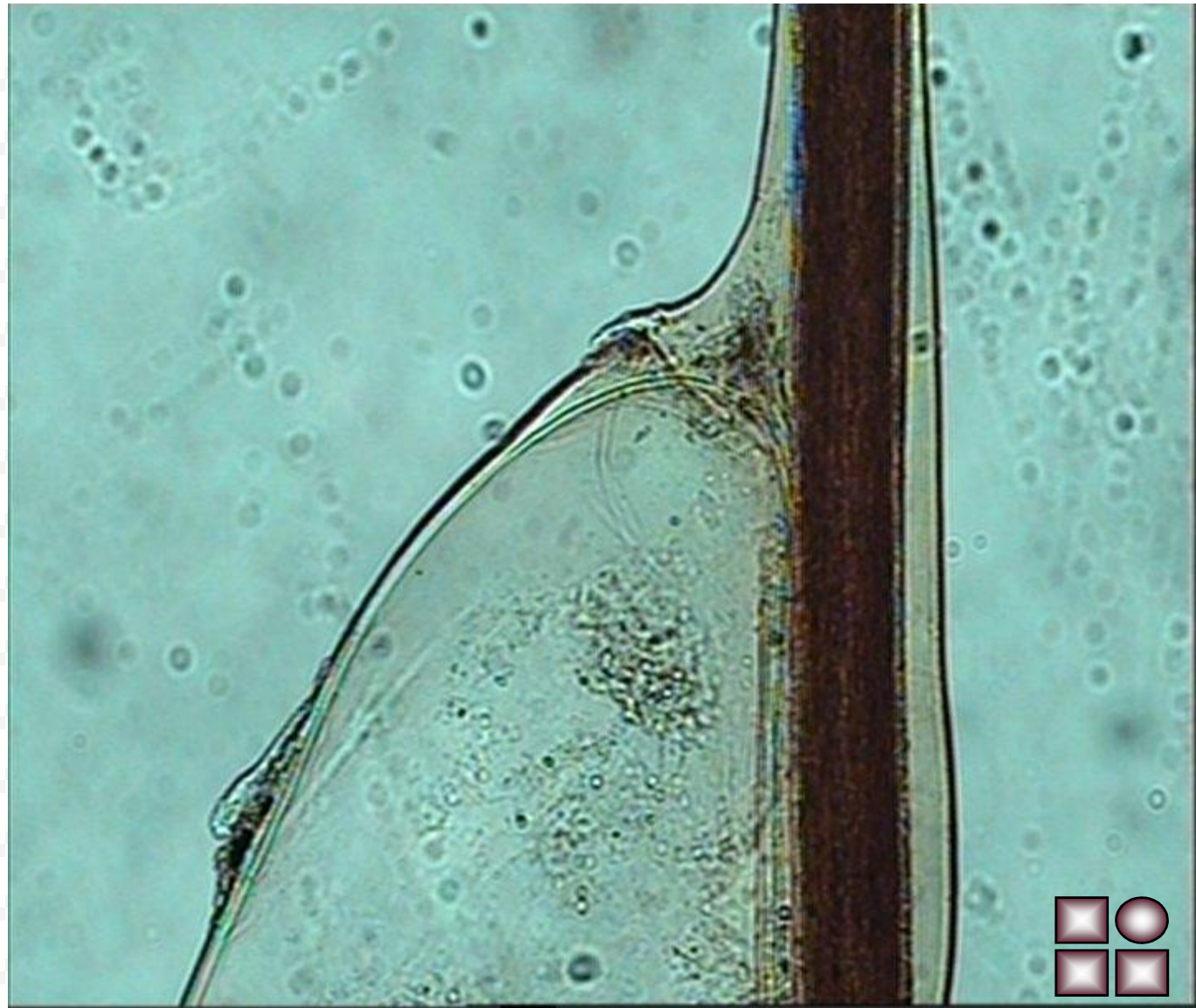



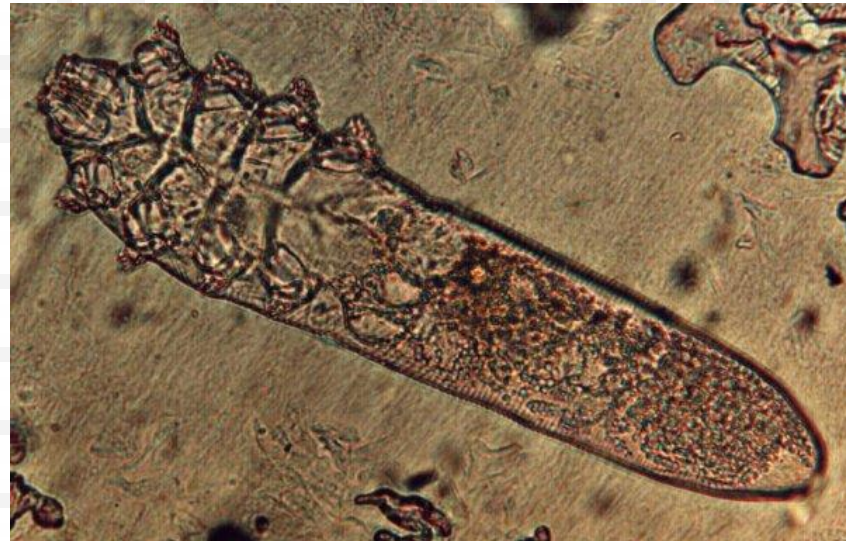
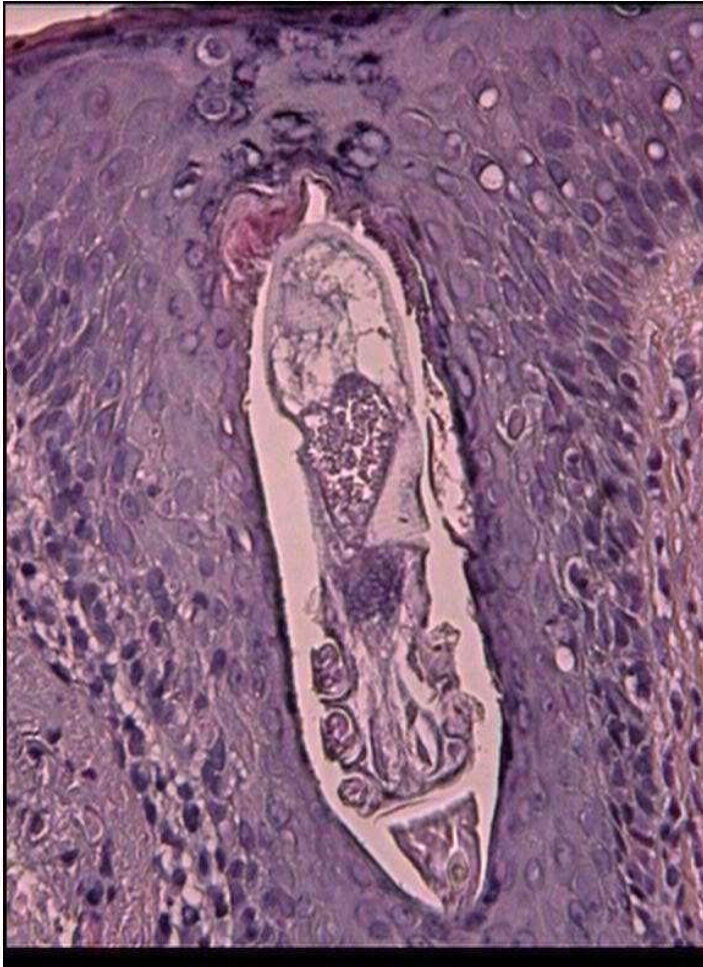The primary mode of transmission is person-to-person.
Occasionally transmission may occur via fomites.

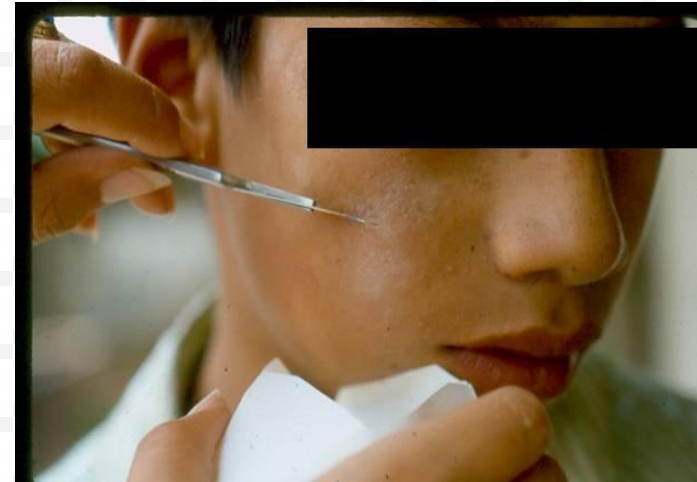
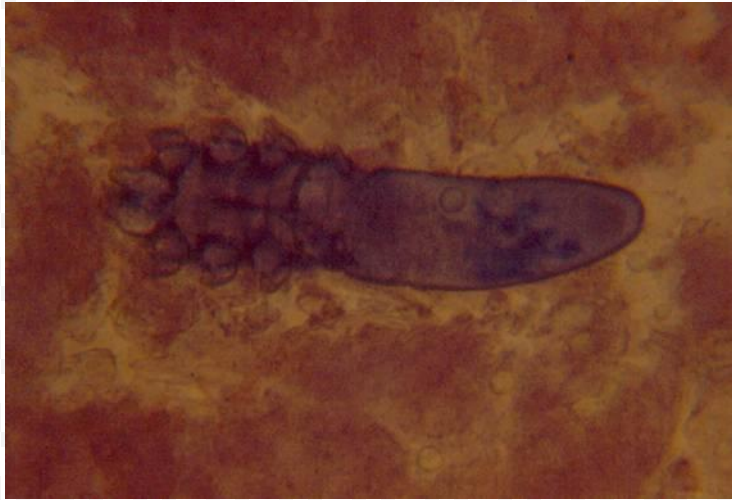
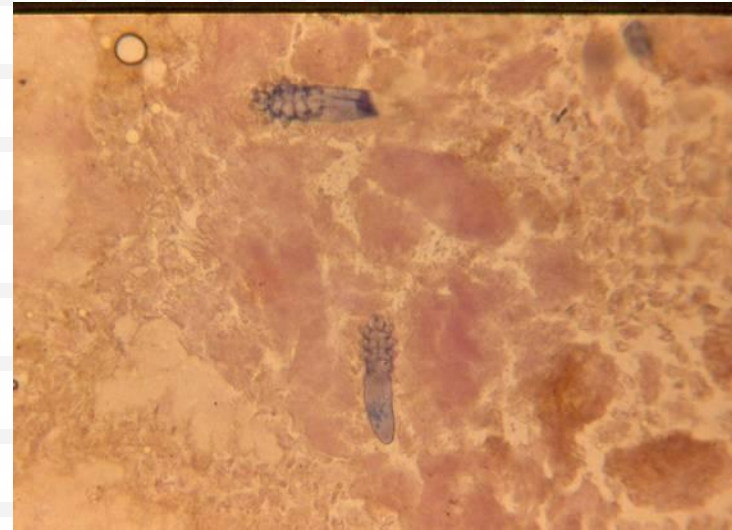


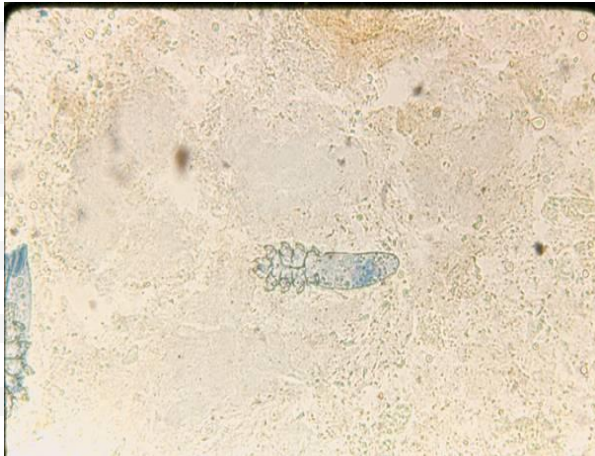

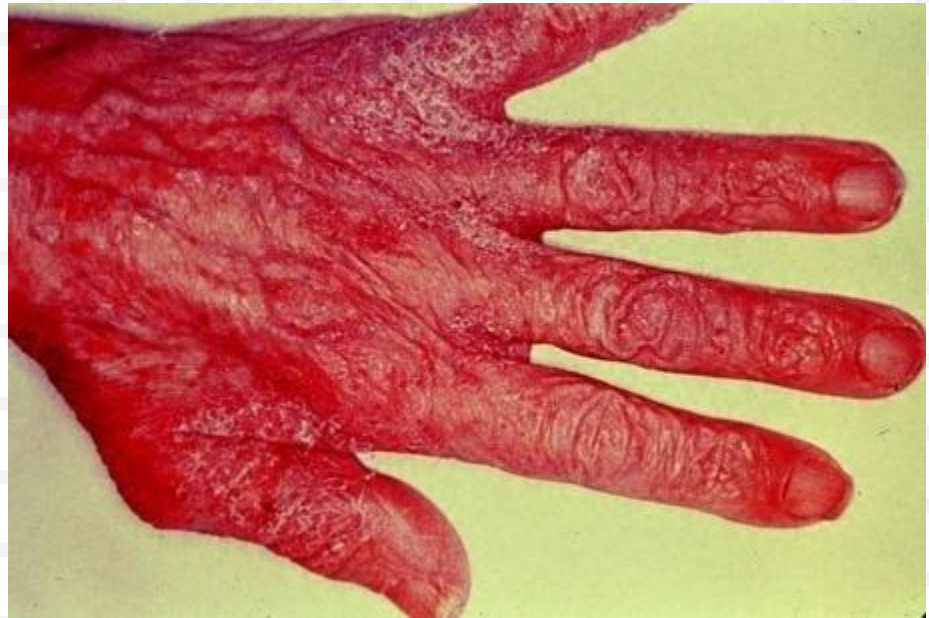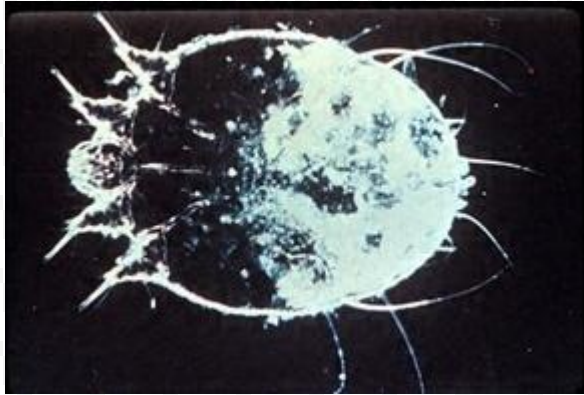
دمودکس

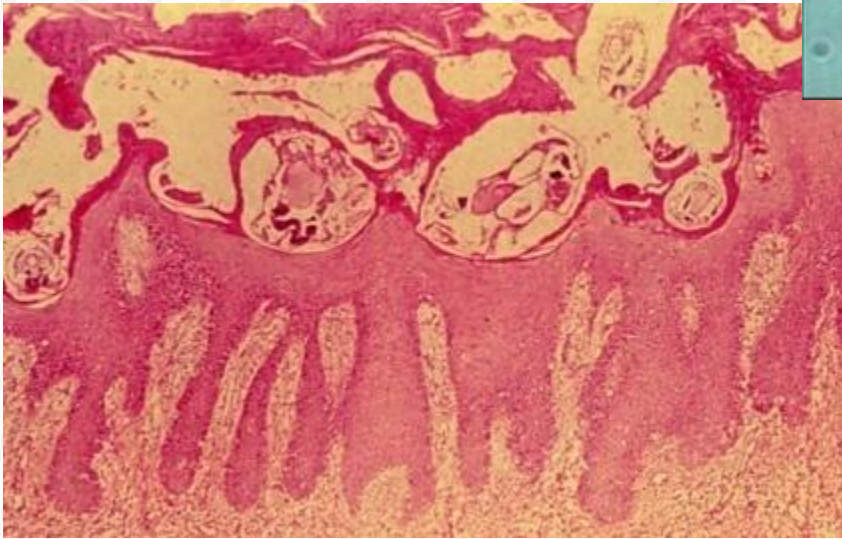
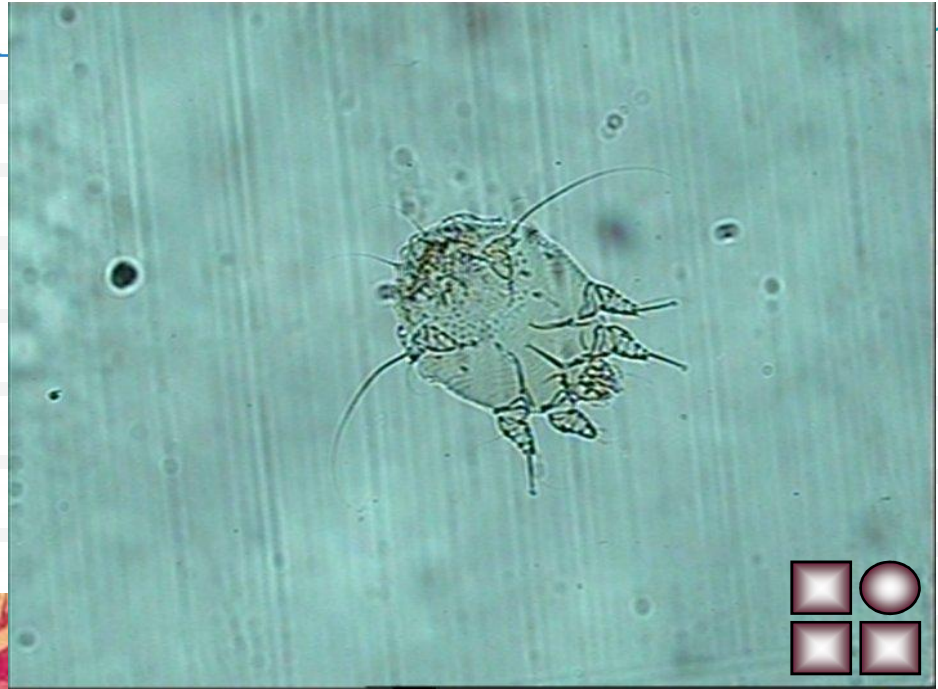


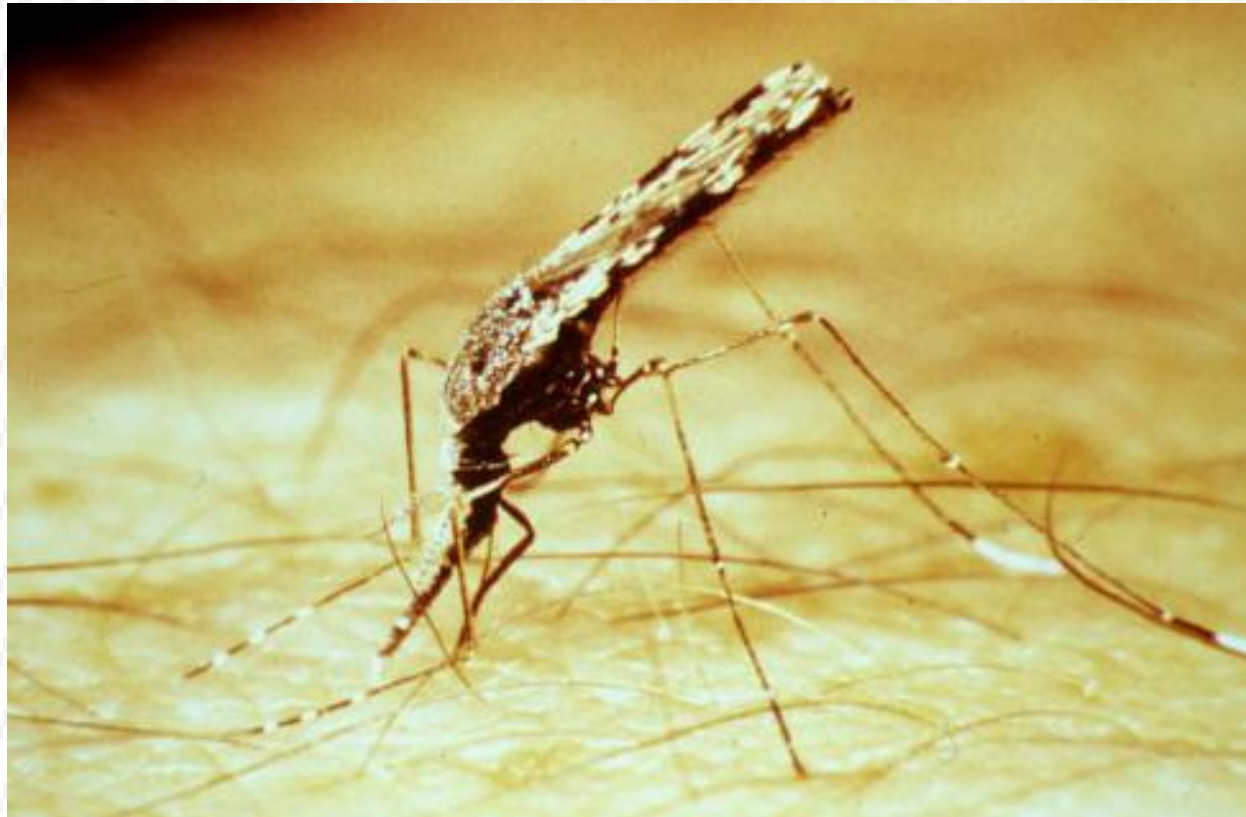


Sarcoptes scabiei mite









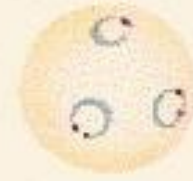P. falciparum



marginal form



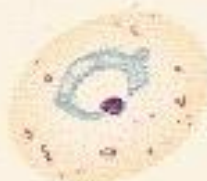ring form



double dotted rings



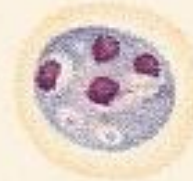ring form



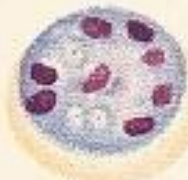young trophozoite



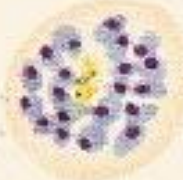
trophozoite



early schizont



schizont



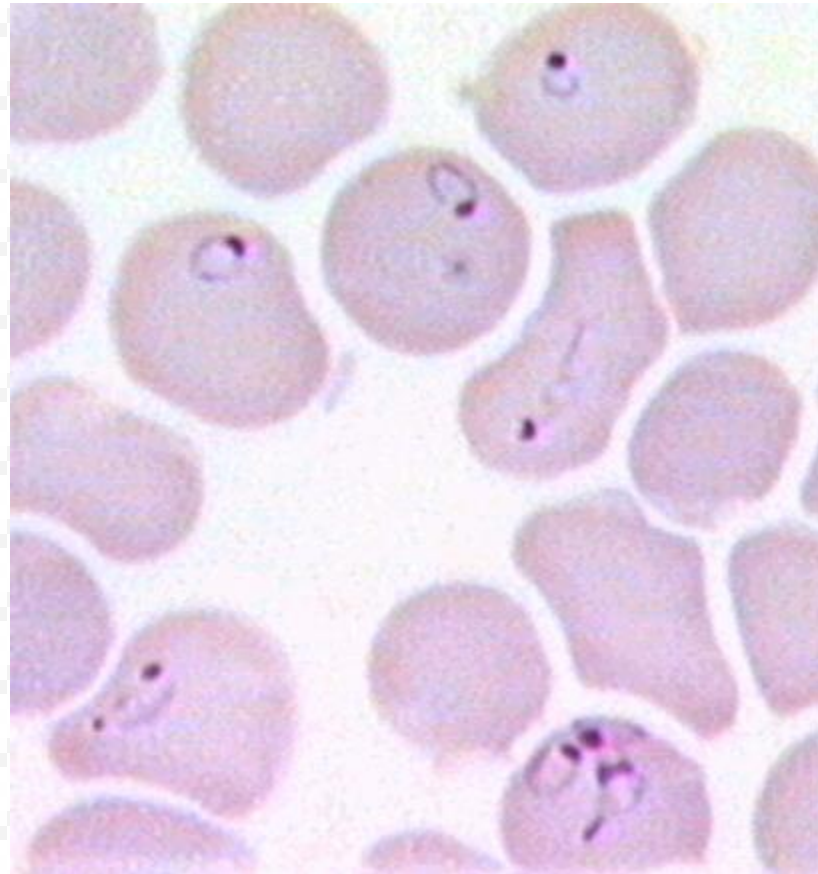
mature schizont

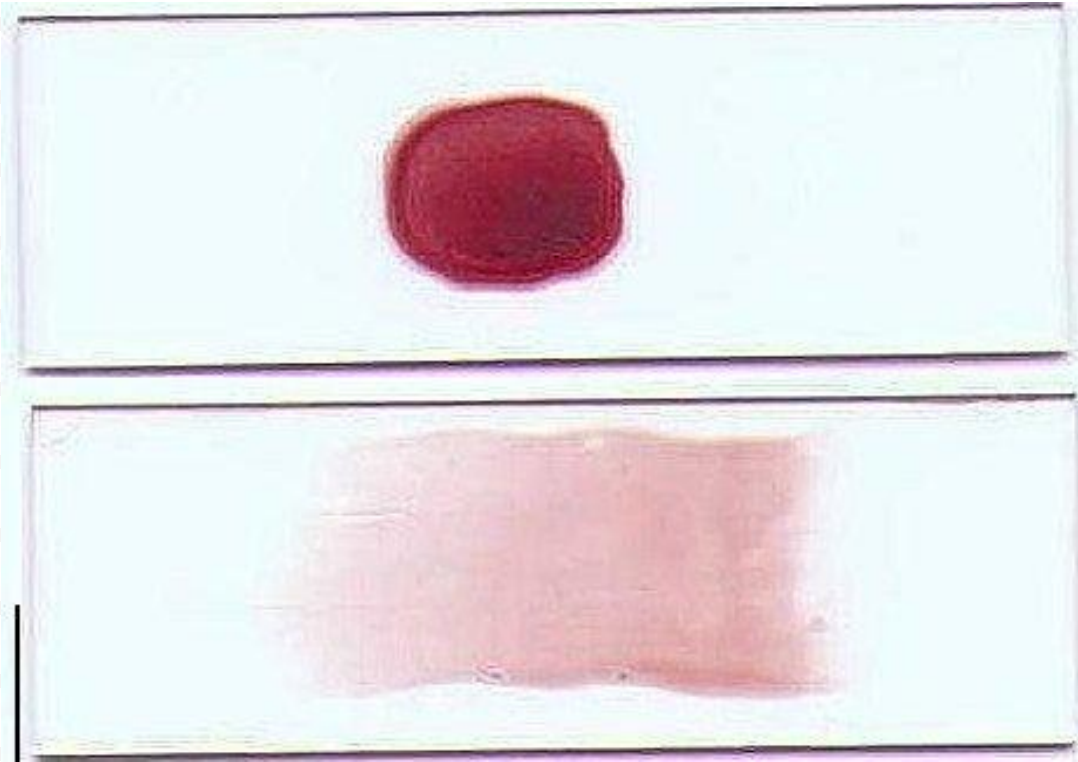


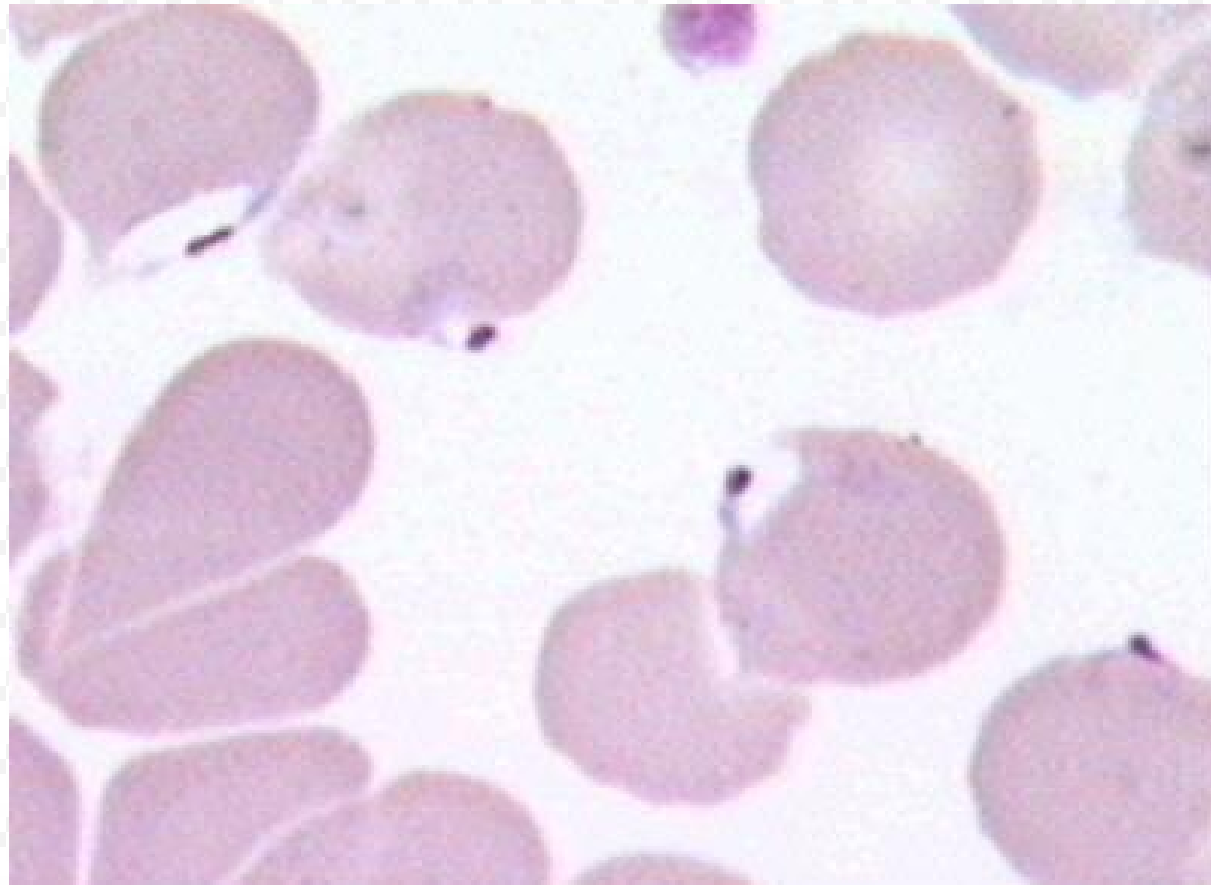
female gametocyte



male gametocyte



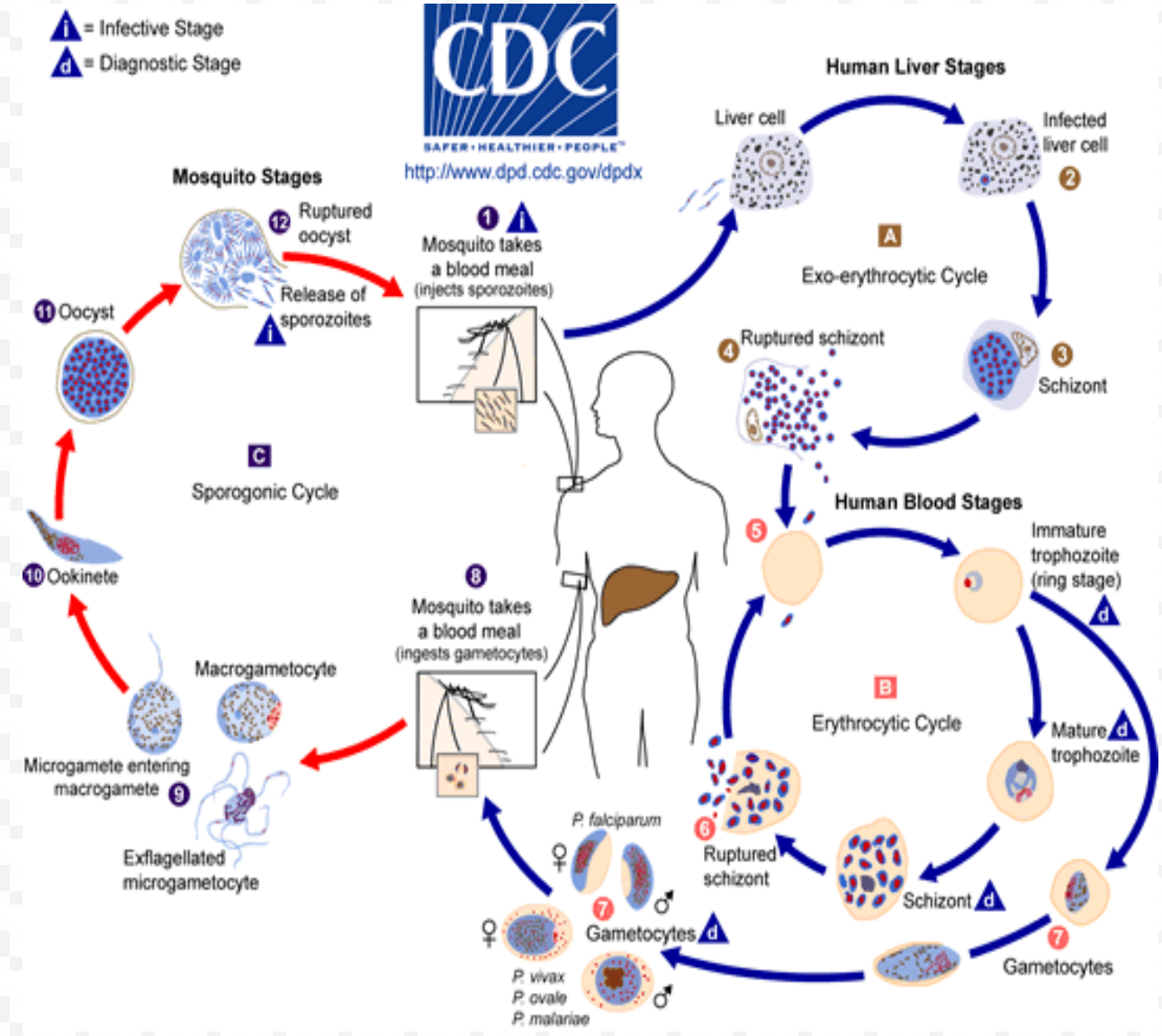


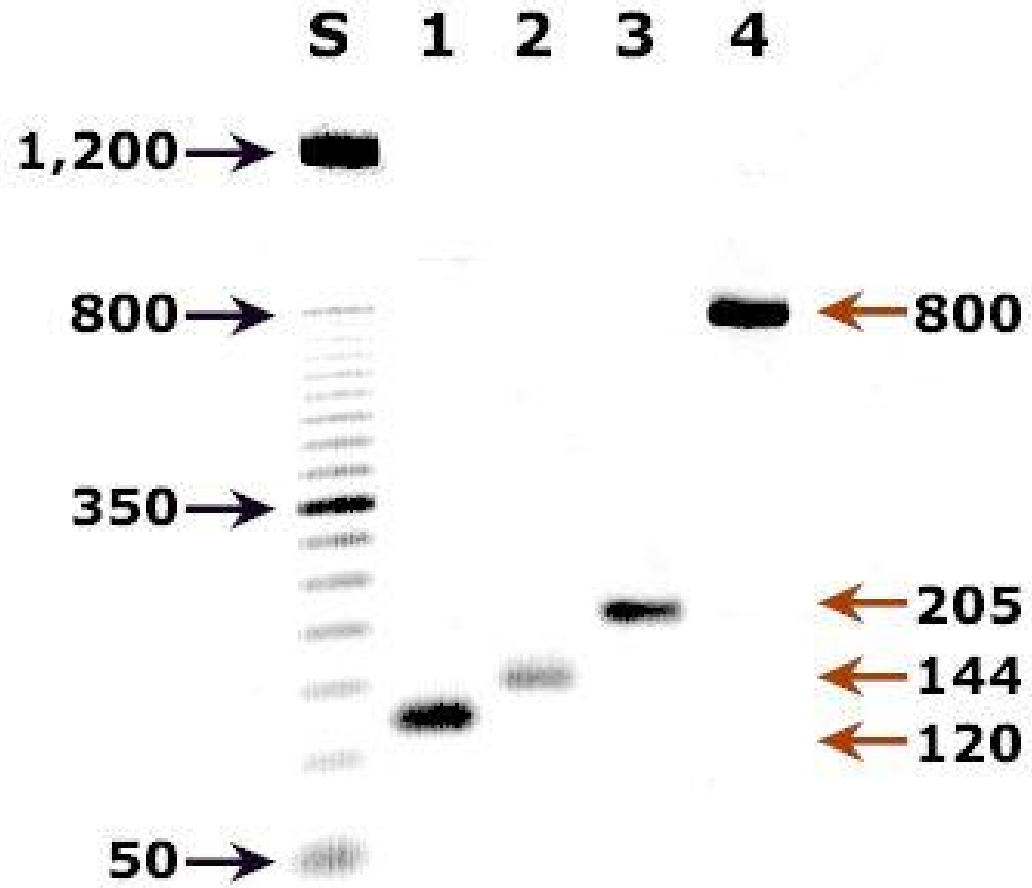
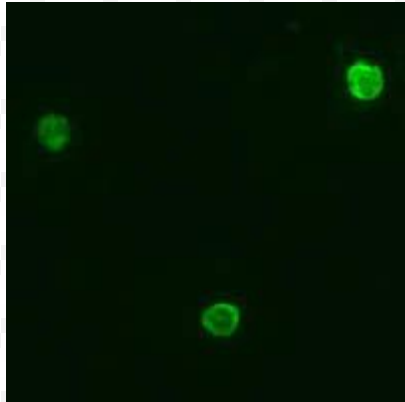


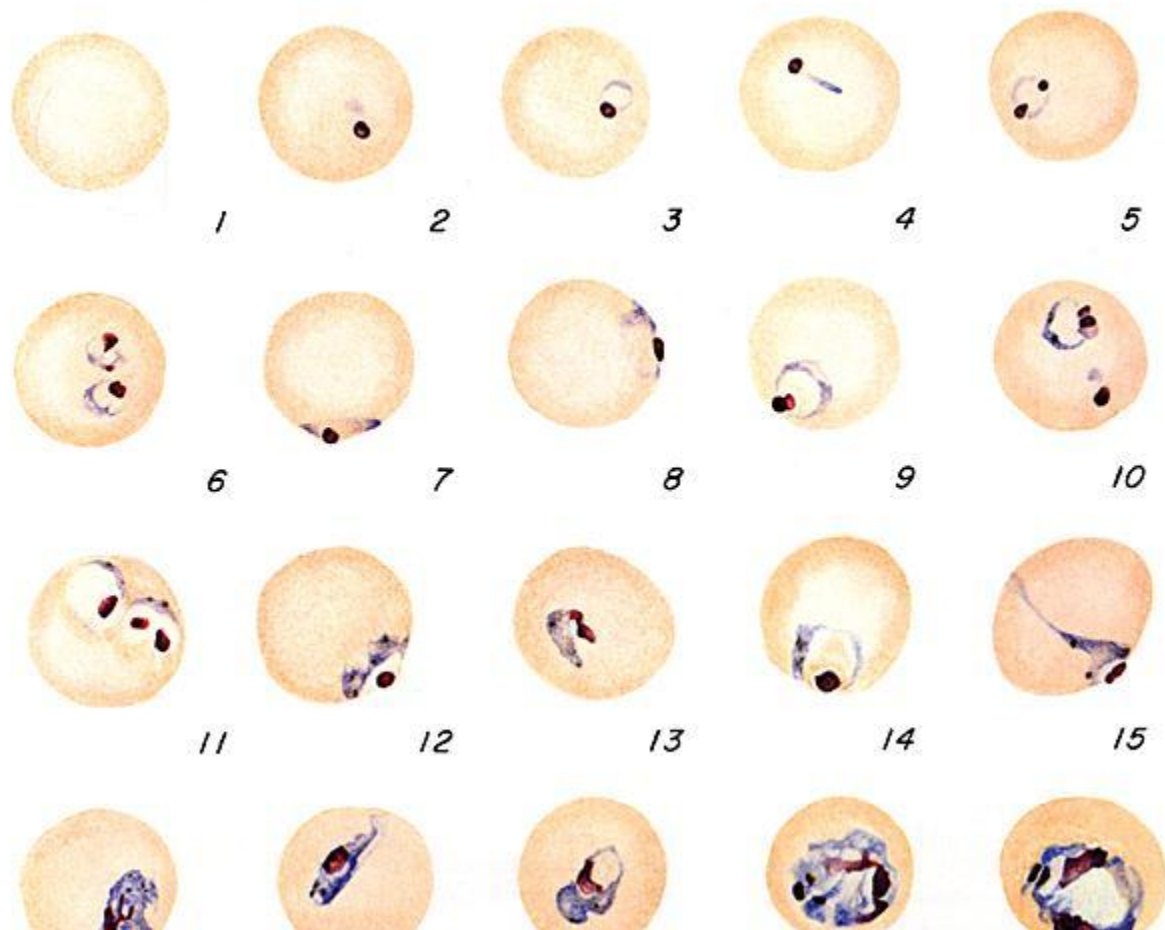


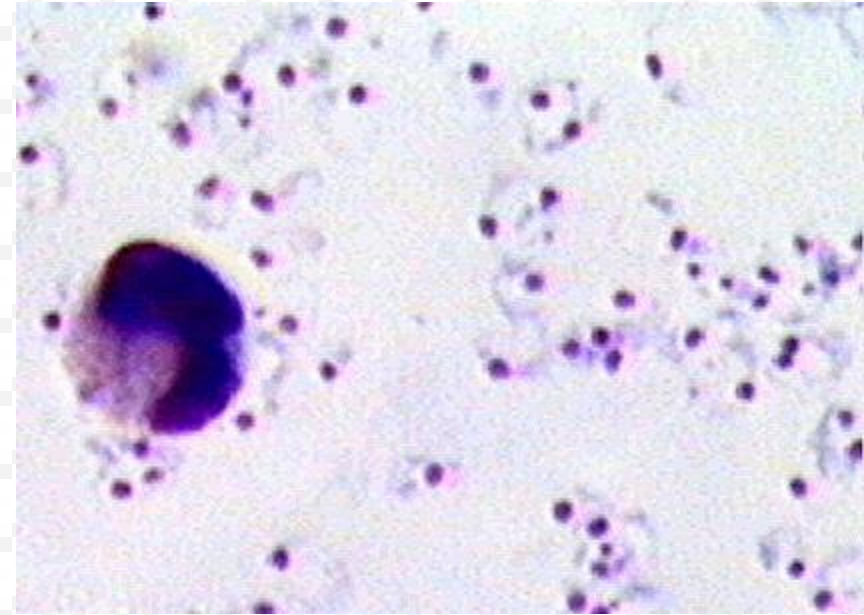
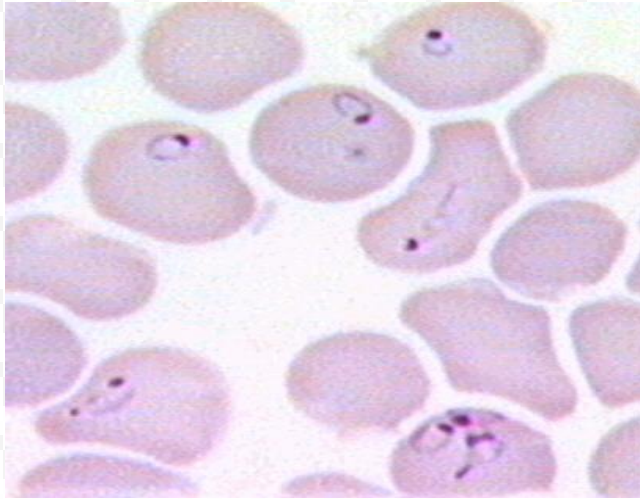
Plasmodium spp

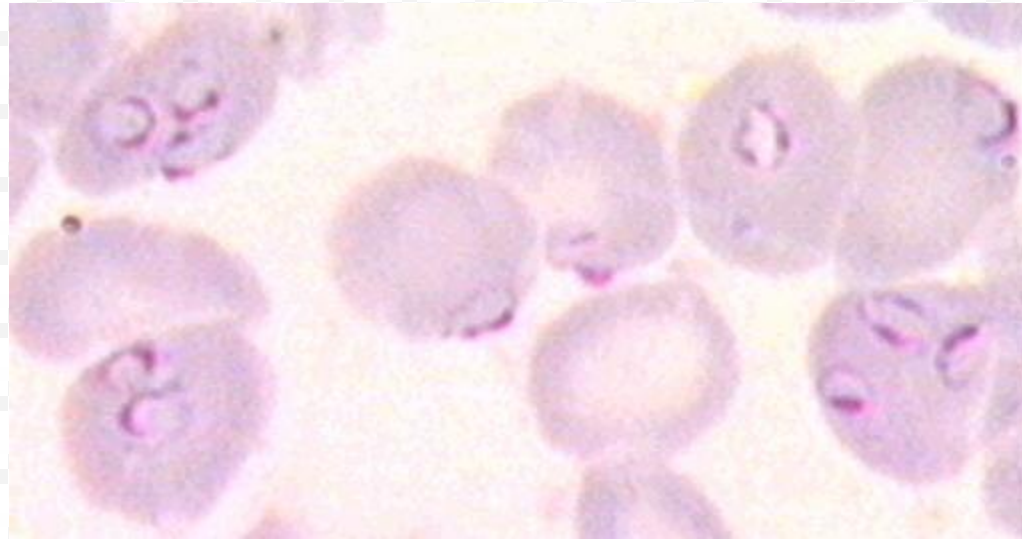
Life cycle of
Plasmodium spp

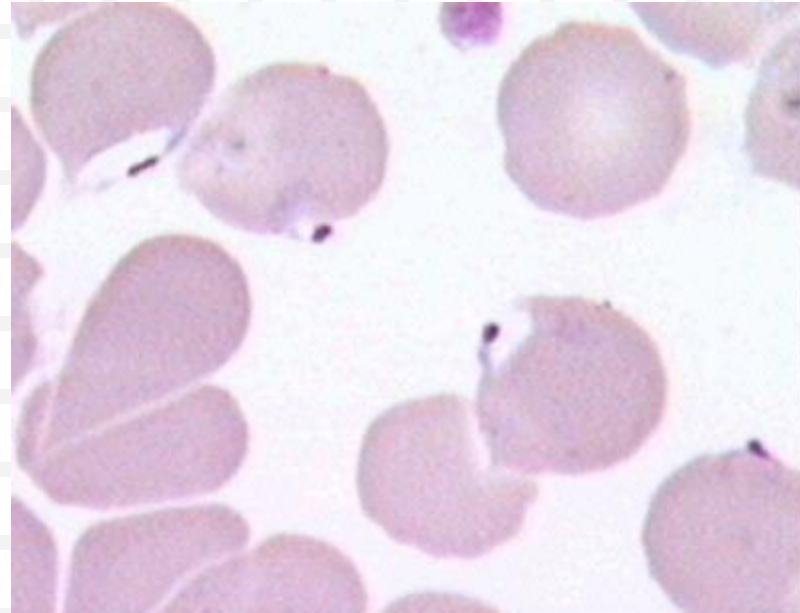


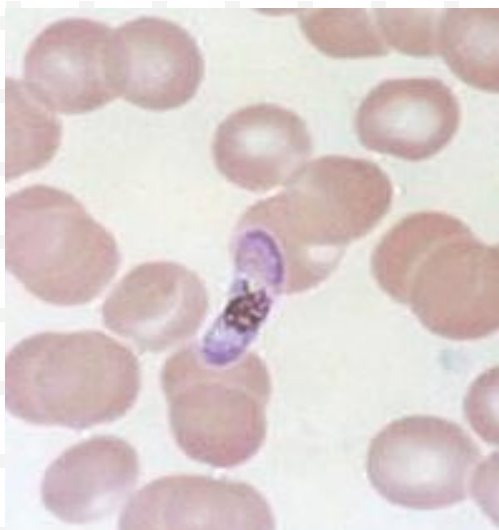
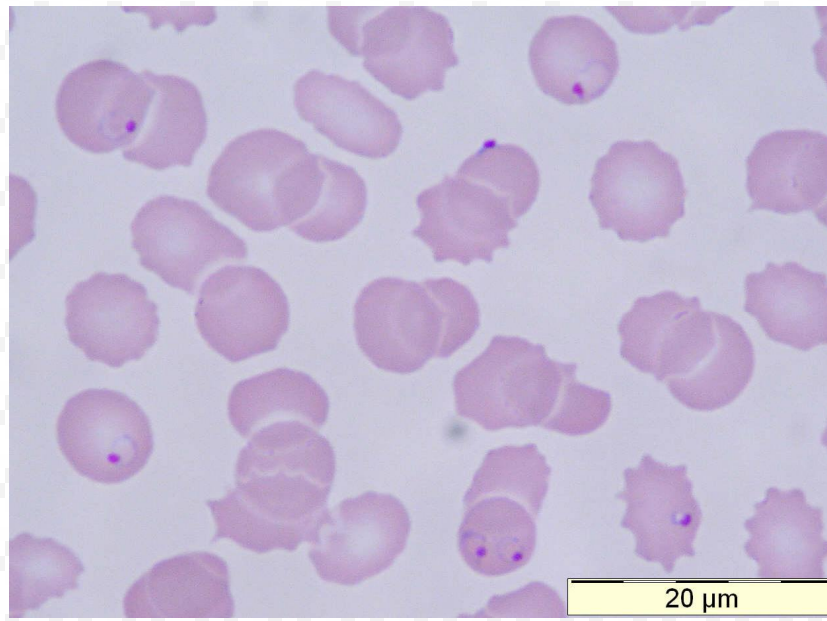
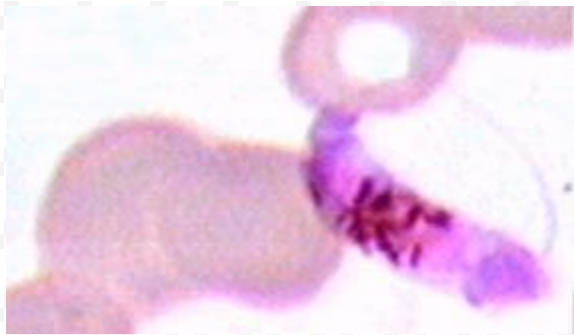

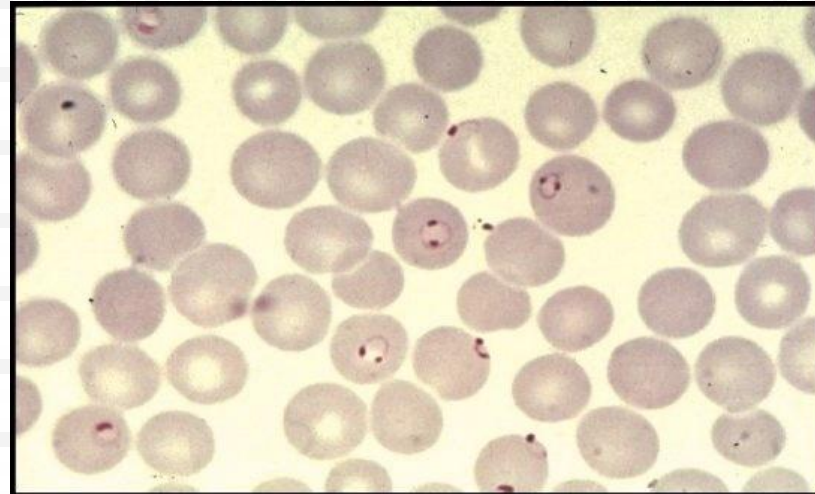



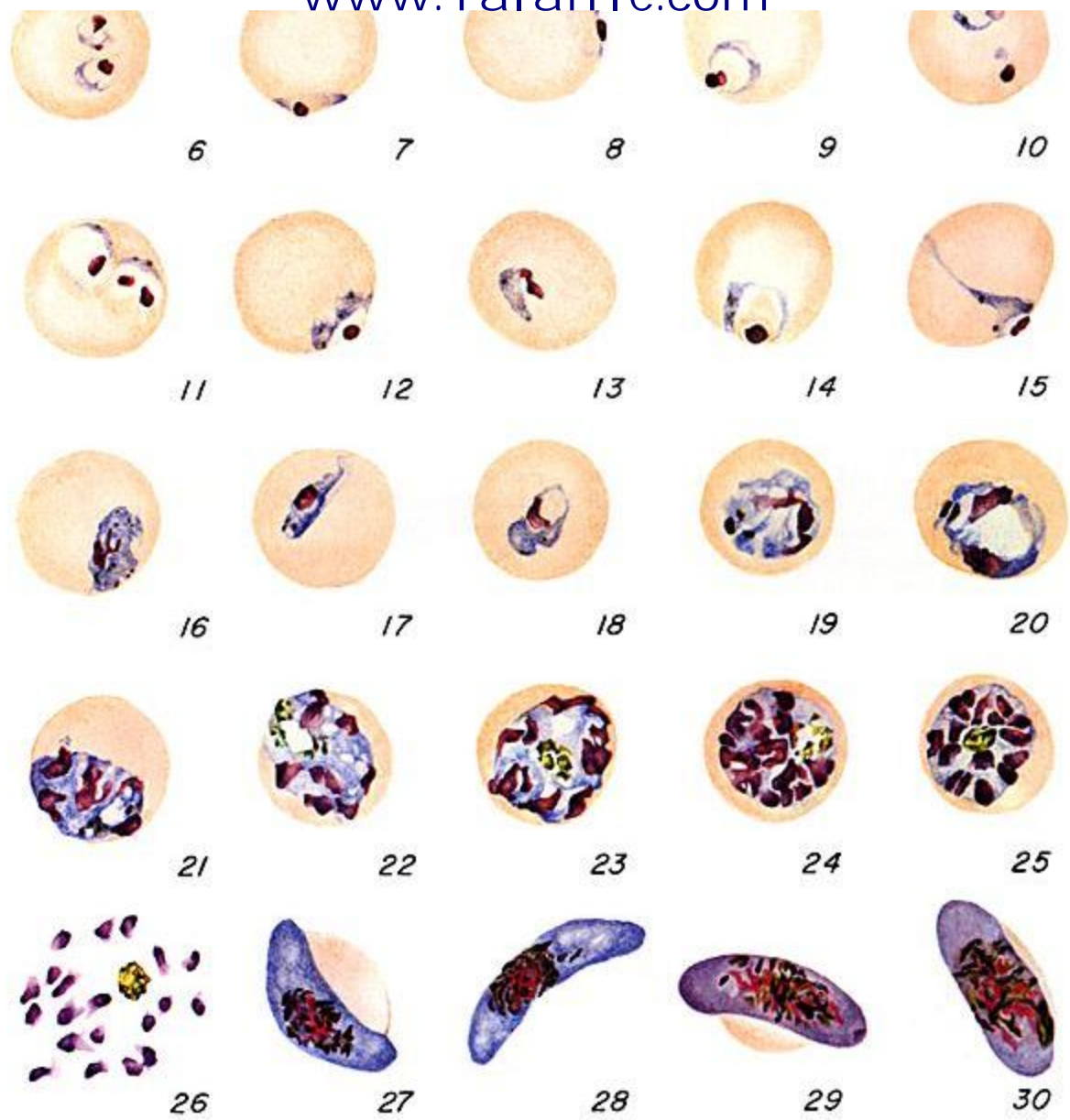












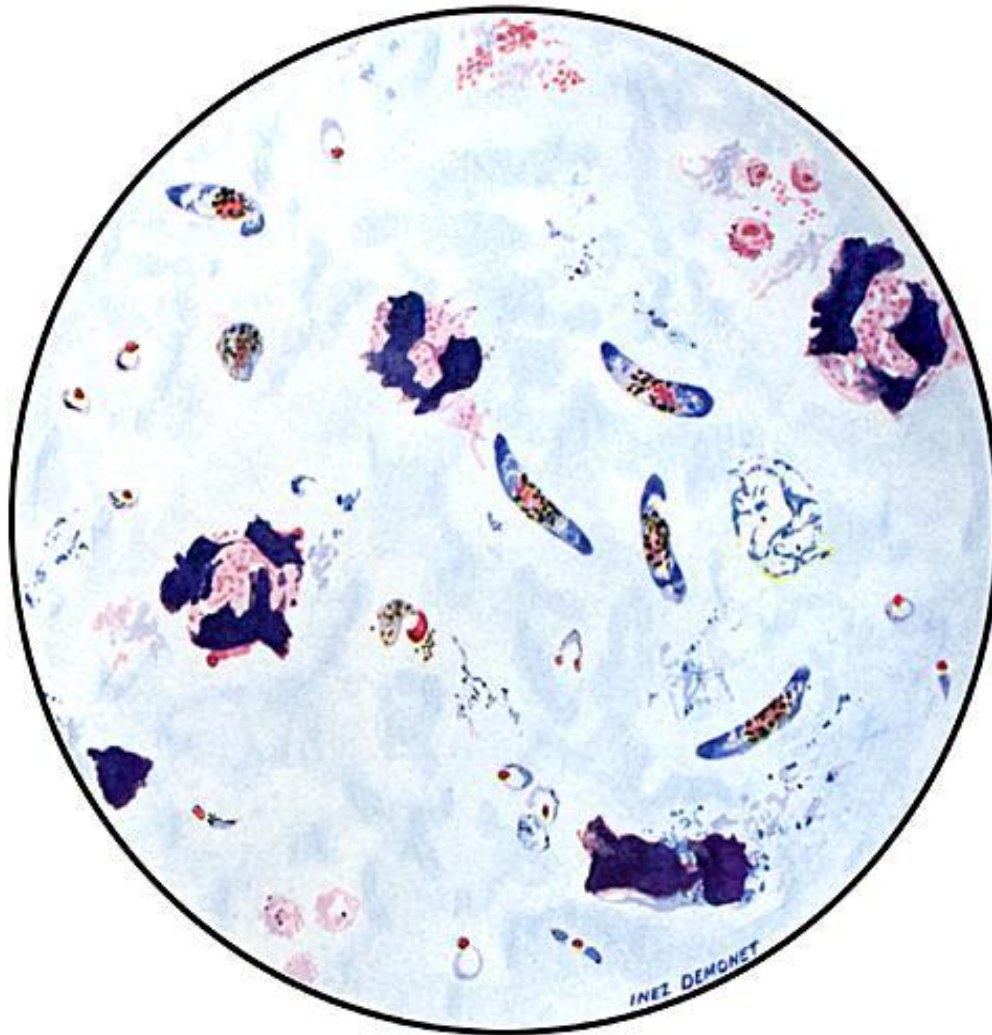
PLASMODIUM FALCIPARUM


S.W. Nicholson



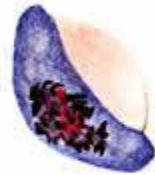- Thick Blood S

Thick Blood Smears

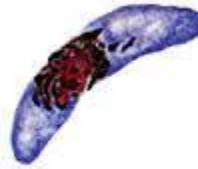



Mature macrogametocytes (female ;(Fig. 29 :۳۰ , Mature microgametocytes (male.(



27



28

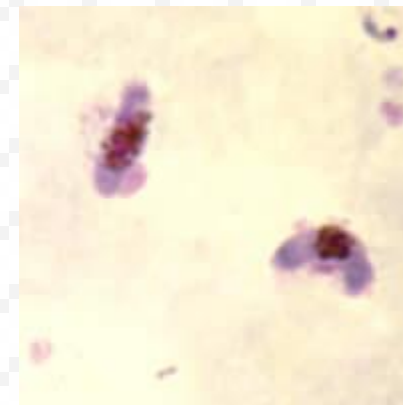
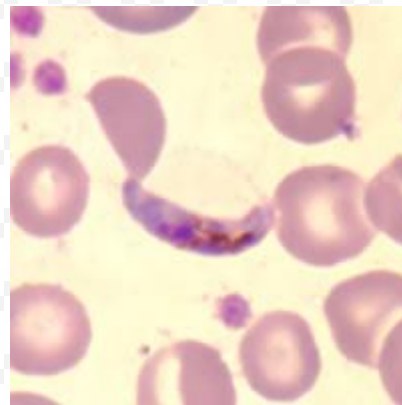
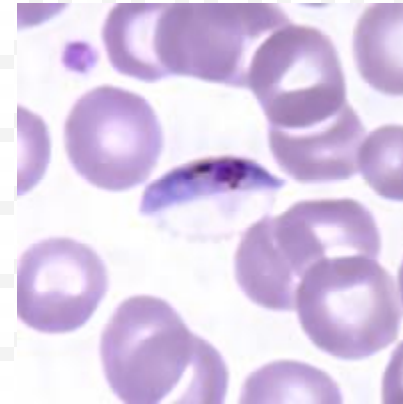
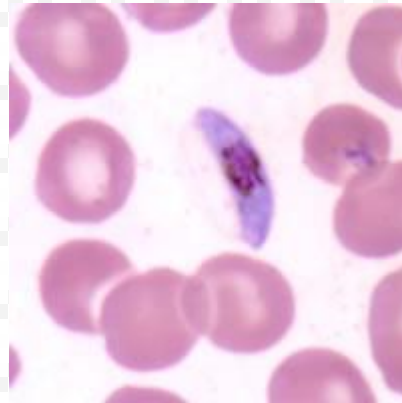
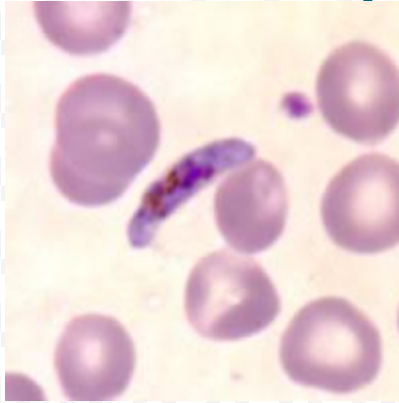


29

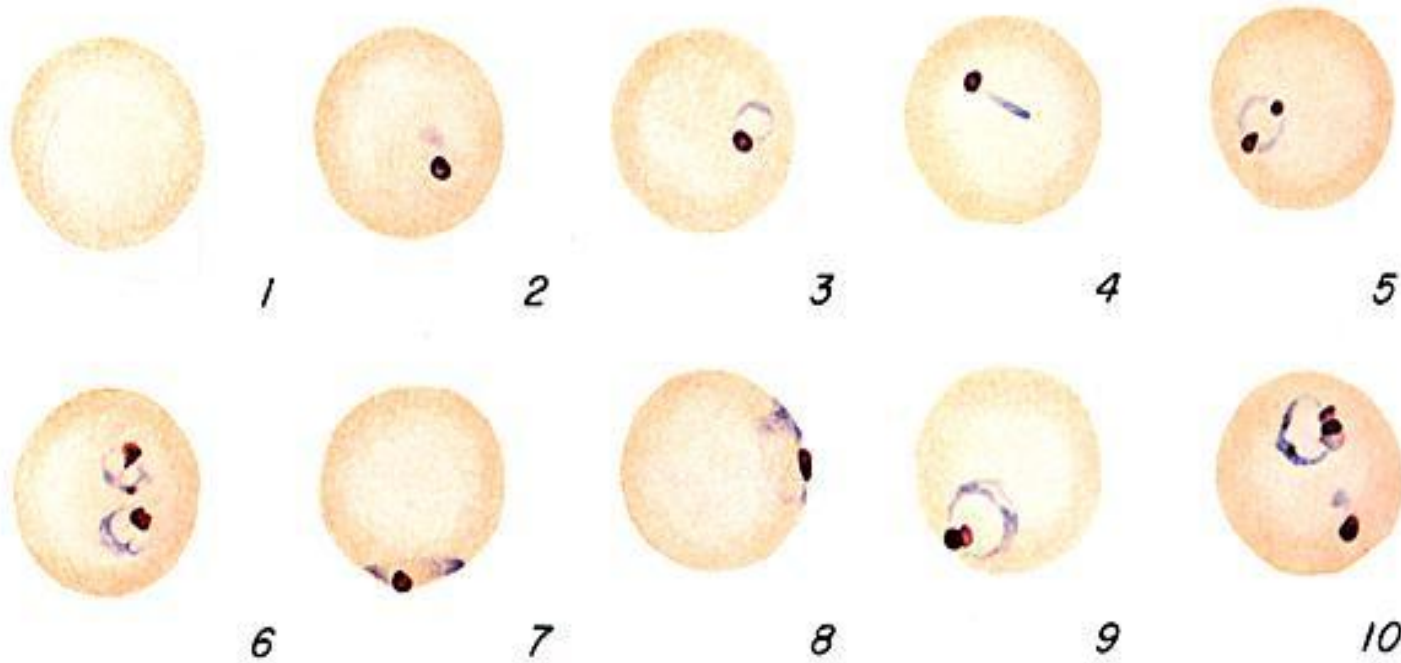


30

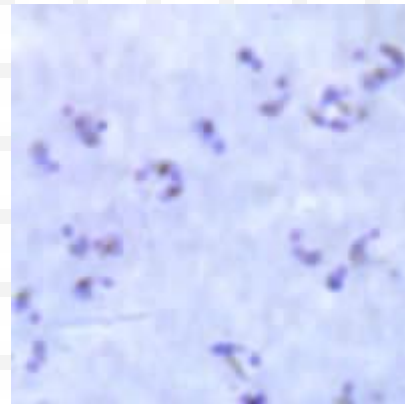
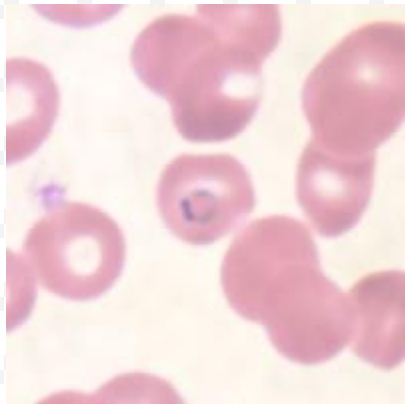
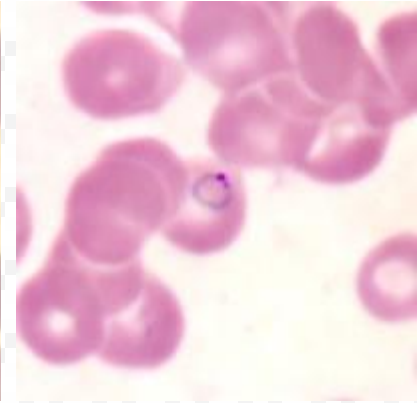
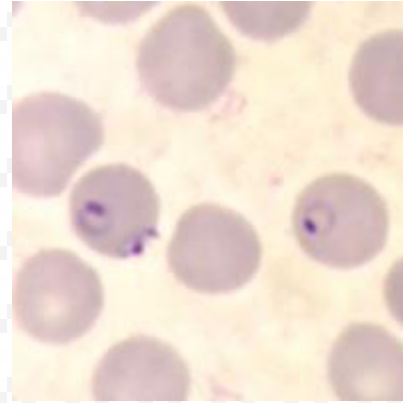
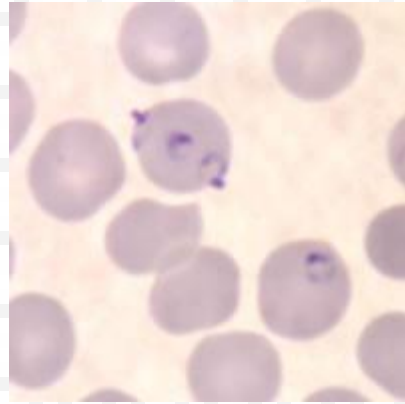
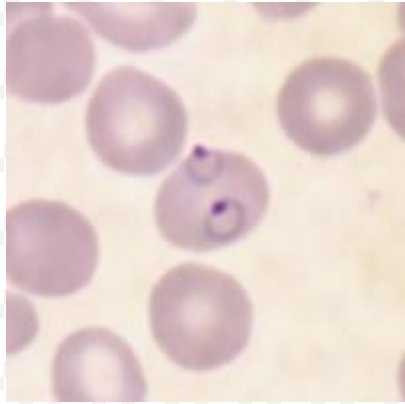
Gametocytes of *P. falciparum*



Ring Stage



Ring Stage





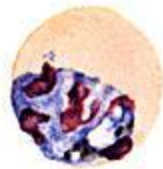schizonts



19



20



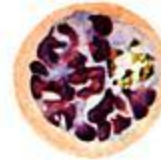21



22



23



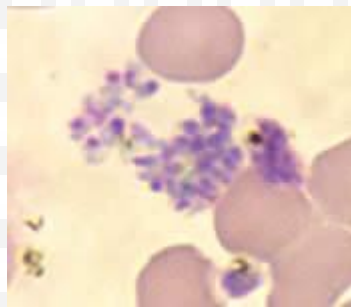
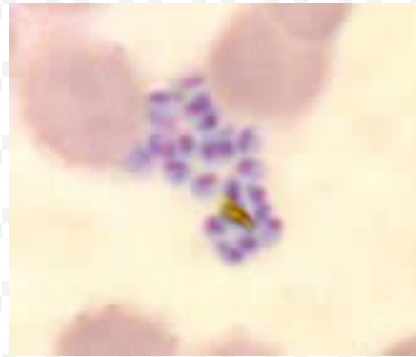
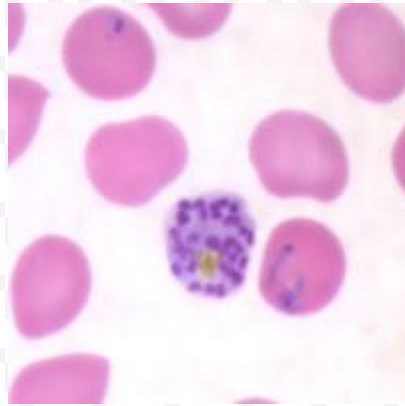
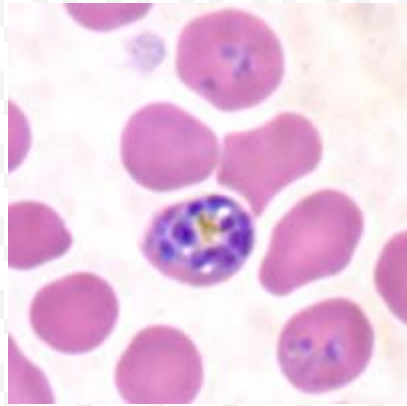
24



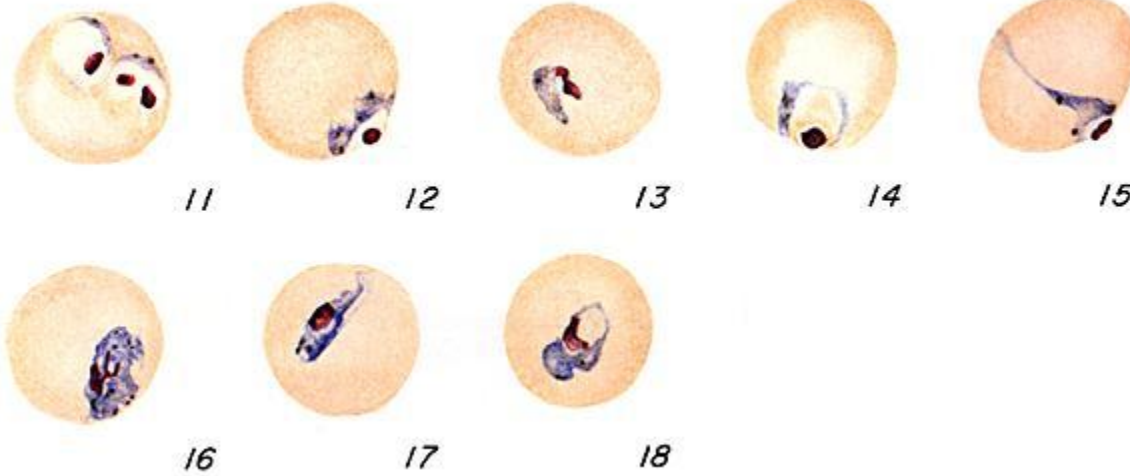
25



26

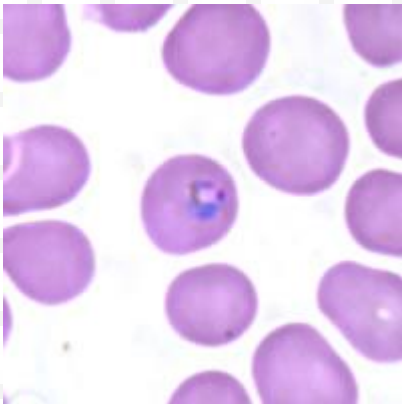
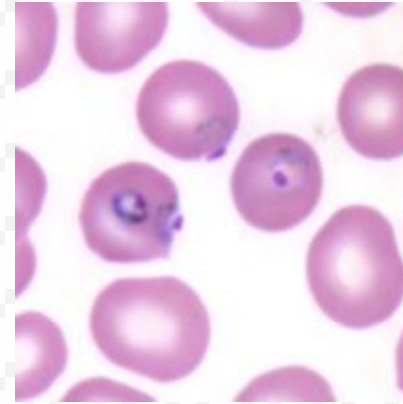
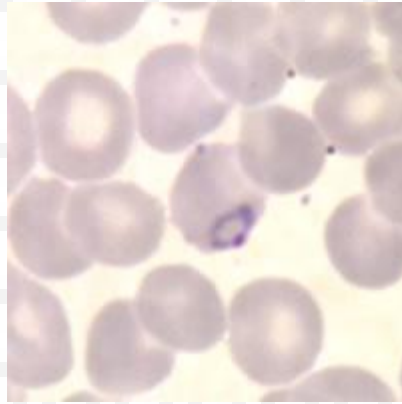
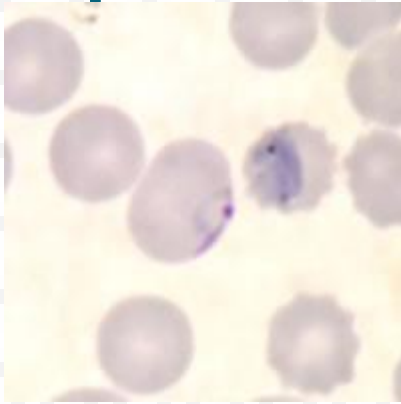


Trophozoites

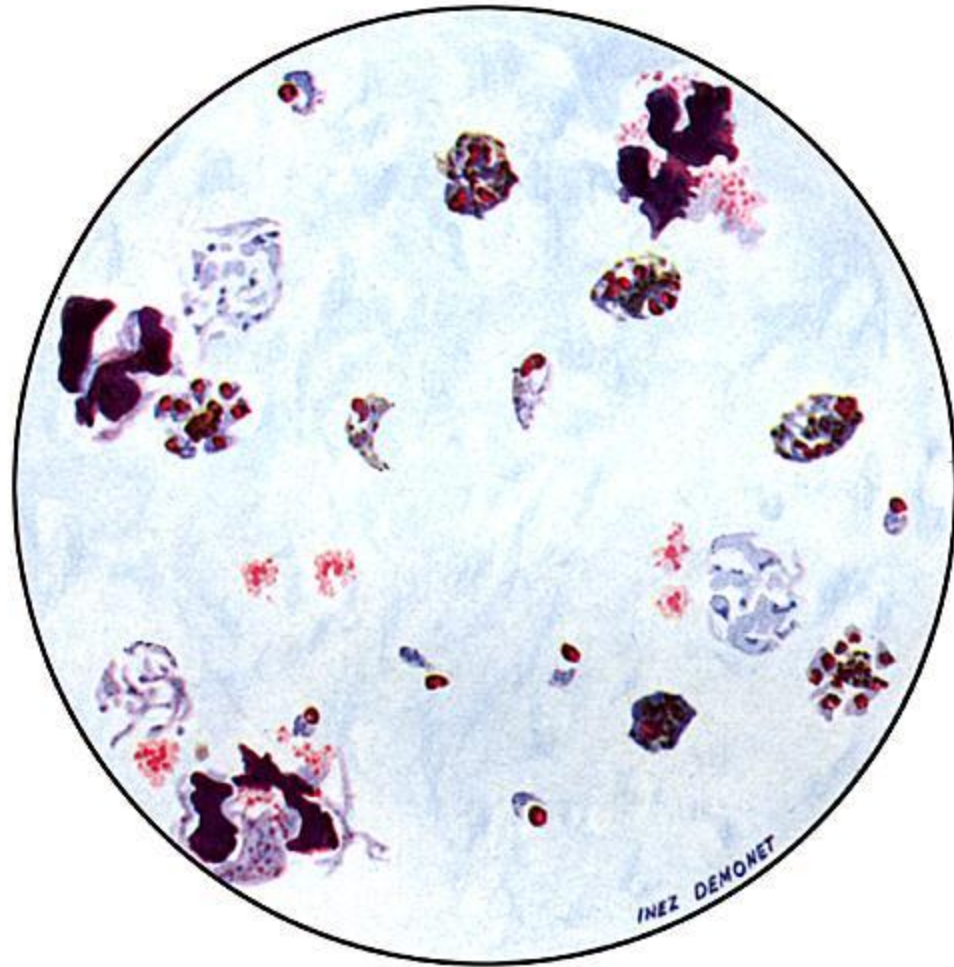




Trophozoites



Plasmodium malariae






Developing gametocyte ;**Fig. 24 : Macrogametocyte (female ;**

Fig. 25 : Microgametocyte (male ;



23

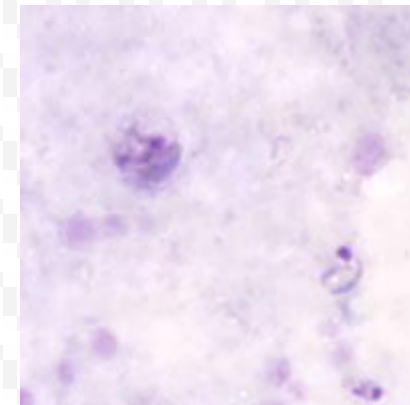
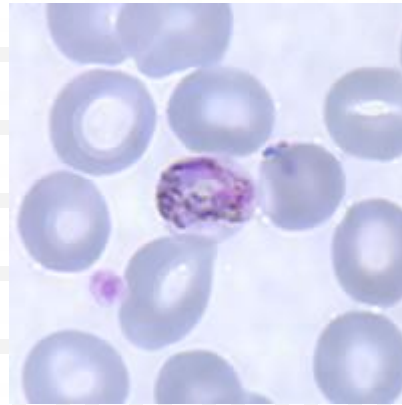
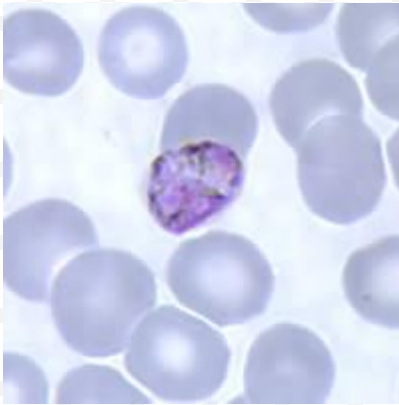

24



25

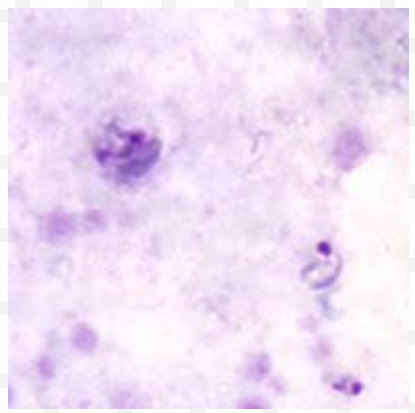
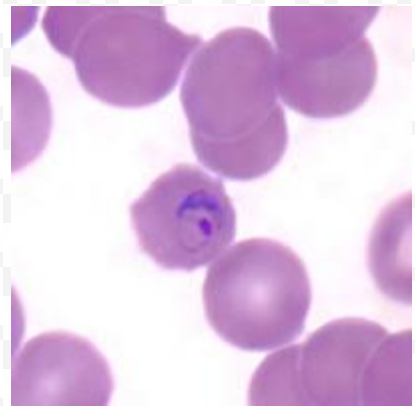
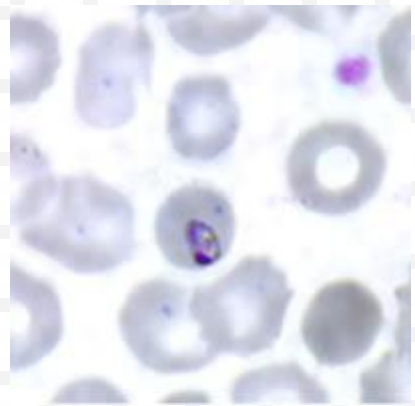
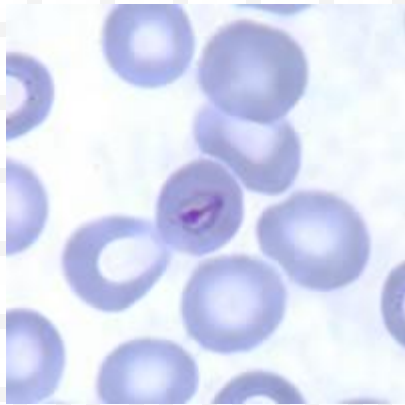
Gametocytes



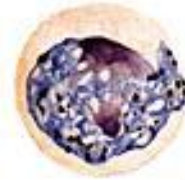

Ring Stage





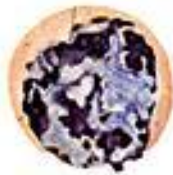Schizonts



14



15



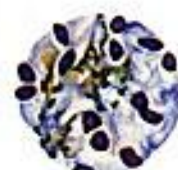16



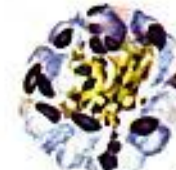17



18



19



20



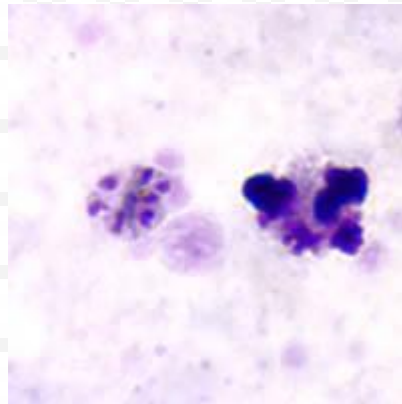
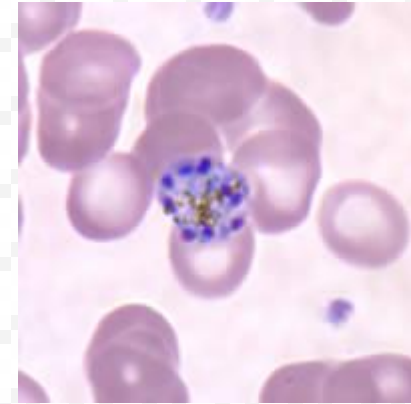
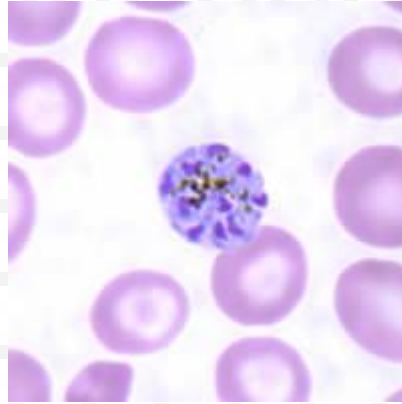
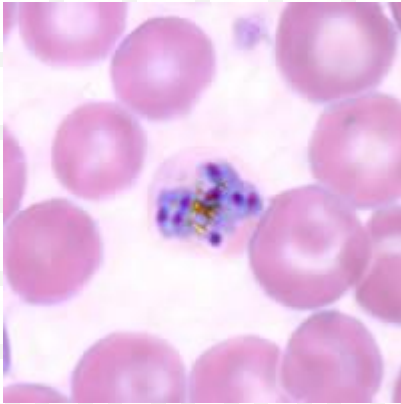
21



22




Schizonts of *P. malariae* in a thin&thick blood smear .



Trophozoites




6



7




8



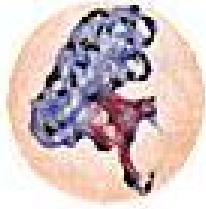9



10



11



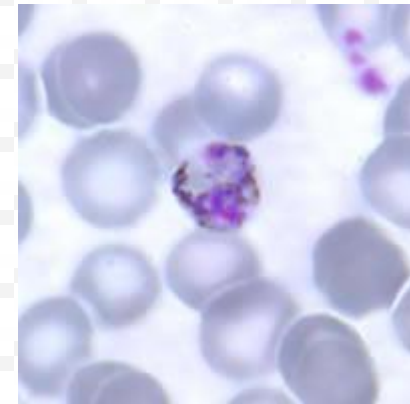
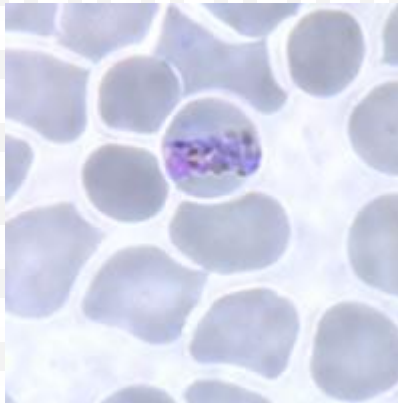
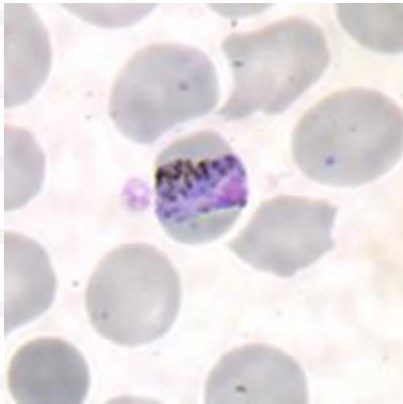
12

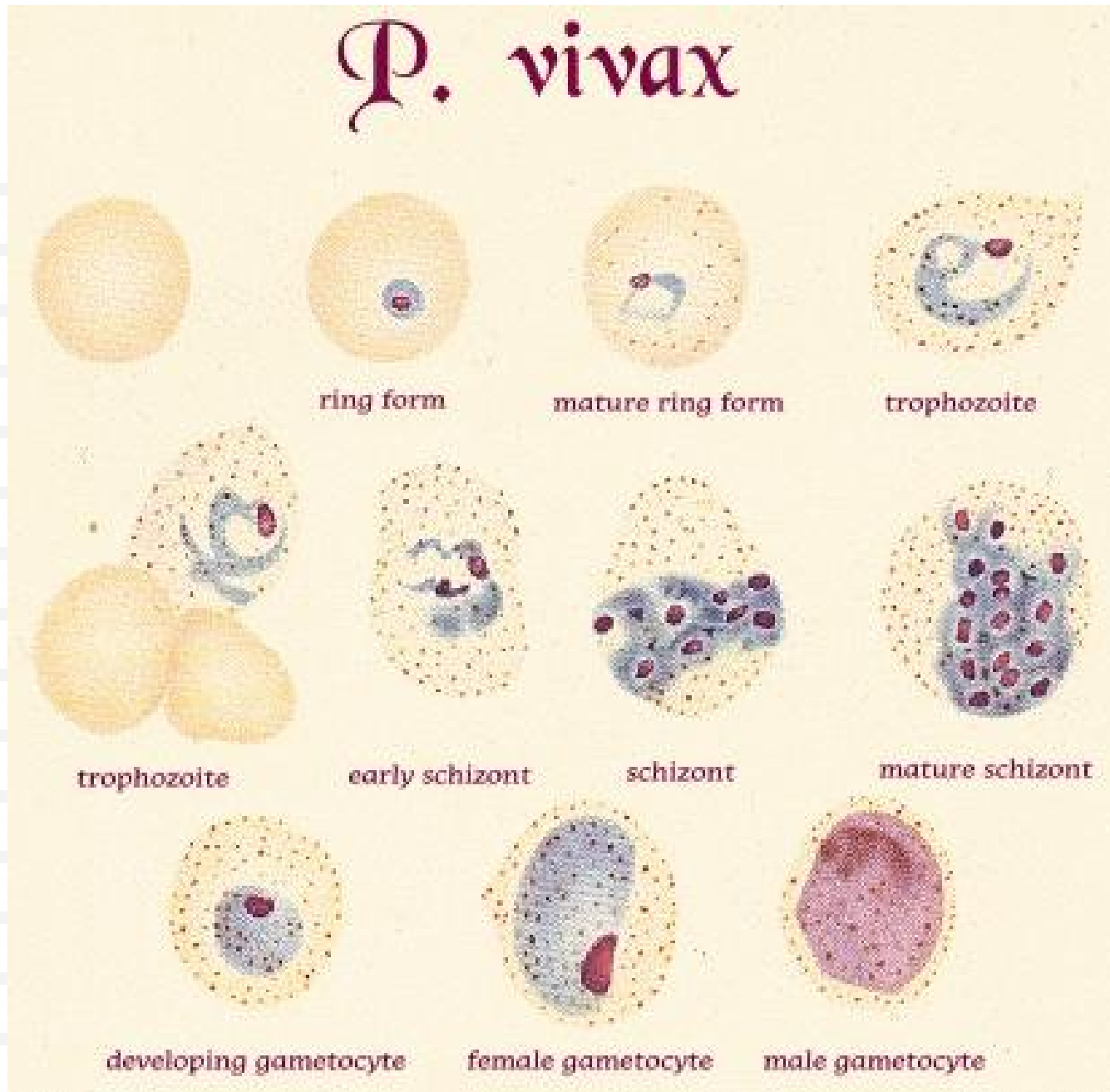


13

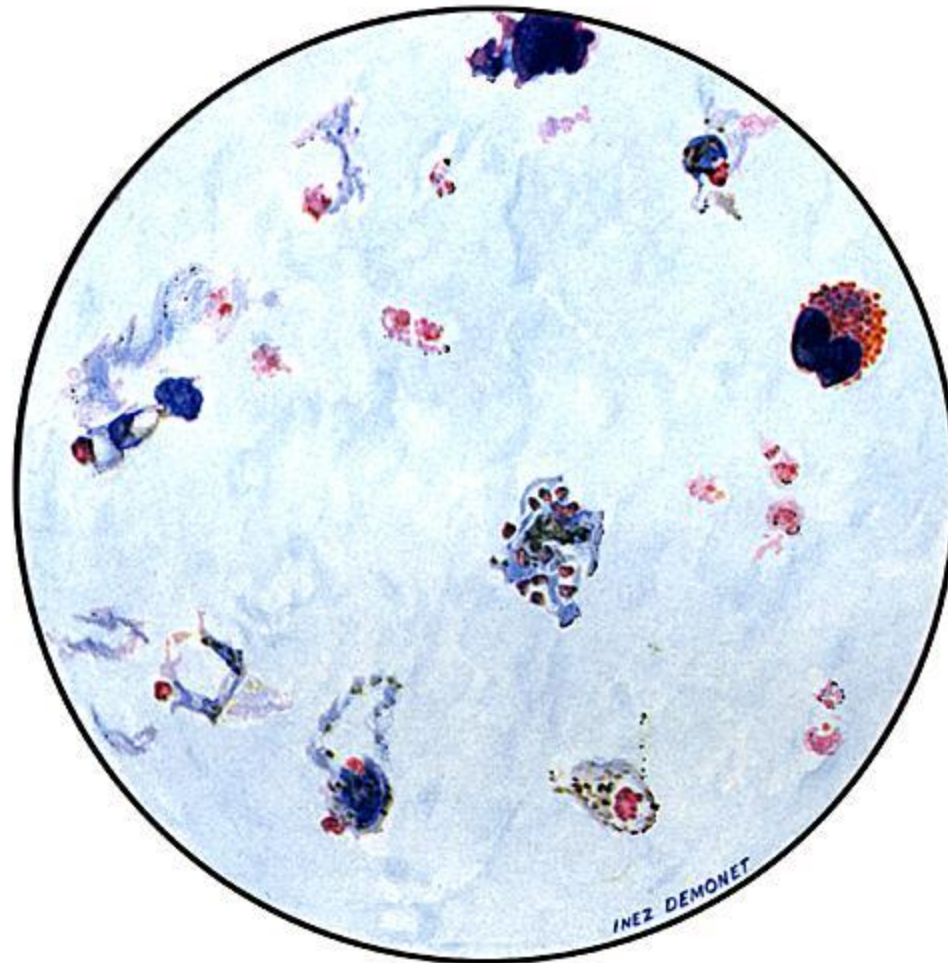


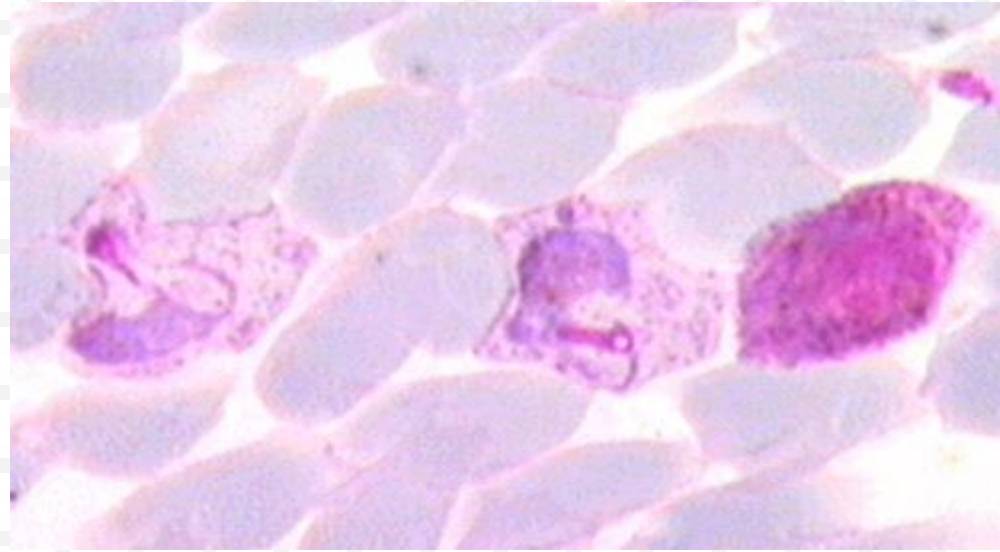
~~A and B are band forms . C is a "basket"~~
form .

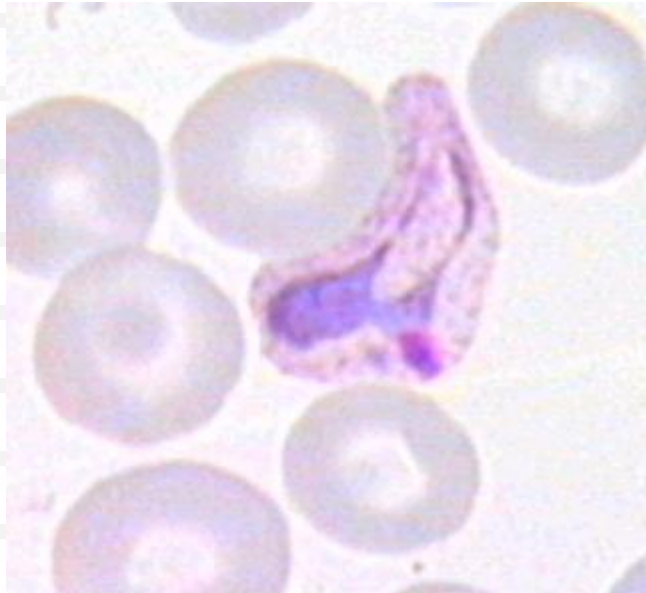




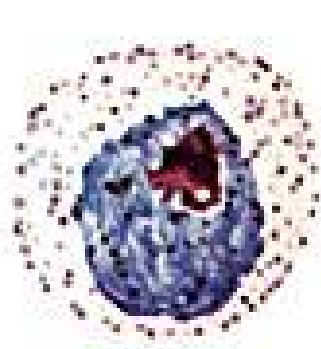
Plasmodium vivax







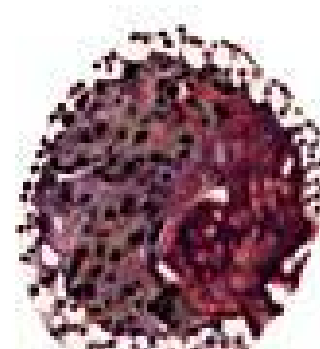
Gametocytes



28

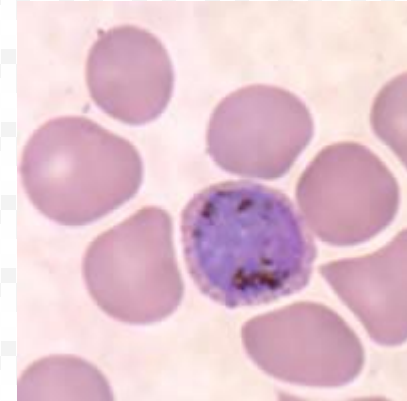
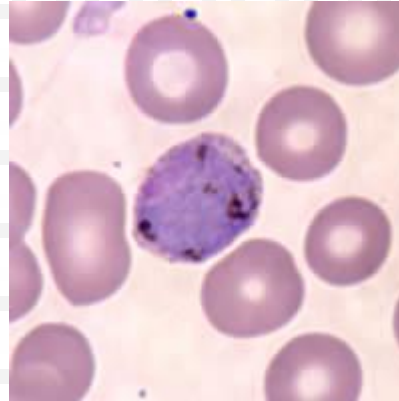
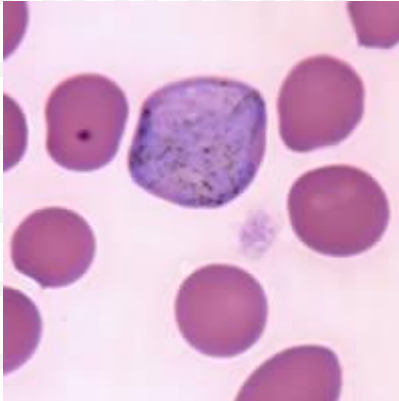


29



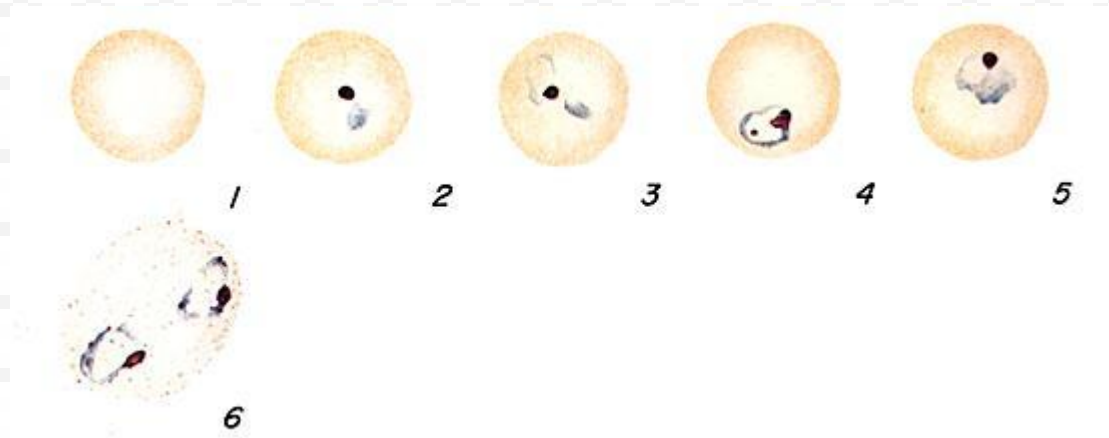
30

Schüffner's dots can be seen in **B** and **C**.



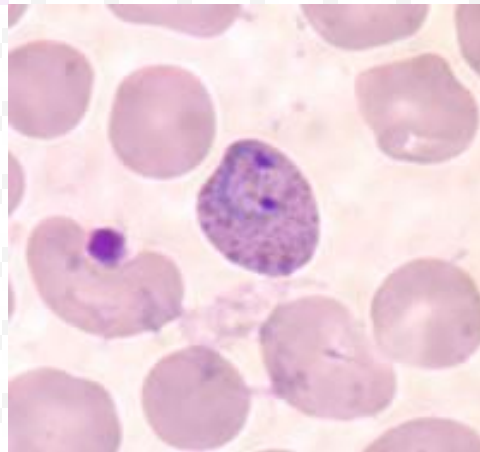
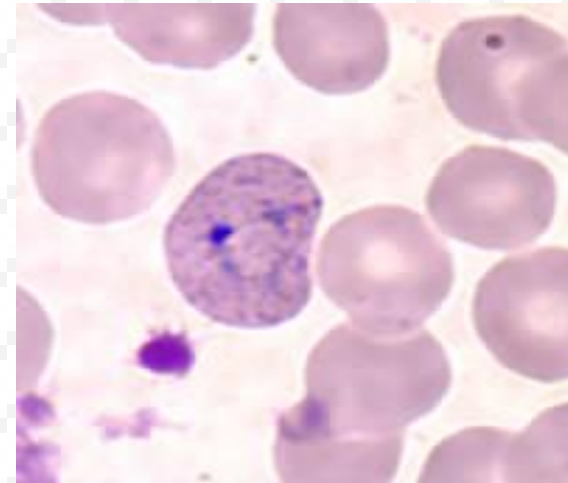
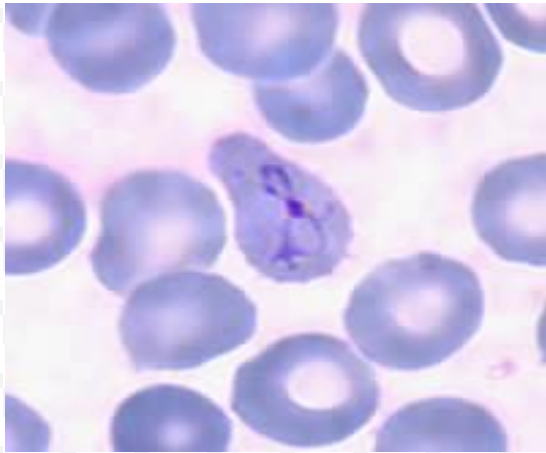


Ring Stage Parasites

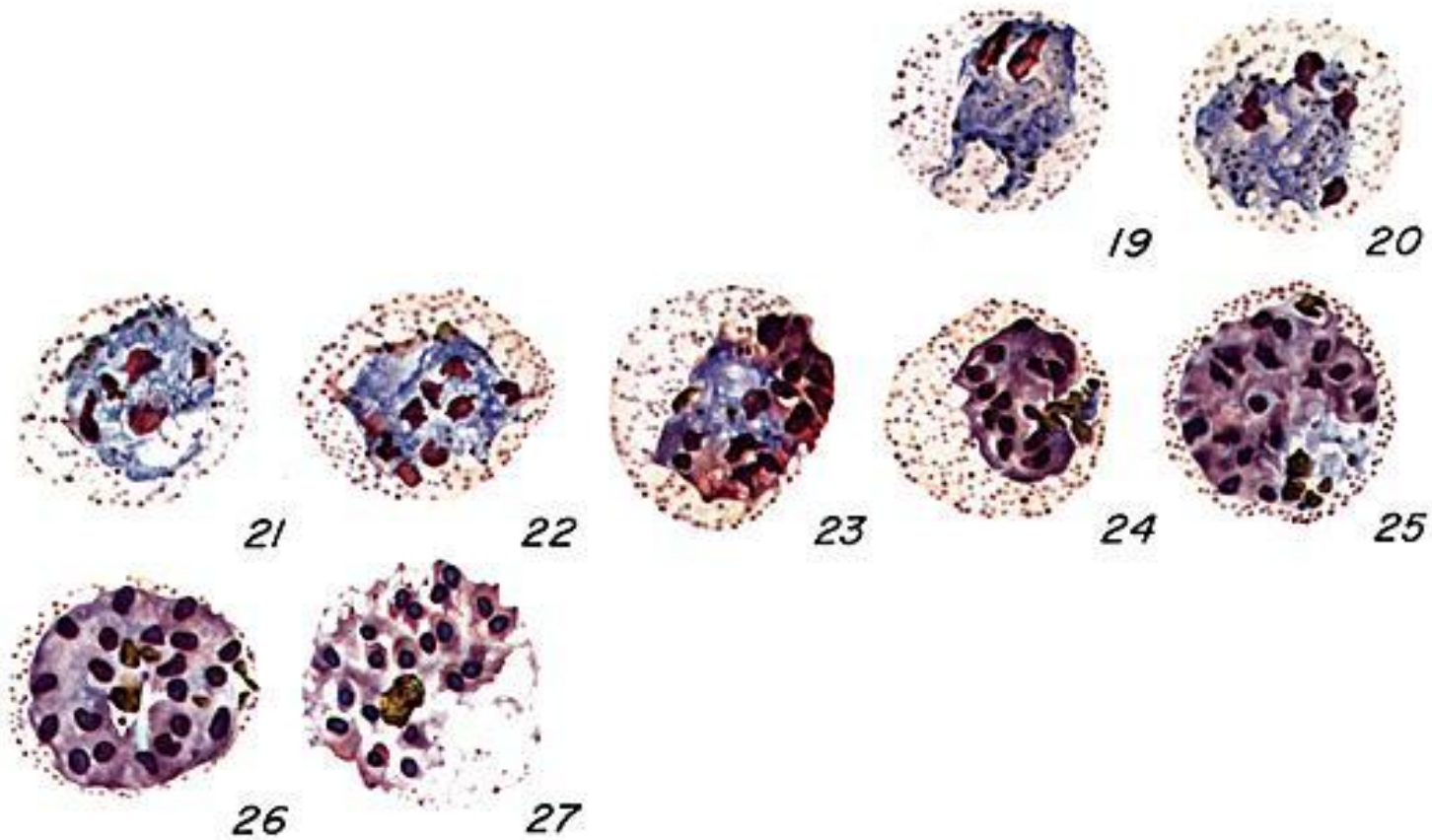


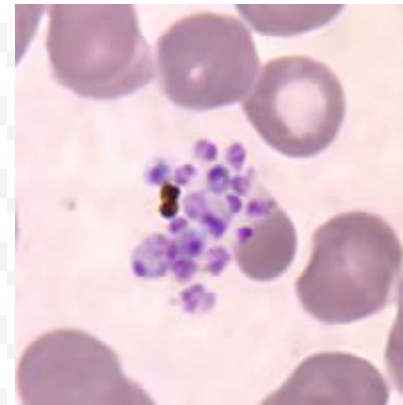
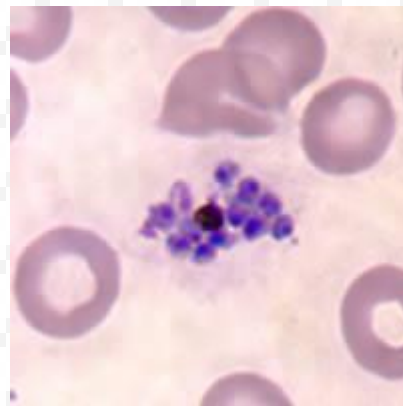
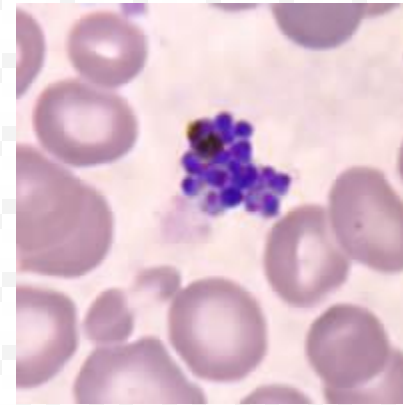
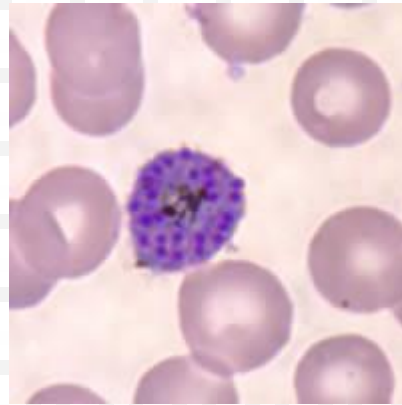
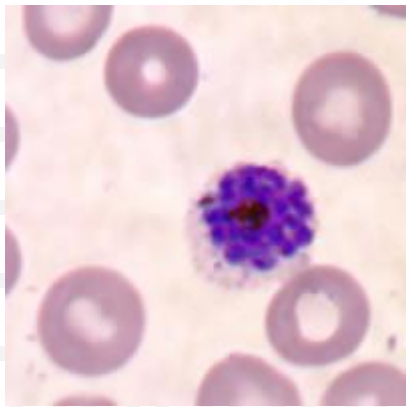


A and **C** :Rings are amoeboid and the RBCs are enlarged and distorted .**B** :
Ring with double chromatin dot.
Schüffner's dots can be seen in **B** and **C**.

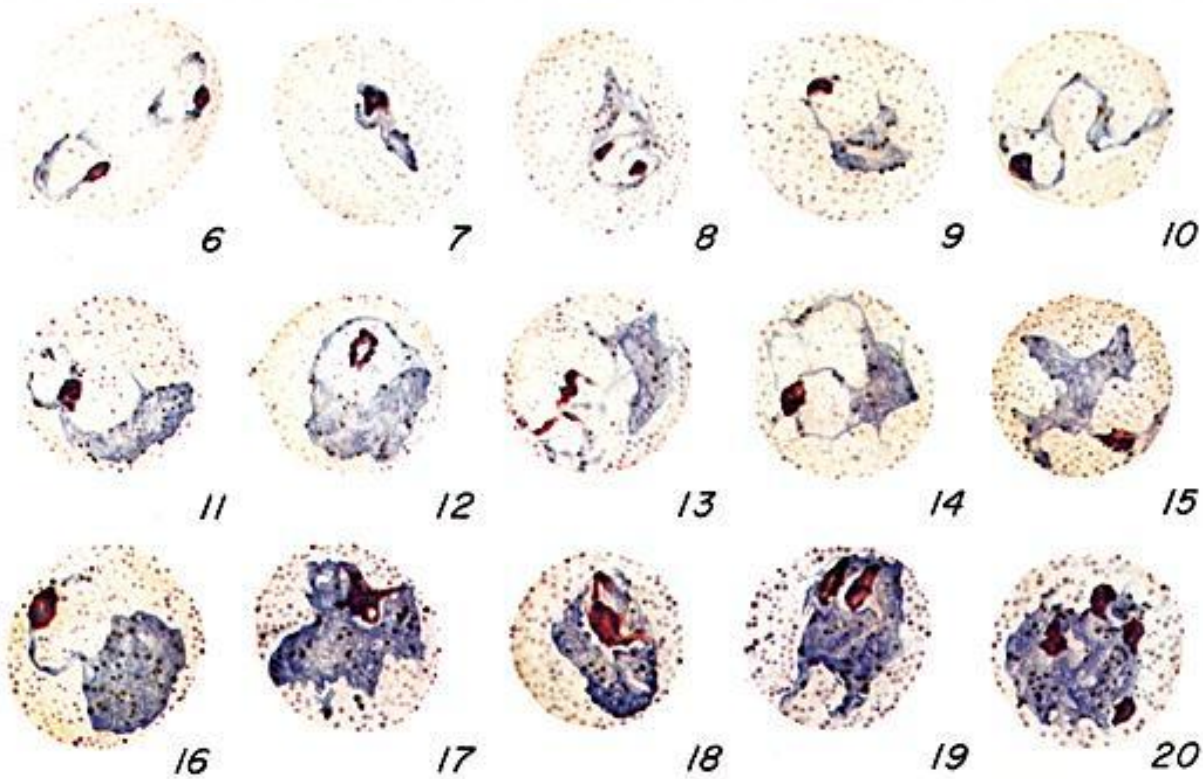


Schizonts



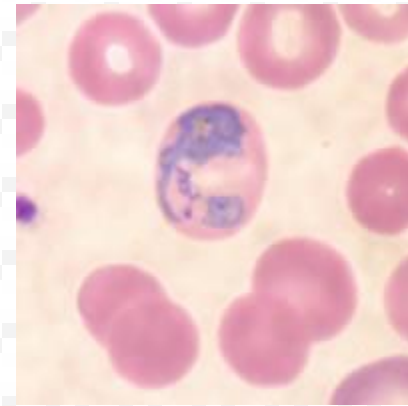
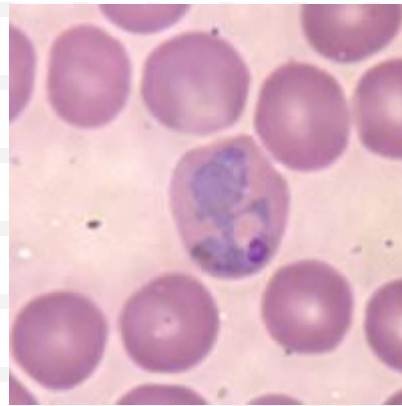
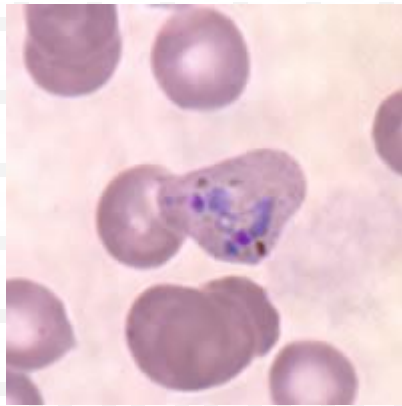


Trophozoites

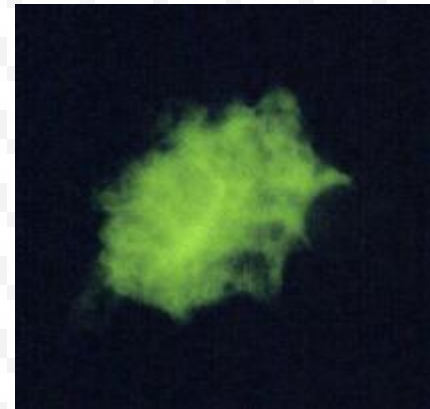
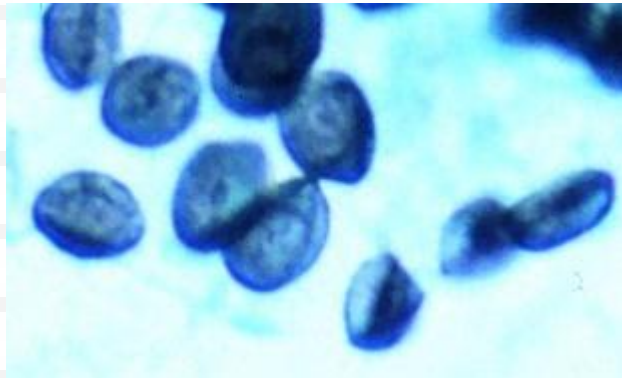
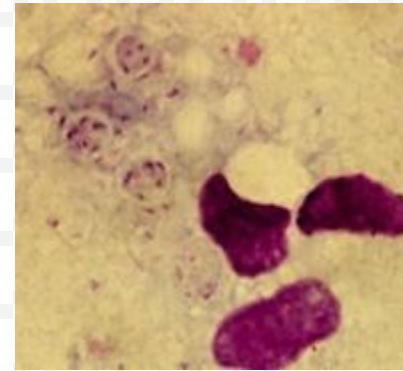
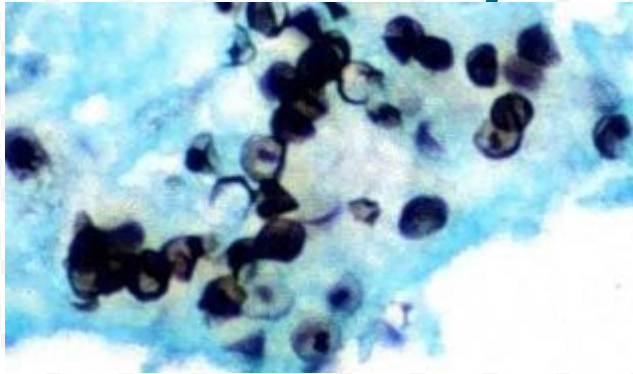


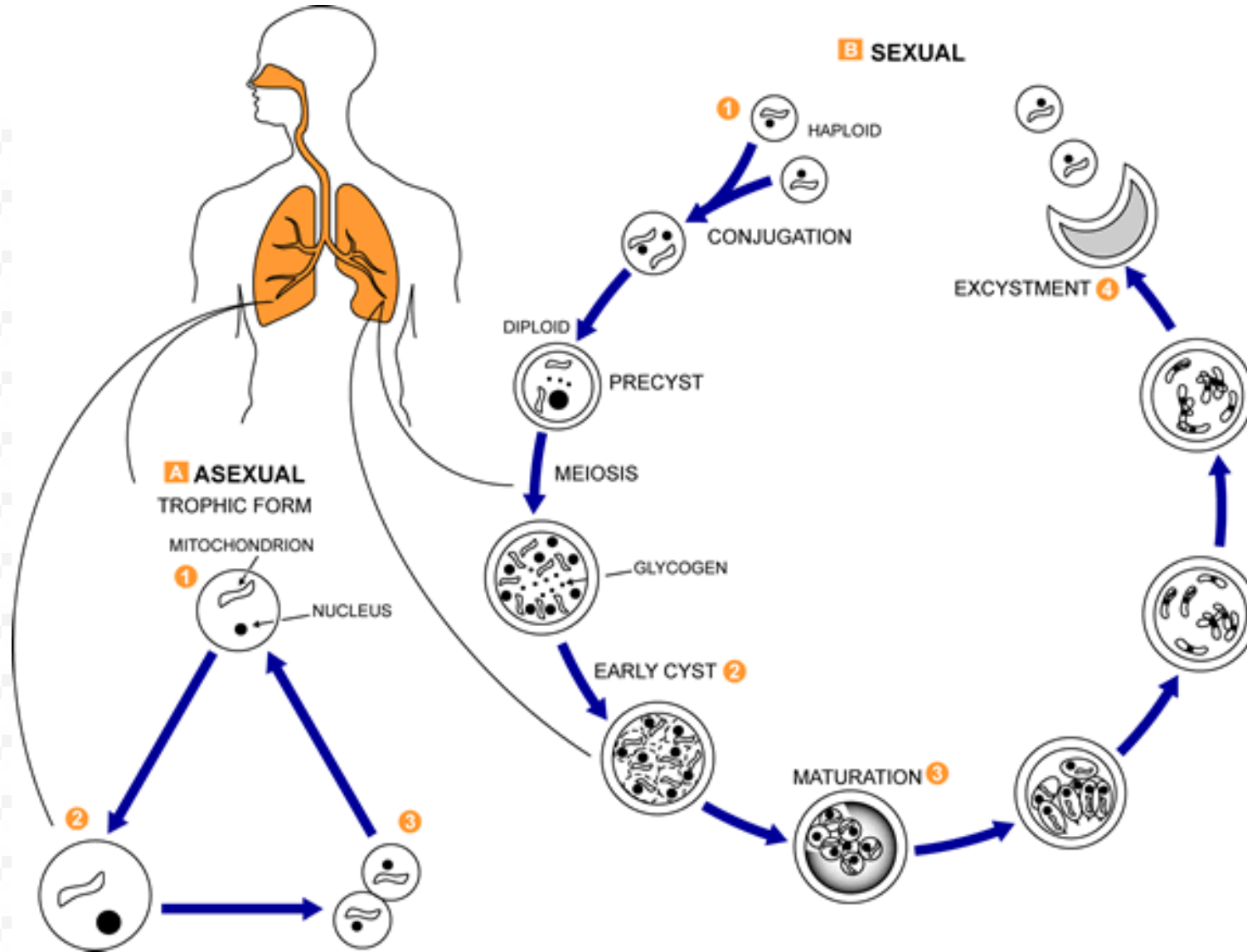


A, B, C : Large, amoeboid trophozoites of *P. vivax*
in thin blood smears

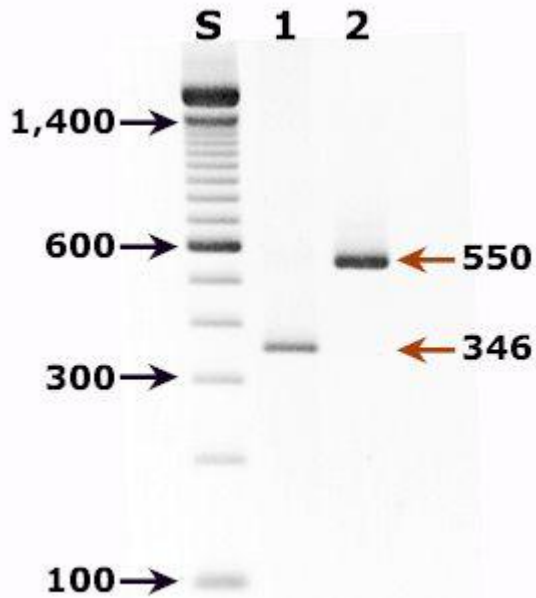


Pneumocystis jiroveci

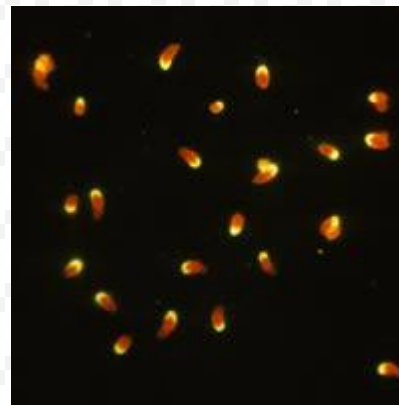
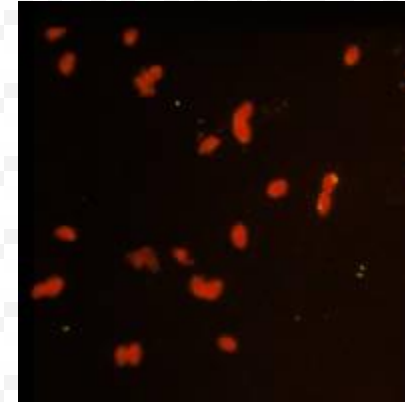
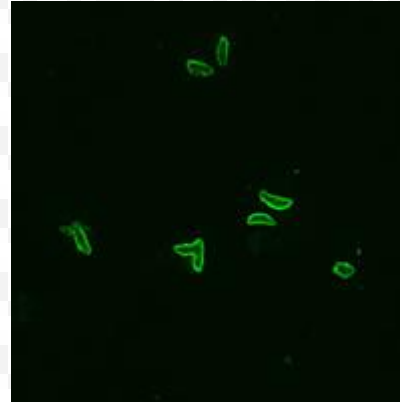
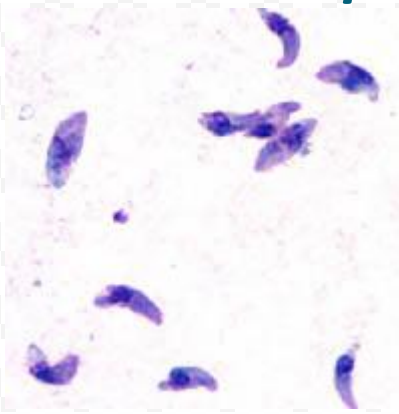




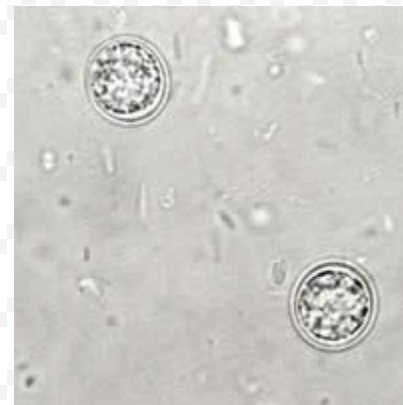
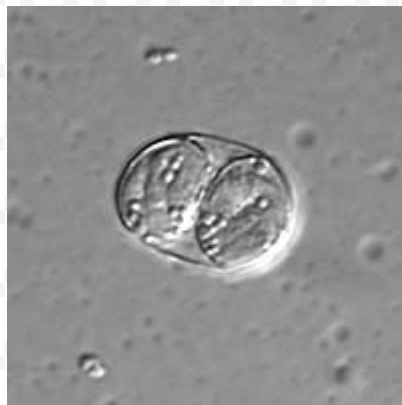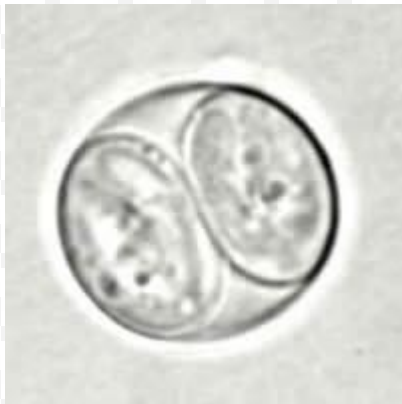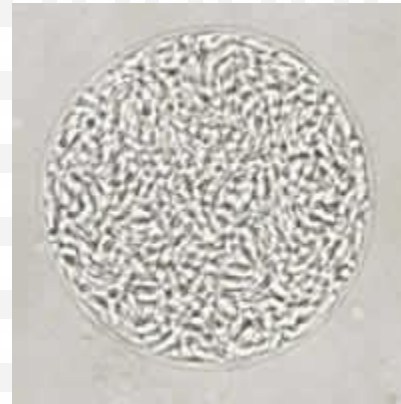
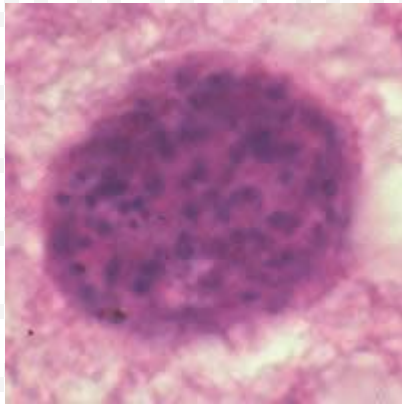
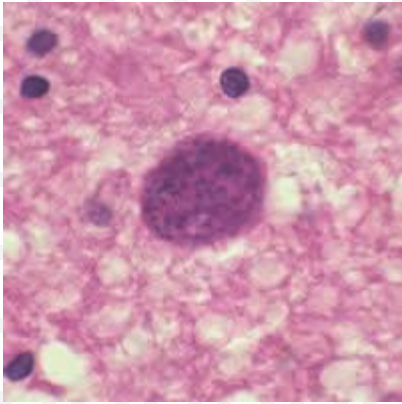
Pneumocystis jiroveci



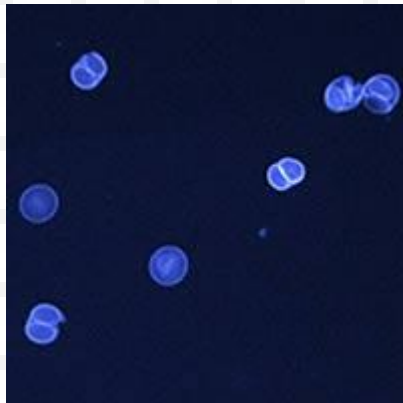
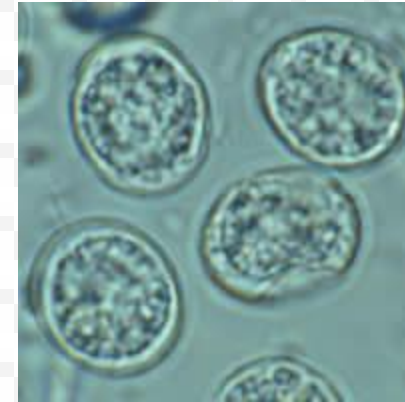
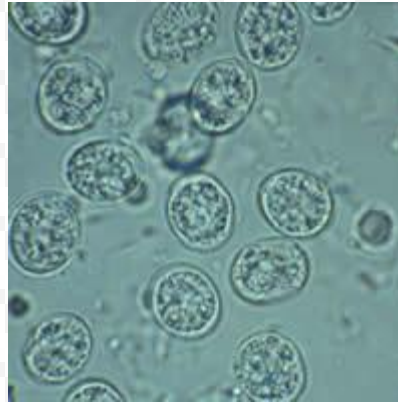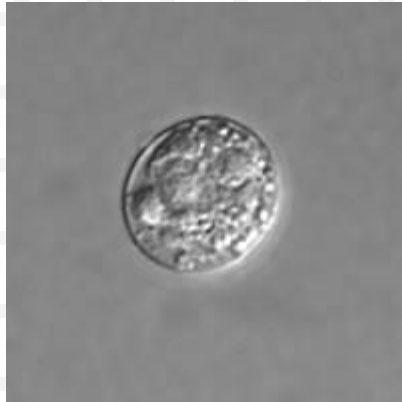
Toxoplasma gondii tachyzoites

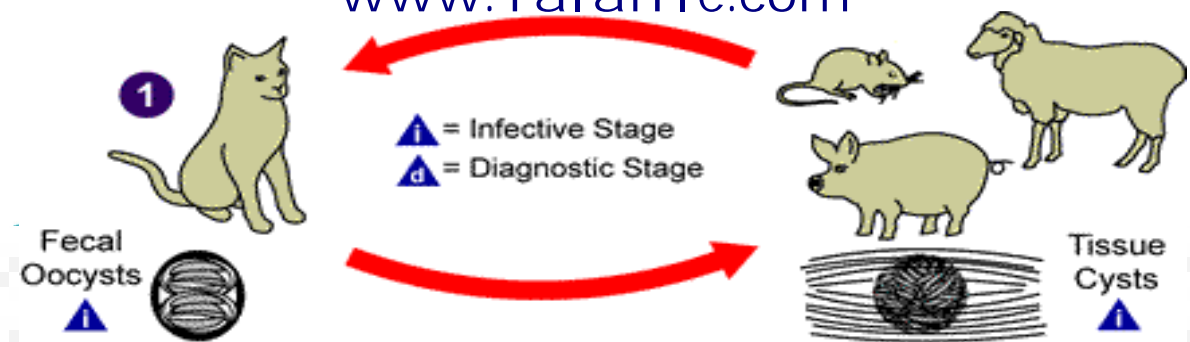

Toxoplasma gondii

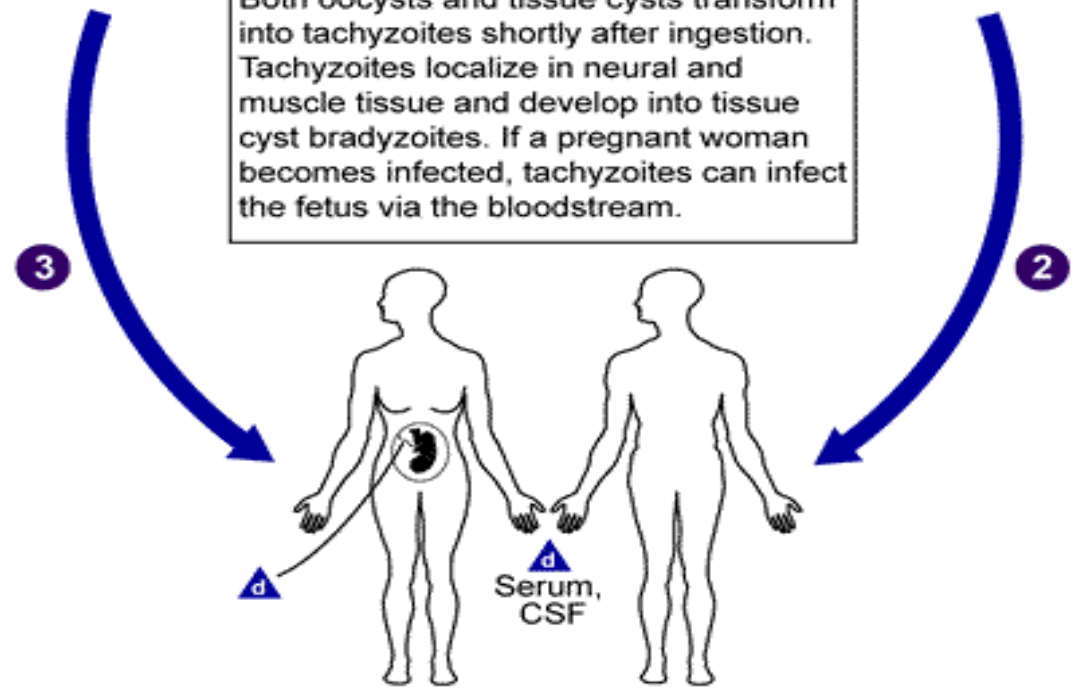


Toxoplasma gondii





Both oocysts and tissue cysts transform into tachyzoites shortly after ingestion. Tachyzoites localize in neural and muscle tissue and develop into tissue cyst bradyzoites. If a pregnant woman becomes infected, tachyzoites can infect the fetus via the bloodstream.



d Diagnostic Stage

1) Serological diagnosis.
or
2) Direct identification of the parasite from peripheral blood, amniotic fluid, or in tissue sections.

